

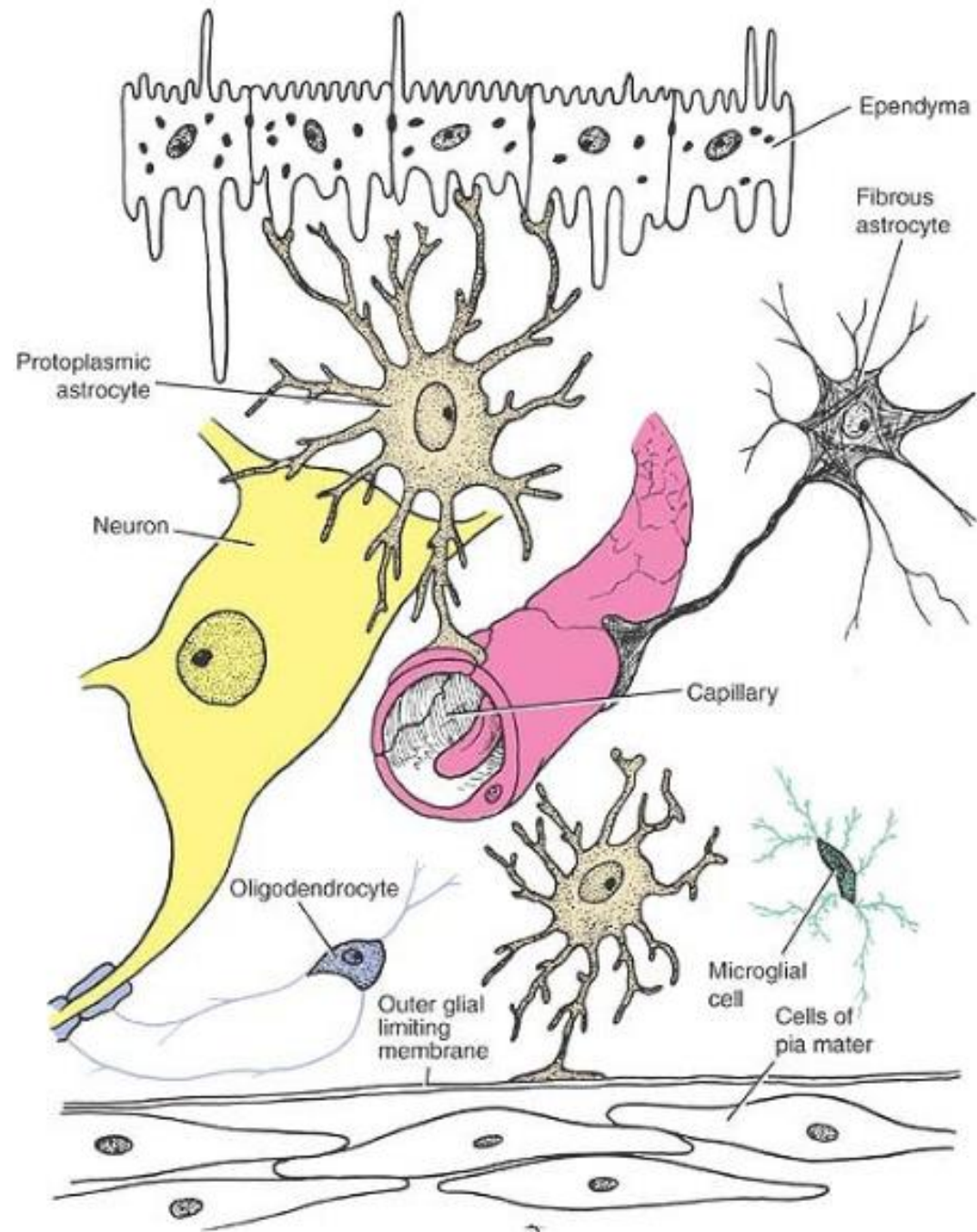
Neurohistología

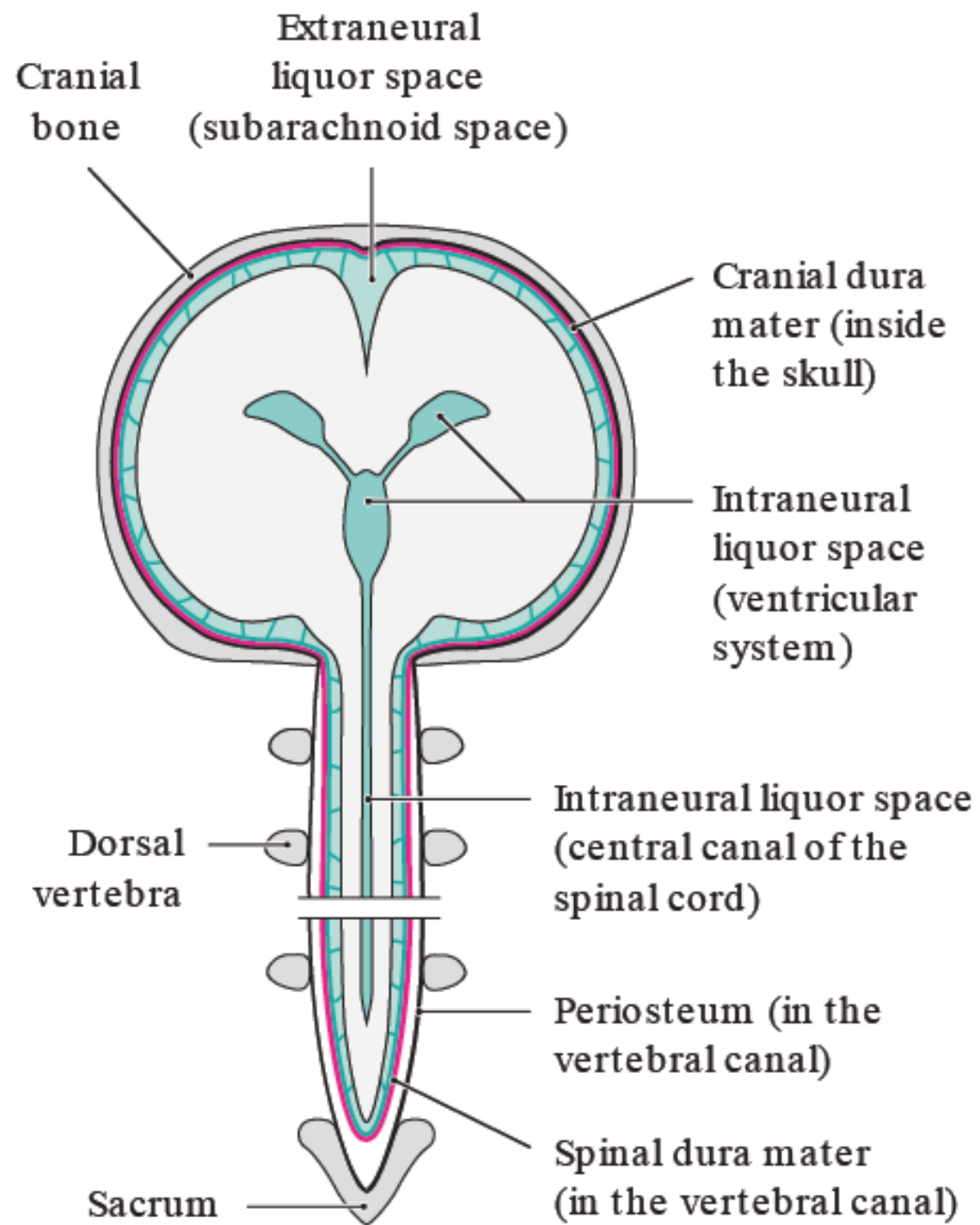
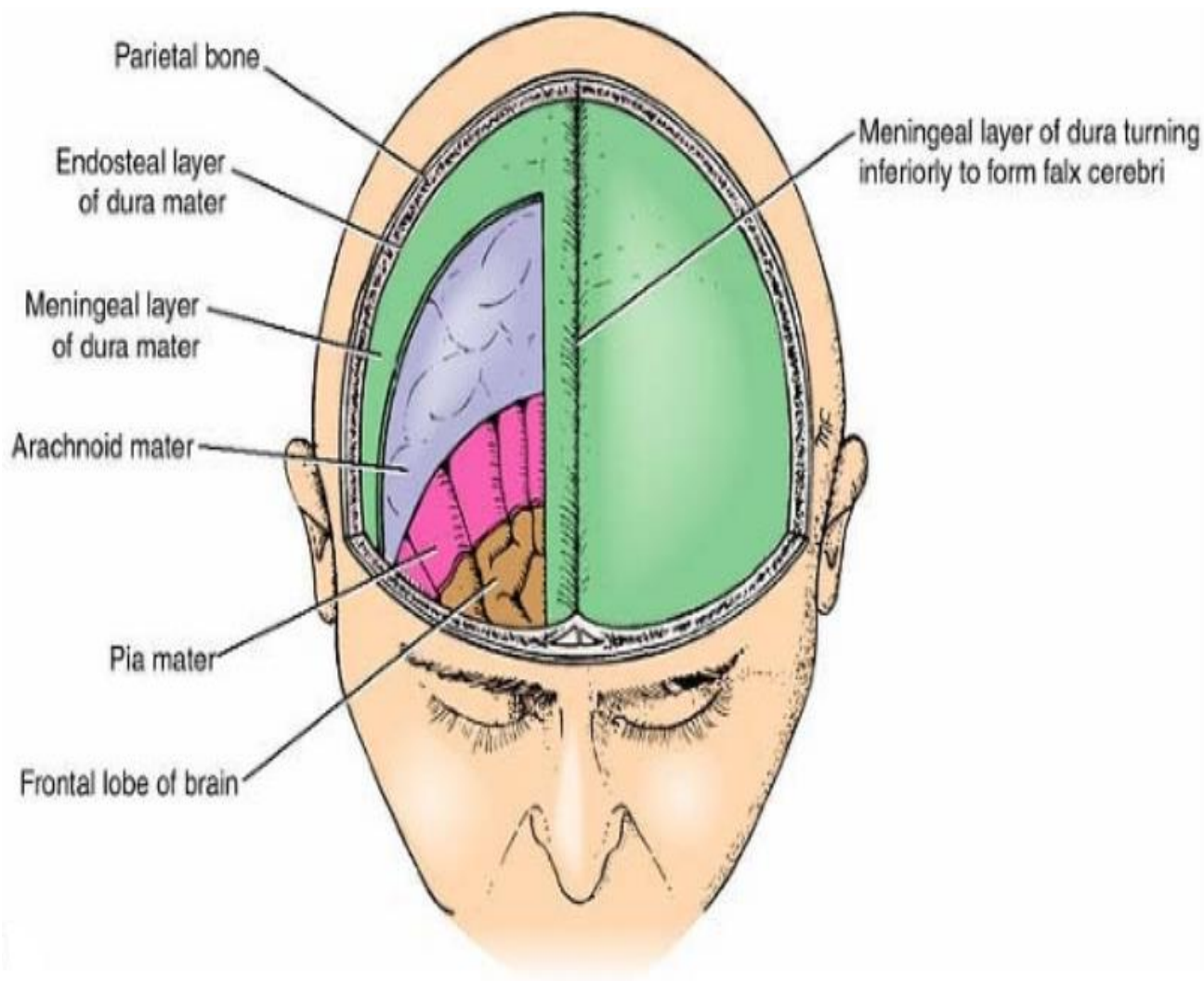
Nelson D. Villalba M.D. M.Sc.

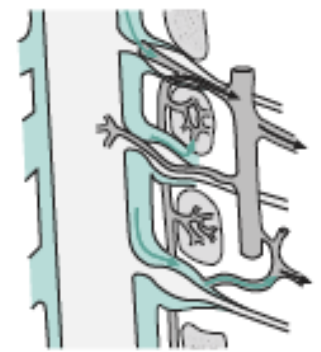
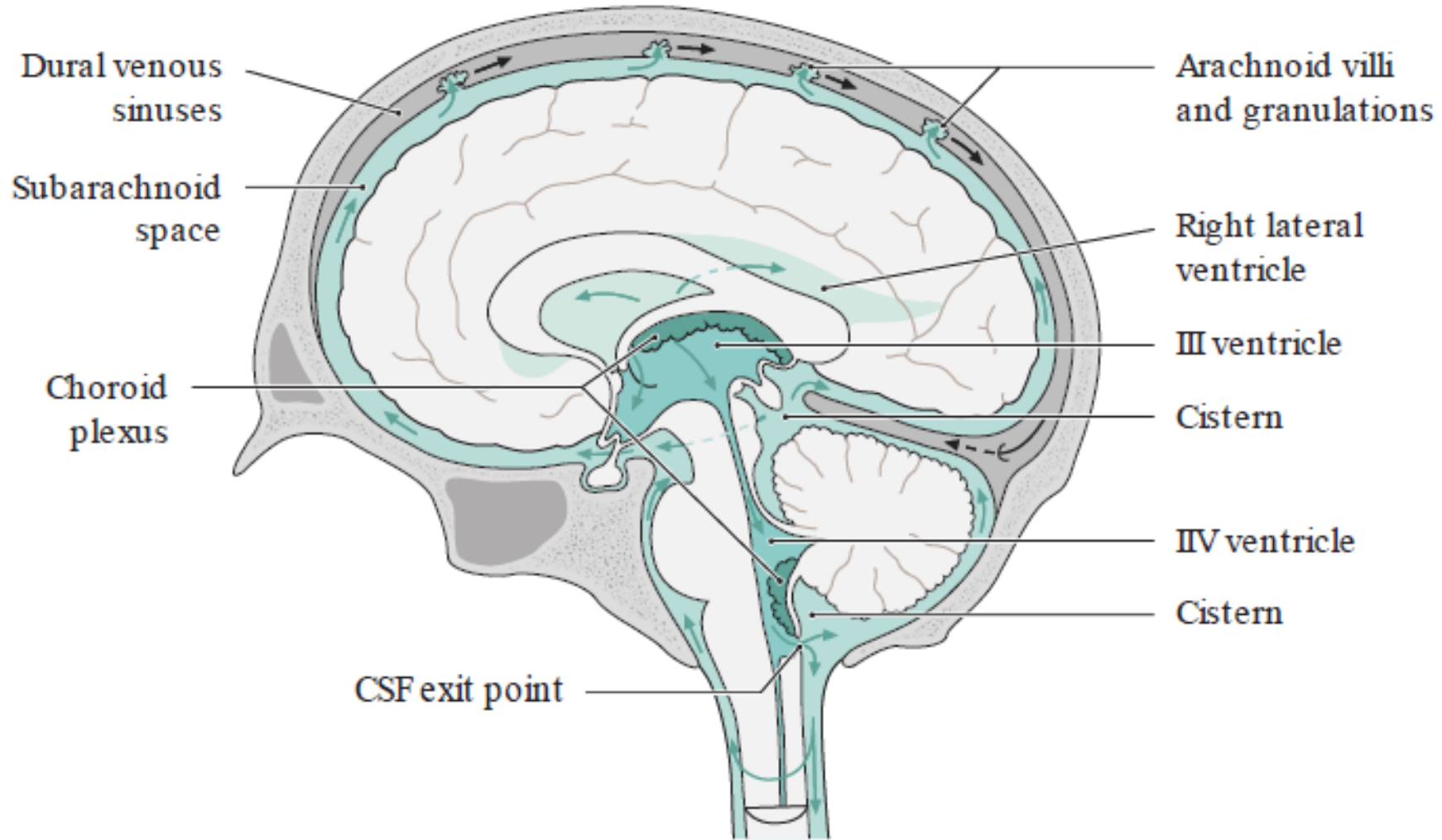


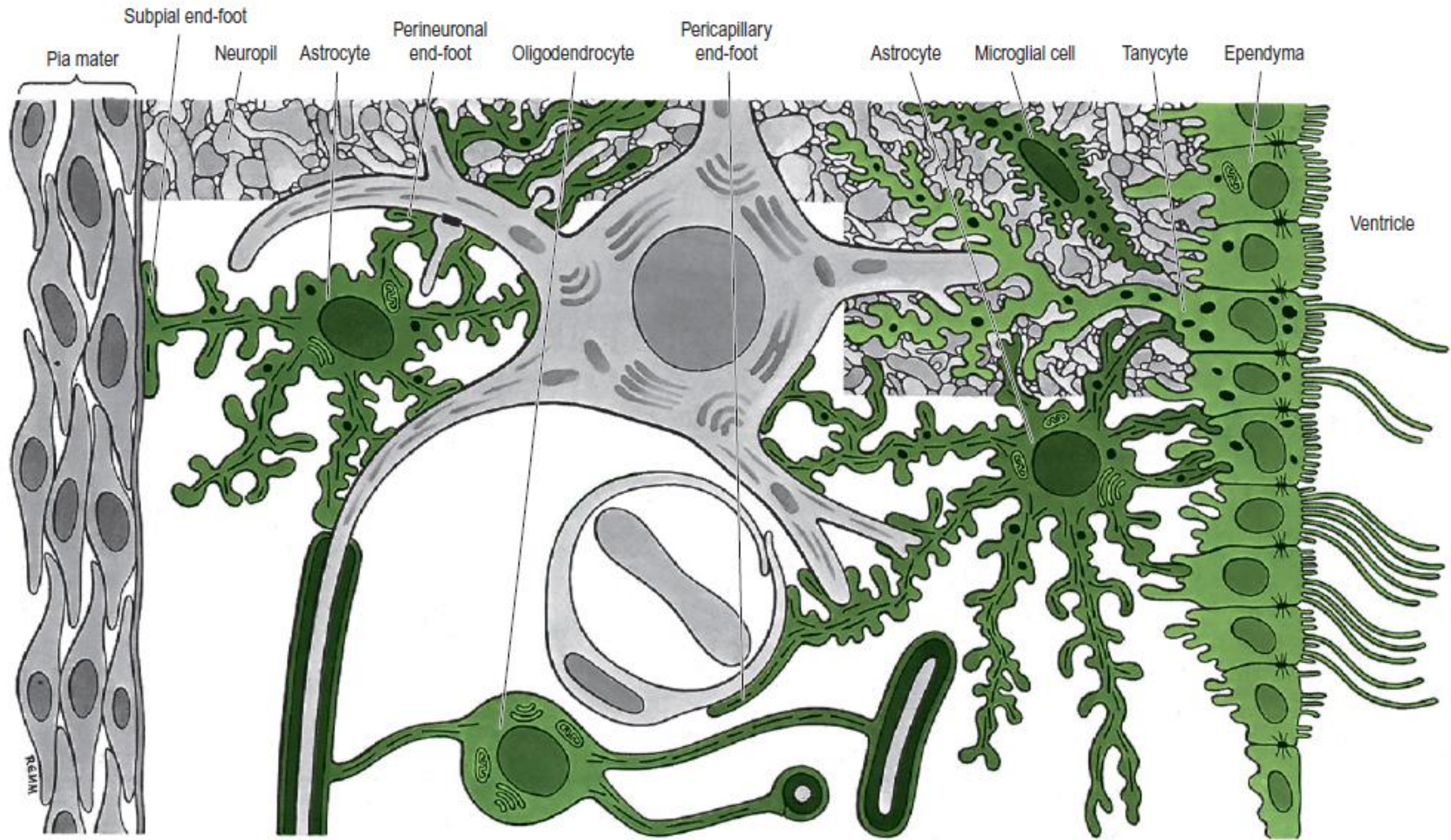
Prof. Camillo Golgi

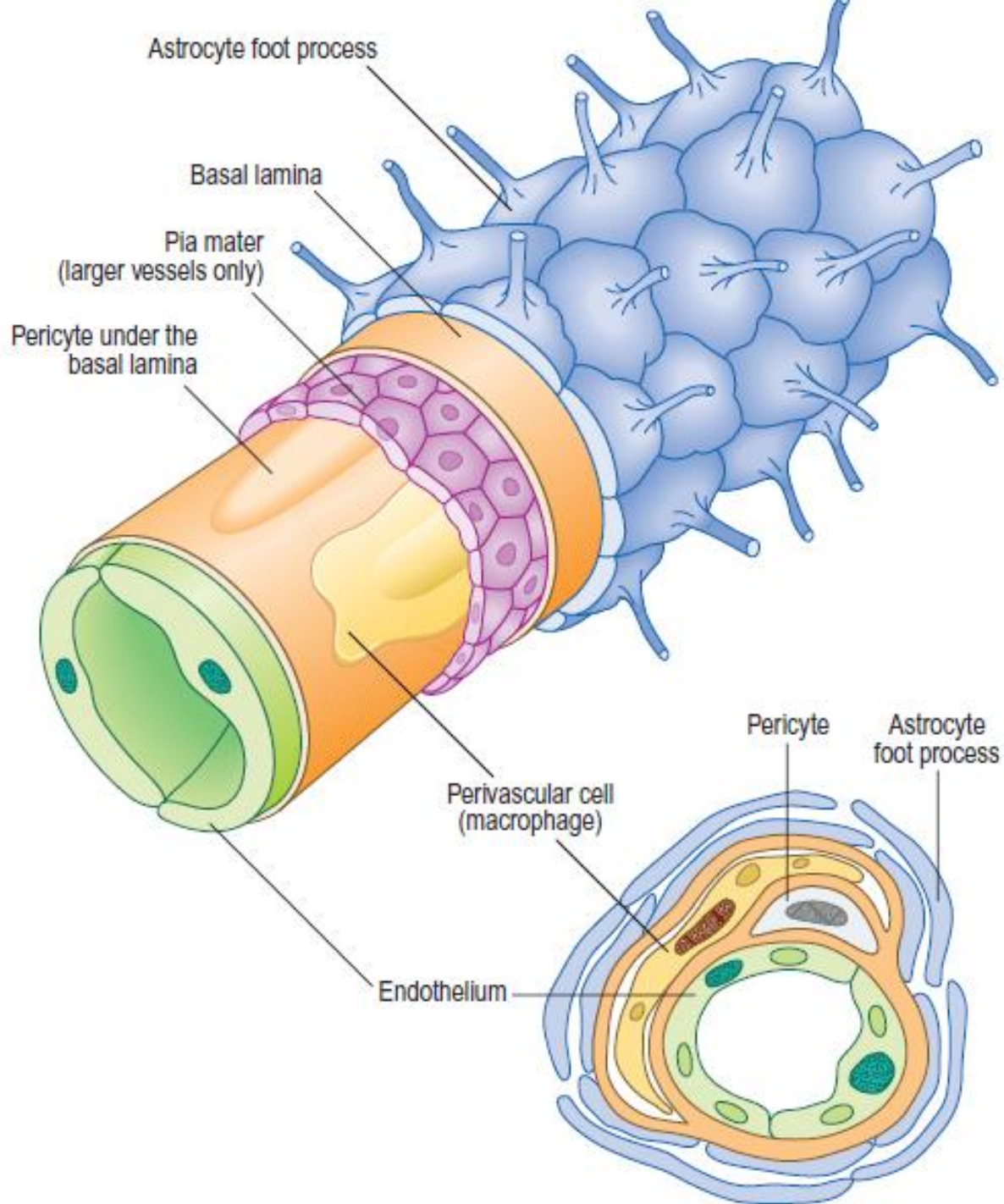
- <http://www.icesi.edu.co/blogs/neuroanatomia/2017/01/25/neurohistologia-ramon-y-cajal-vs-camilo-golgi/>

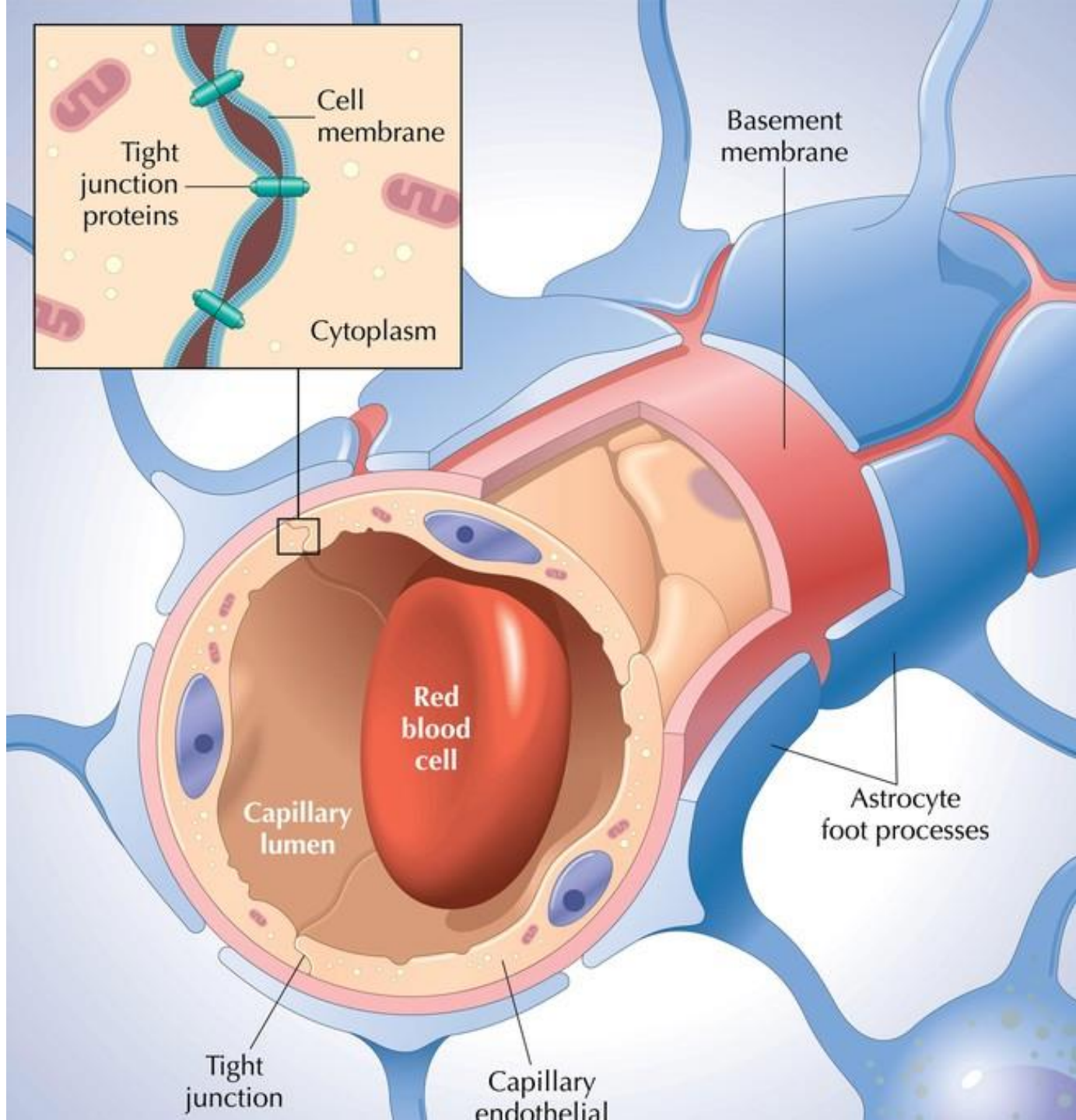


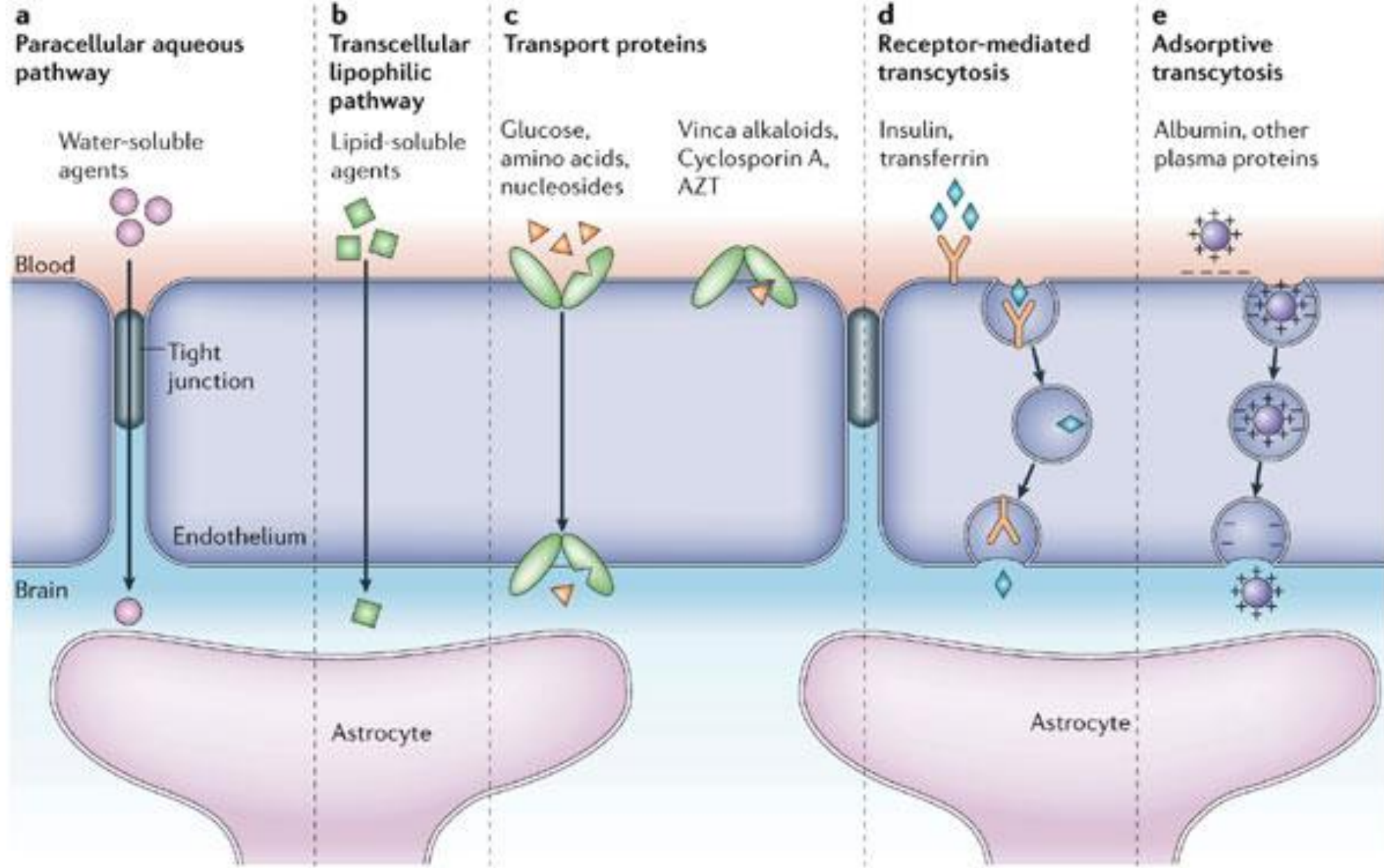


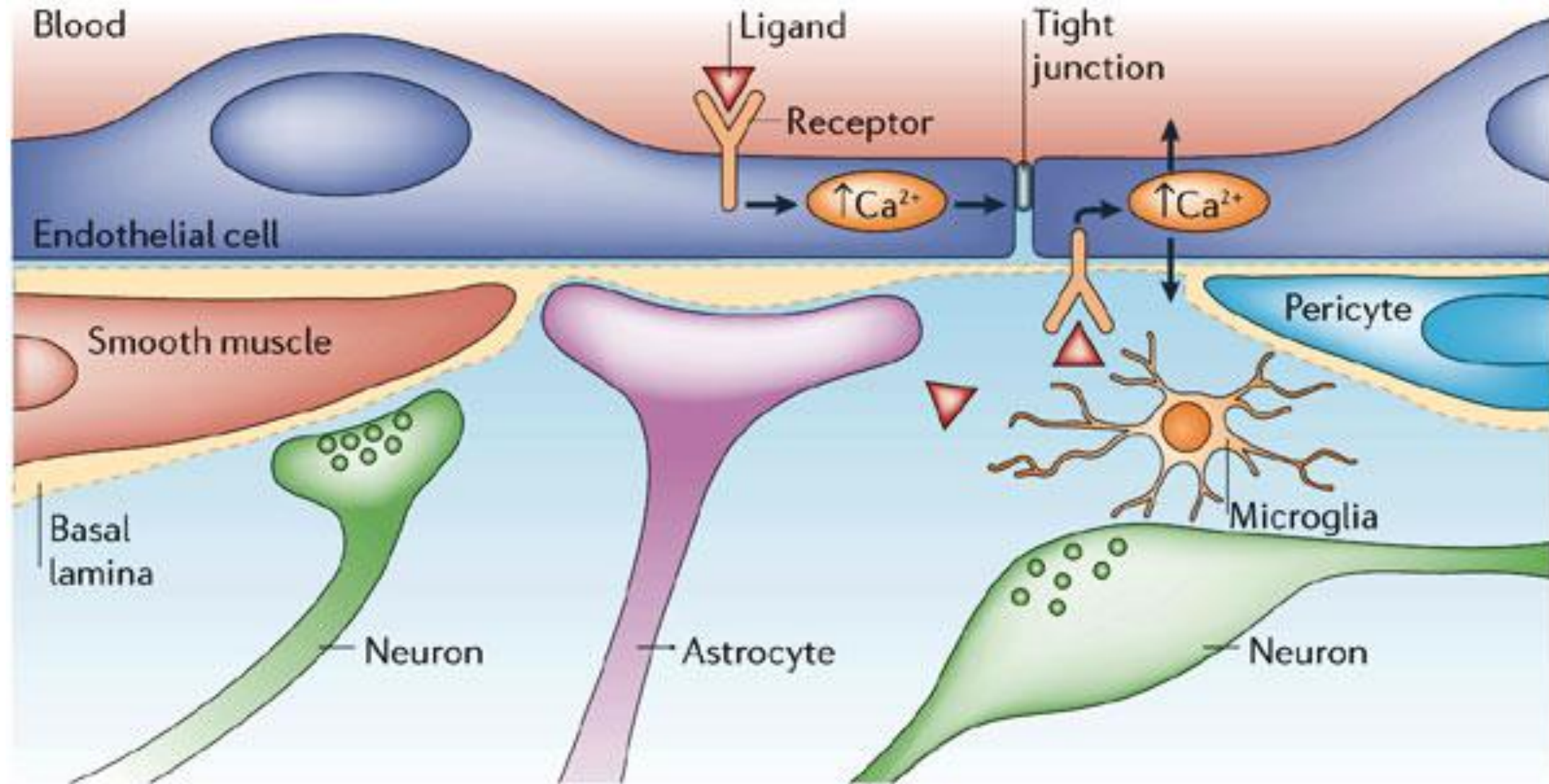










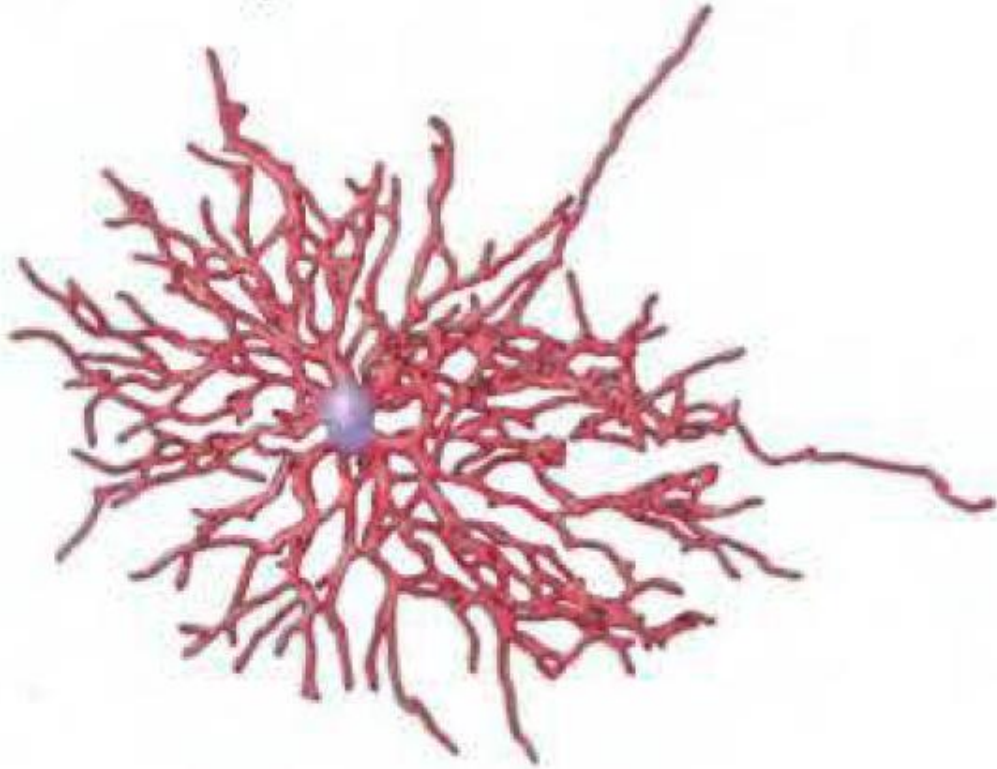


Compartimiento Glial

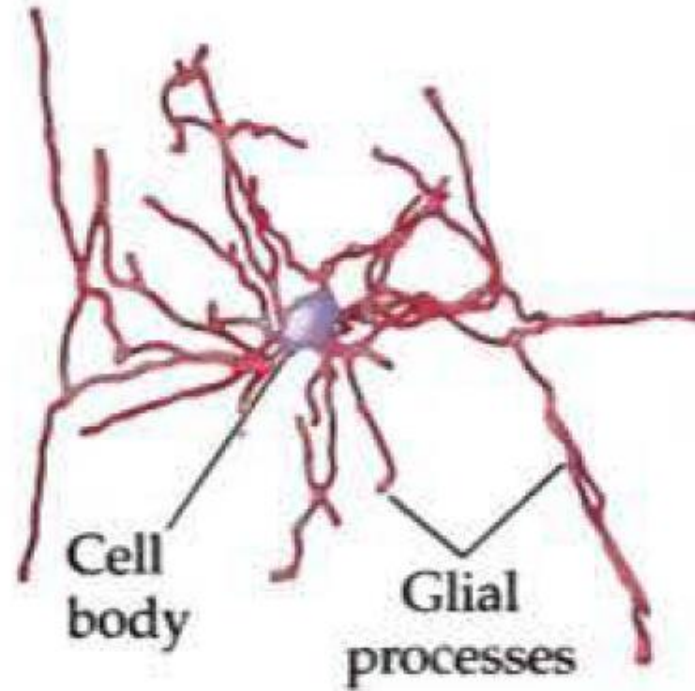
- Microglía
- Macroglía:
 - Astrocitos:
 - Fibrosos
 - Astrocitos Protoplasmáticos
 - Oligodendrocitos

Compartimiento Glial

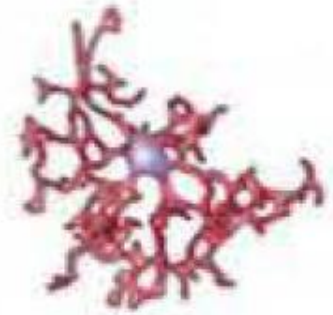(A) Astrocyte

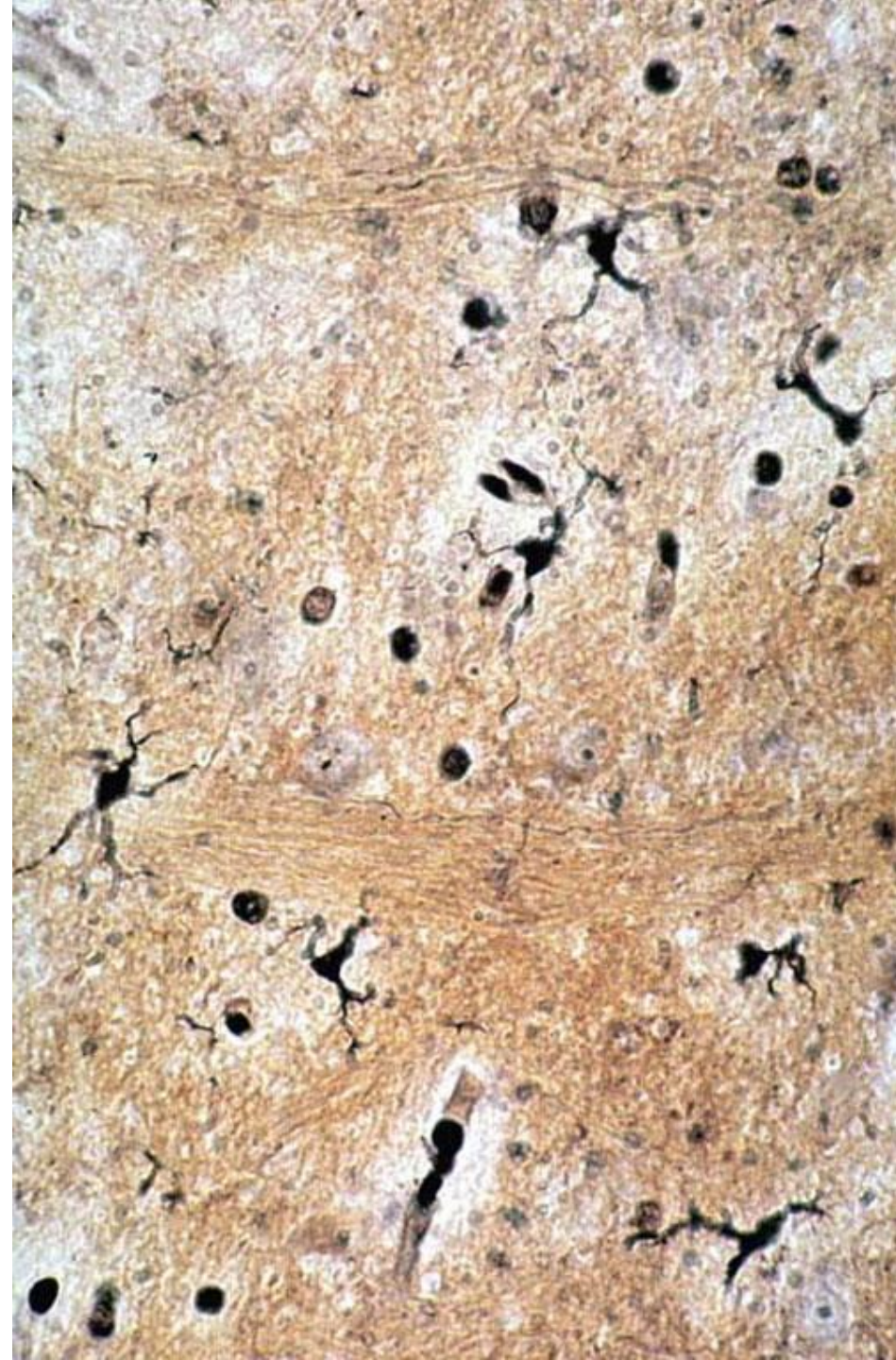


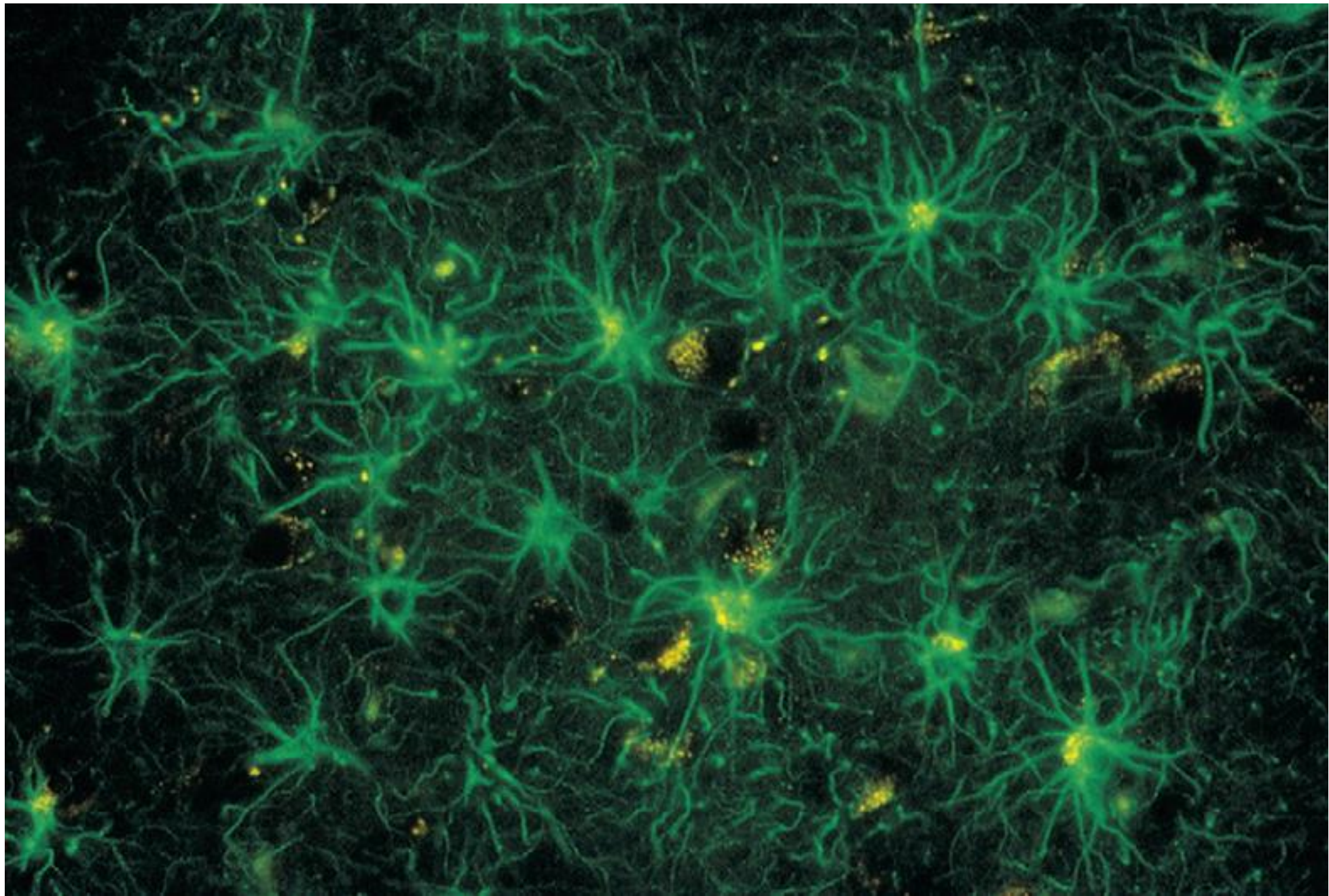
(B) Oligodendrocyte

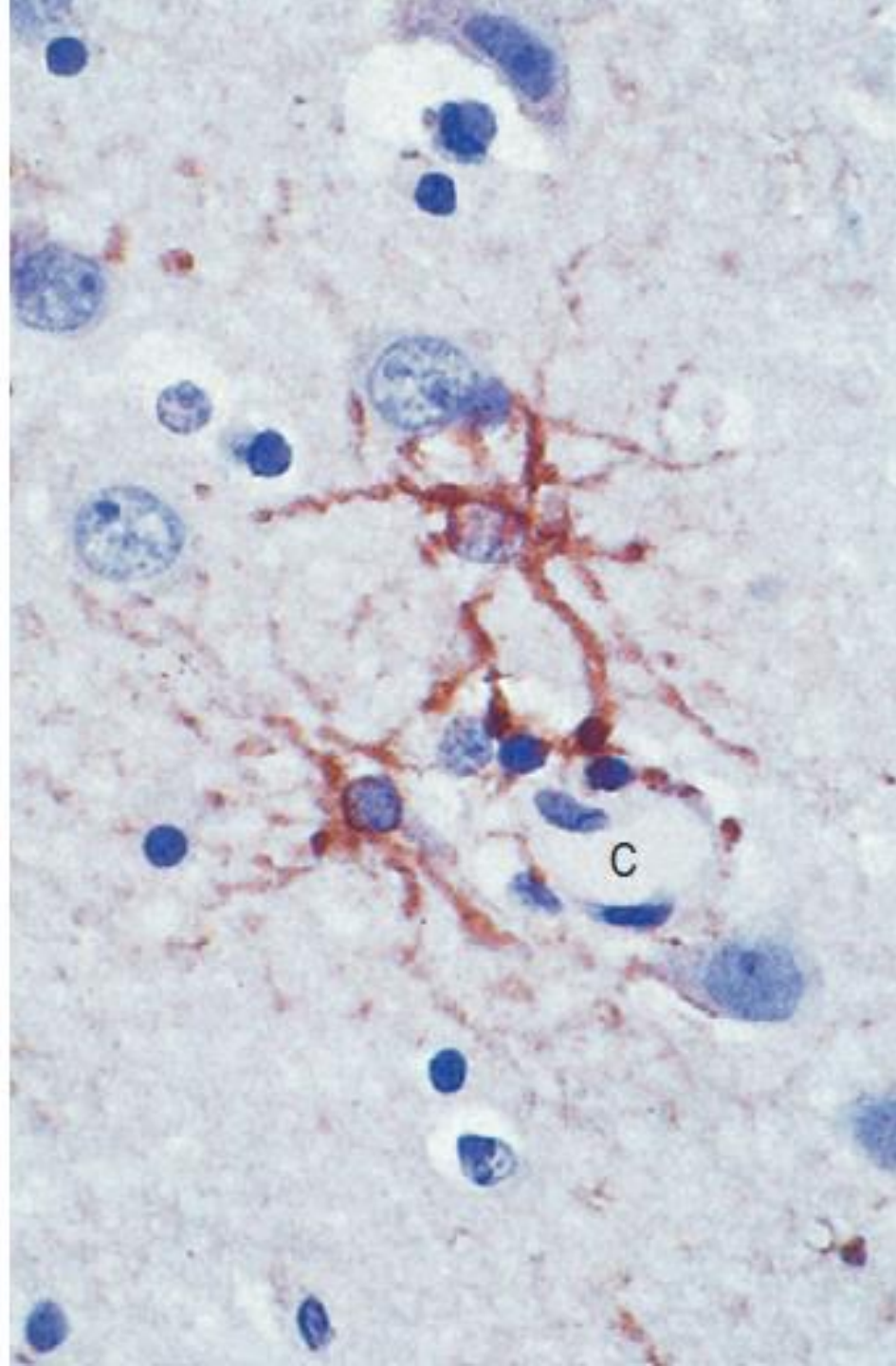
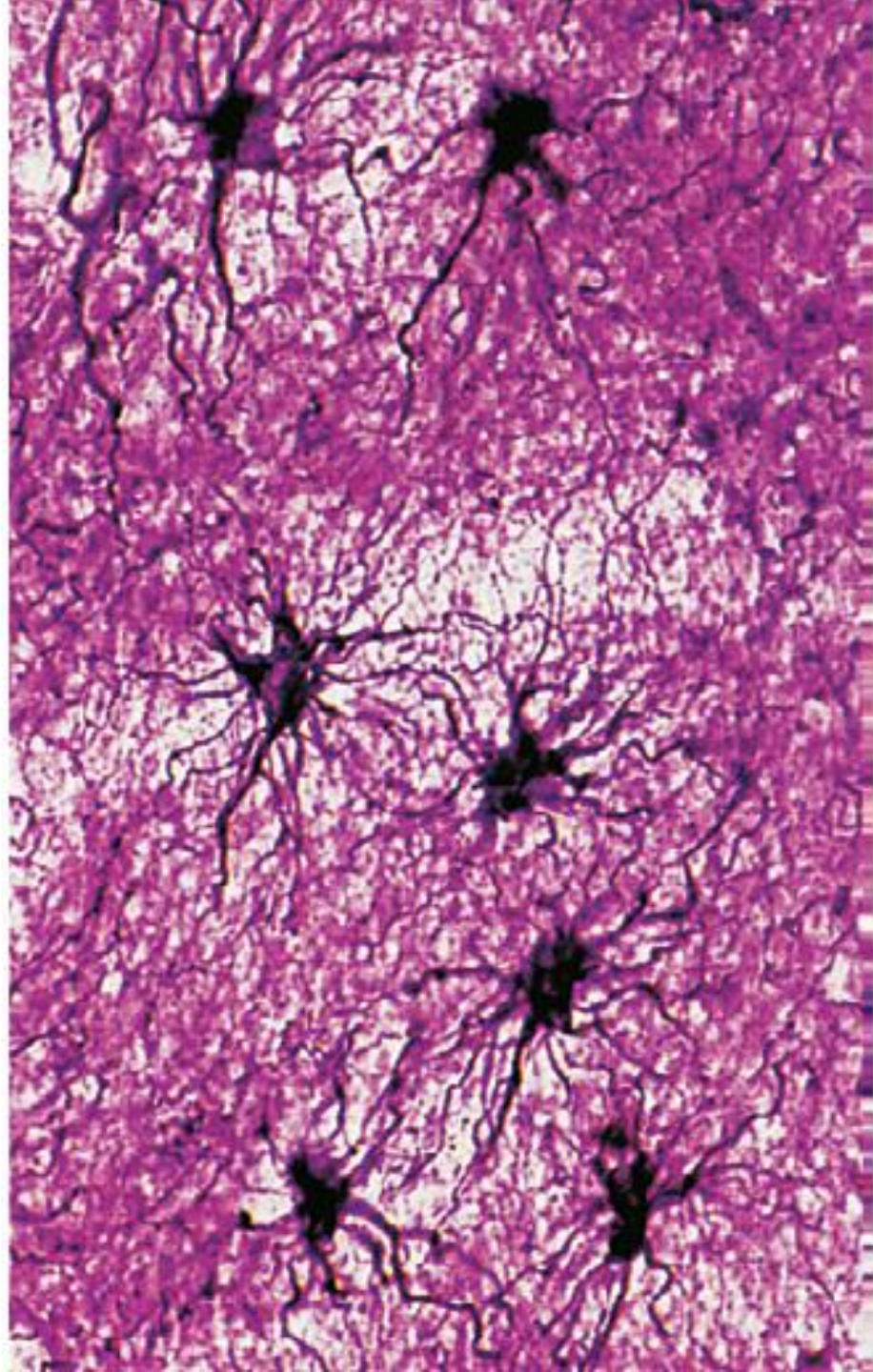


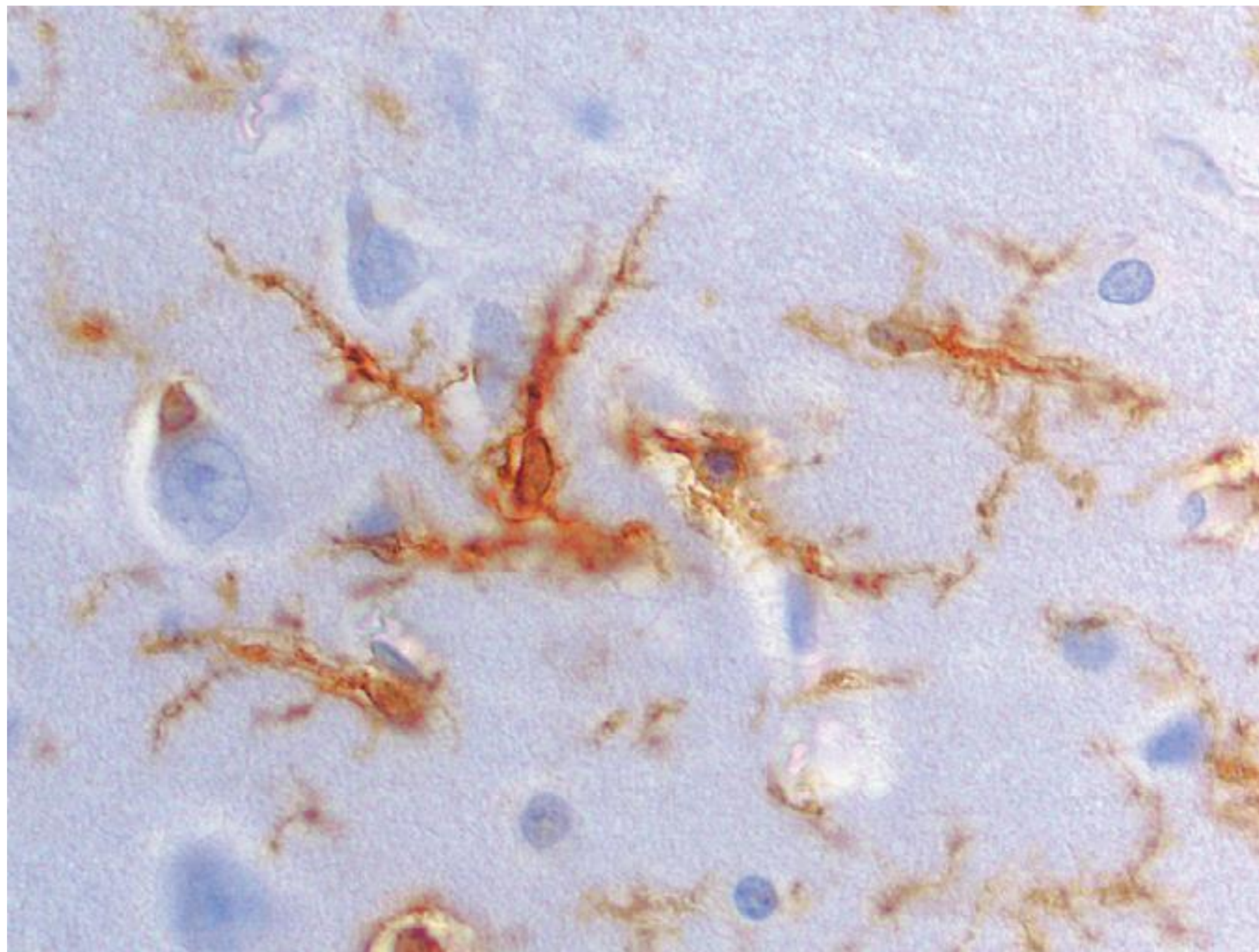
(C) Microglial cell



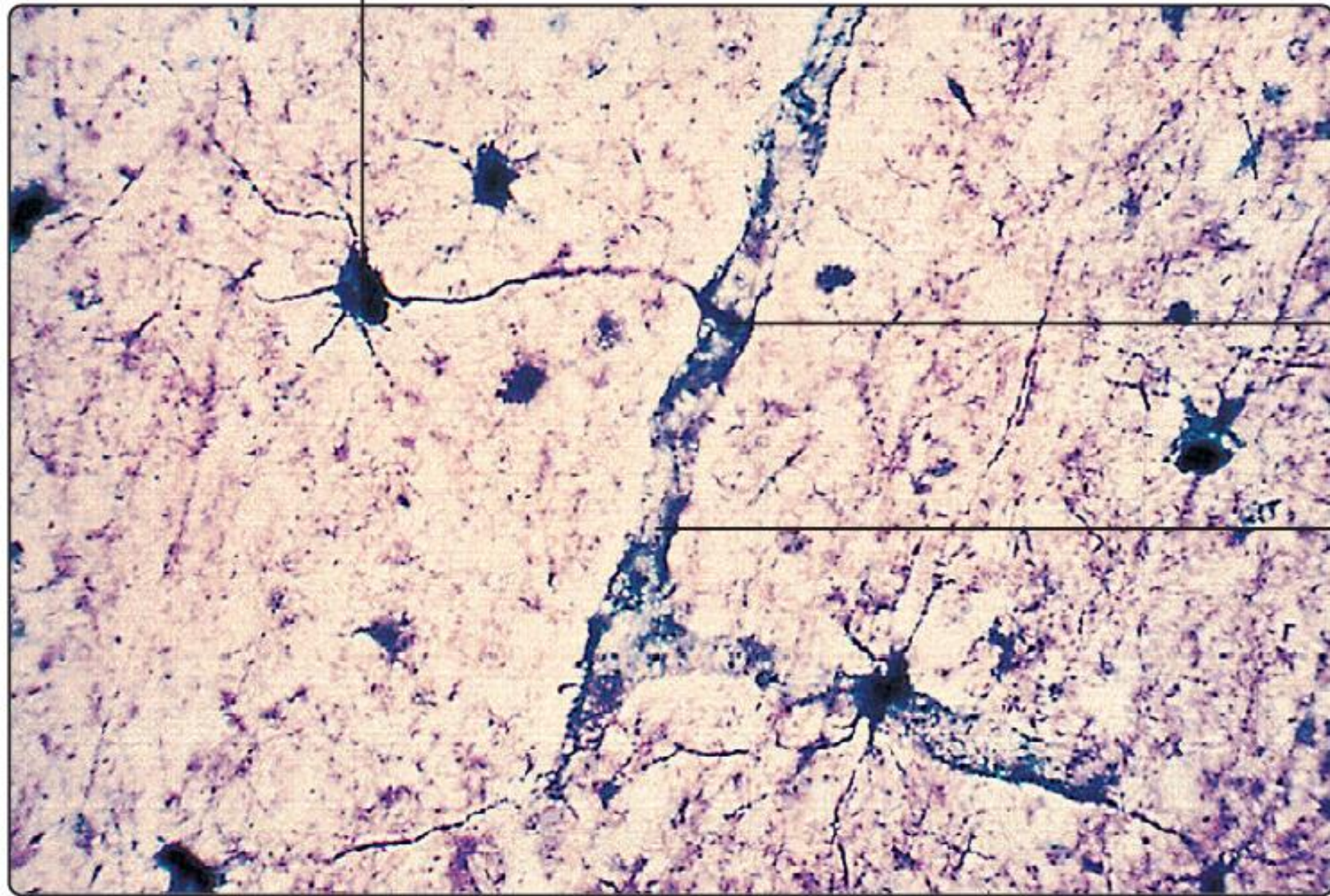








Astrocyte soma



Endfoot

Capillary

PNS

Schwann cell

Axon

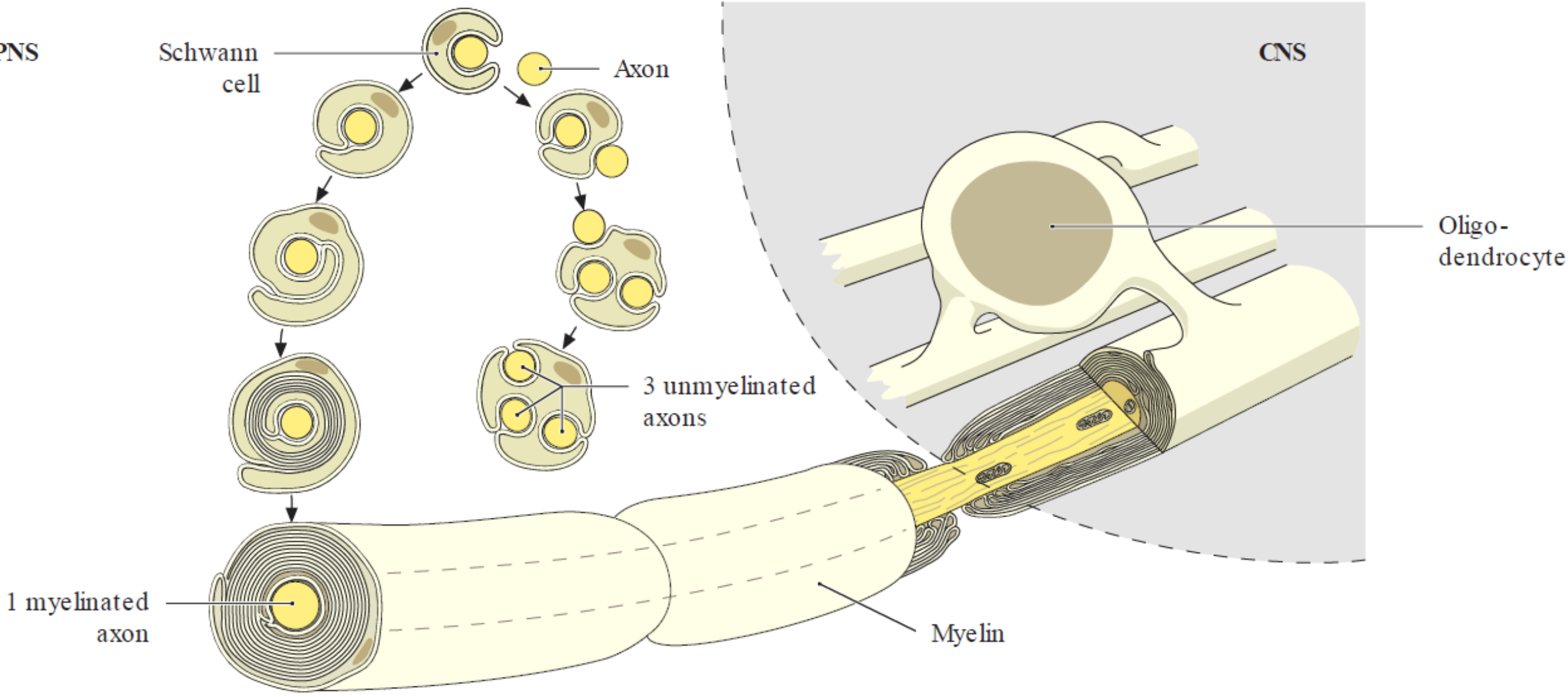
CNS

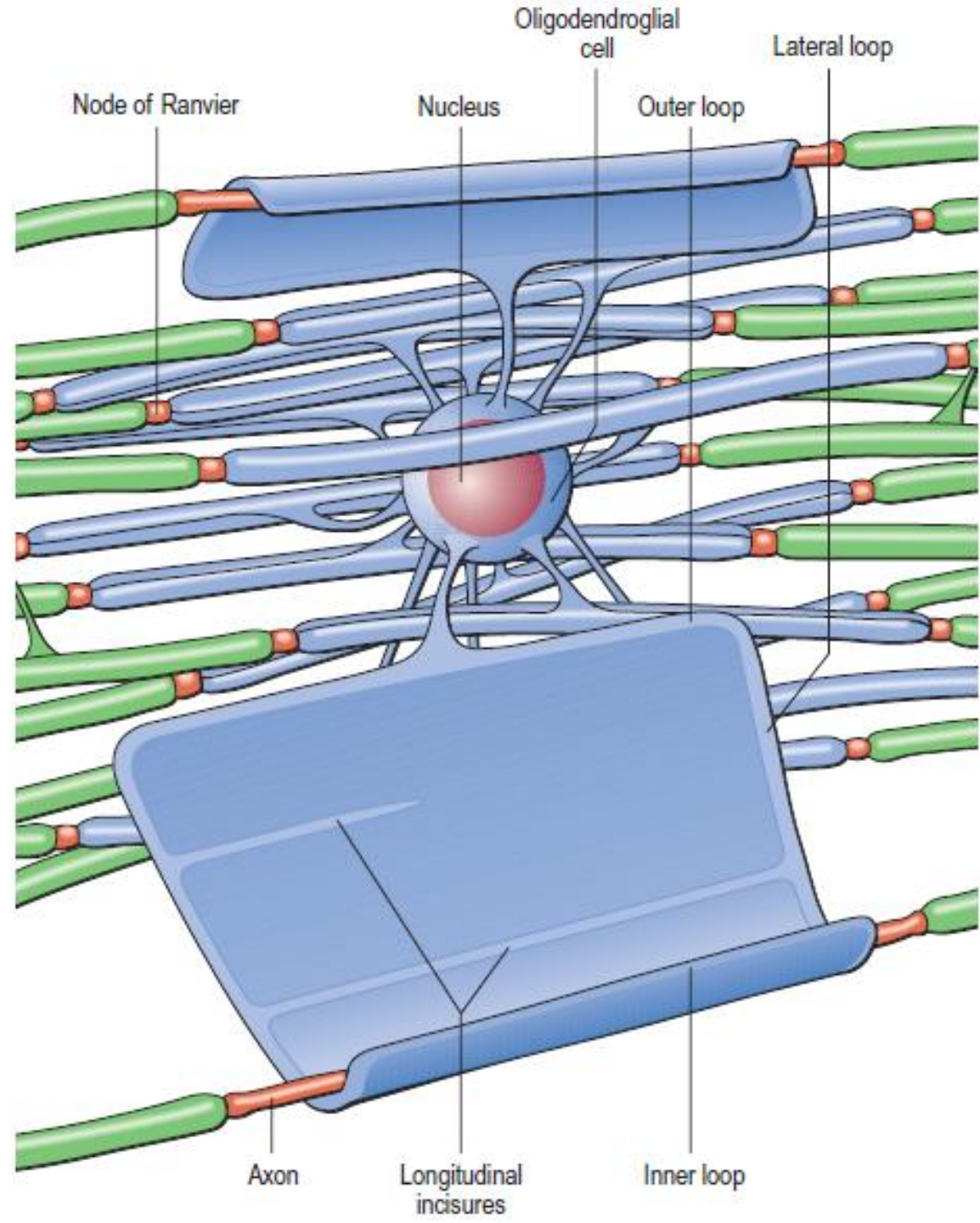
Oligo-dendrocyte

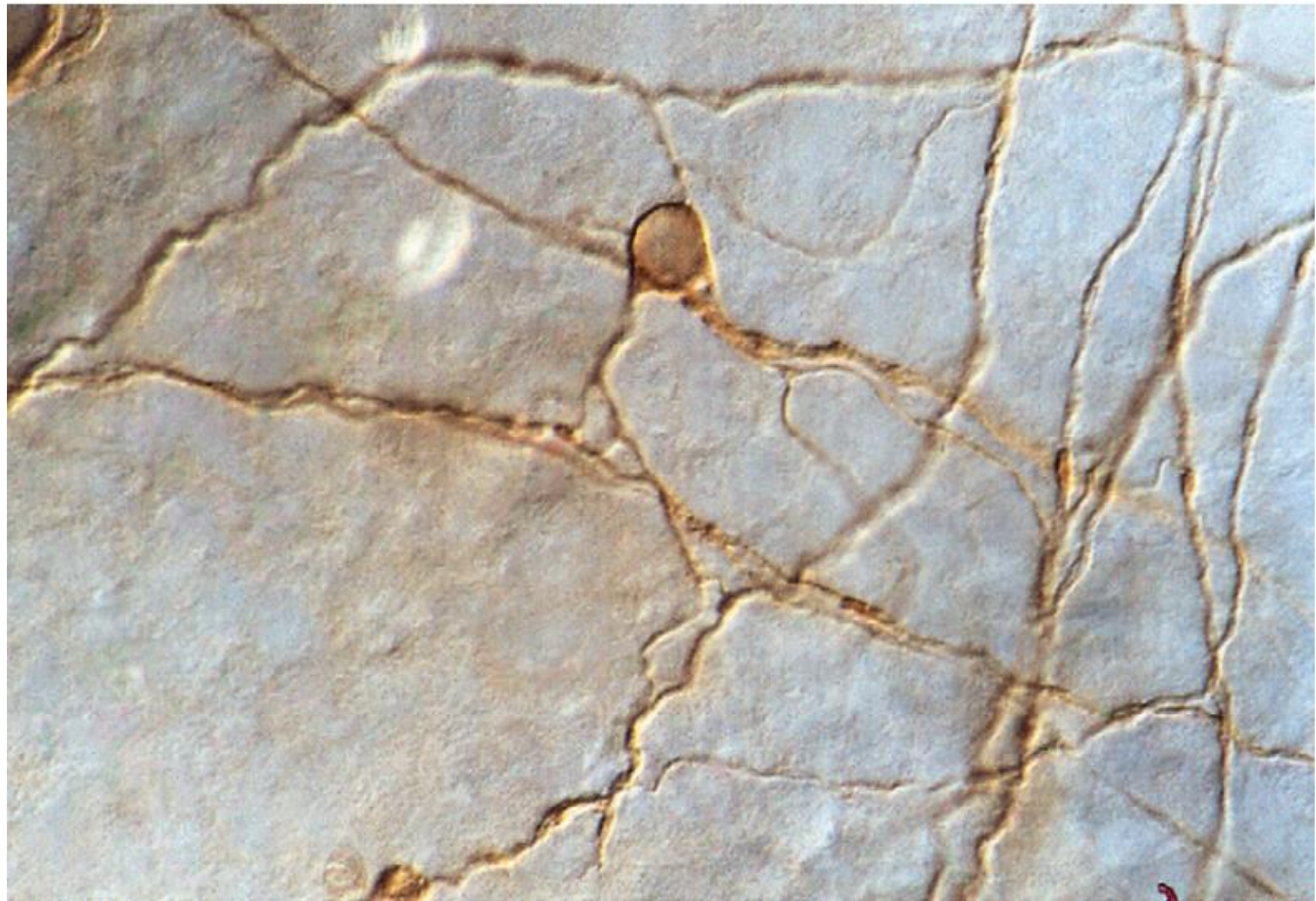
3 unmyelinated axons

1 myelinated axon

Myelin

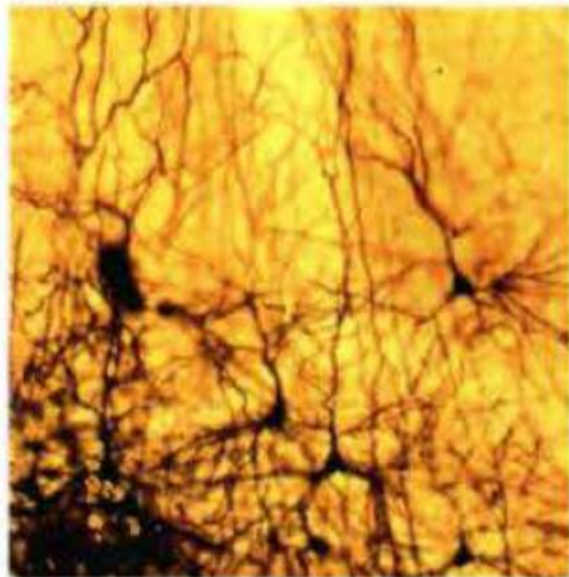




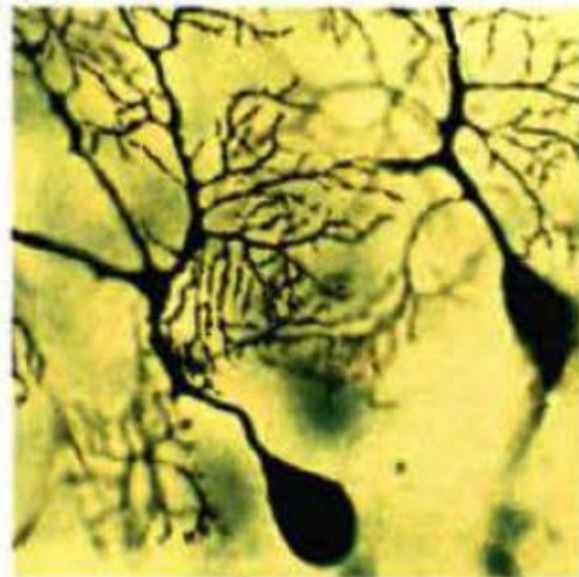


Compartimento Neuronal

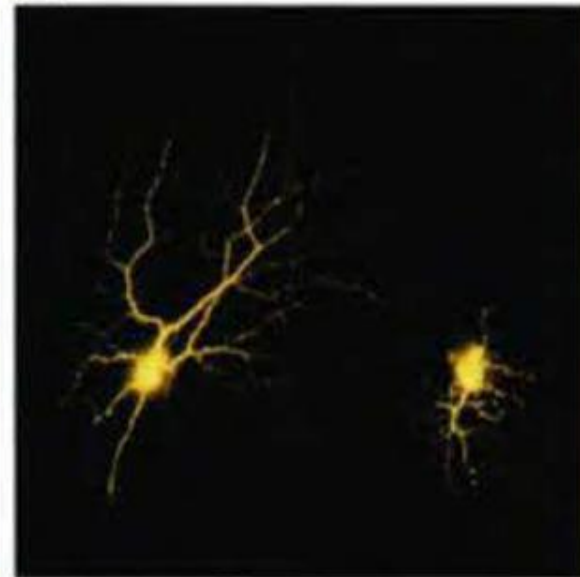
(A)



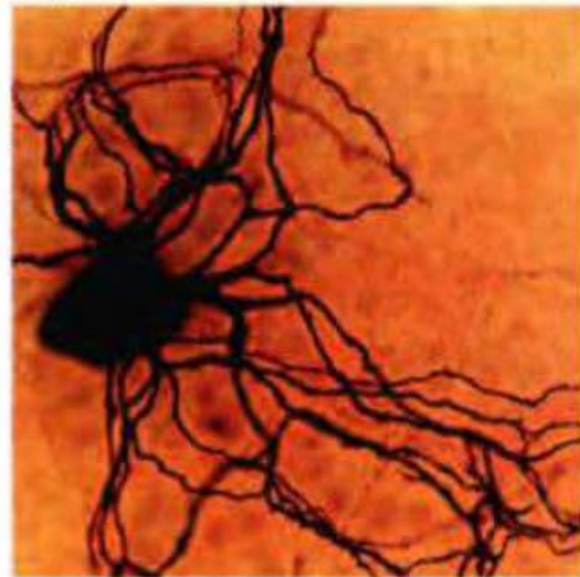(B)

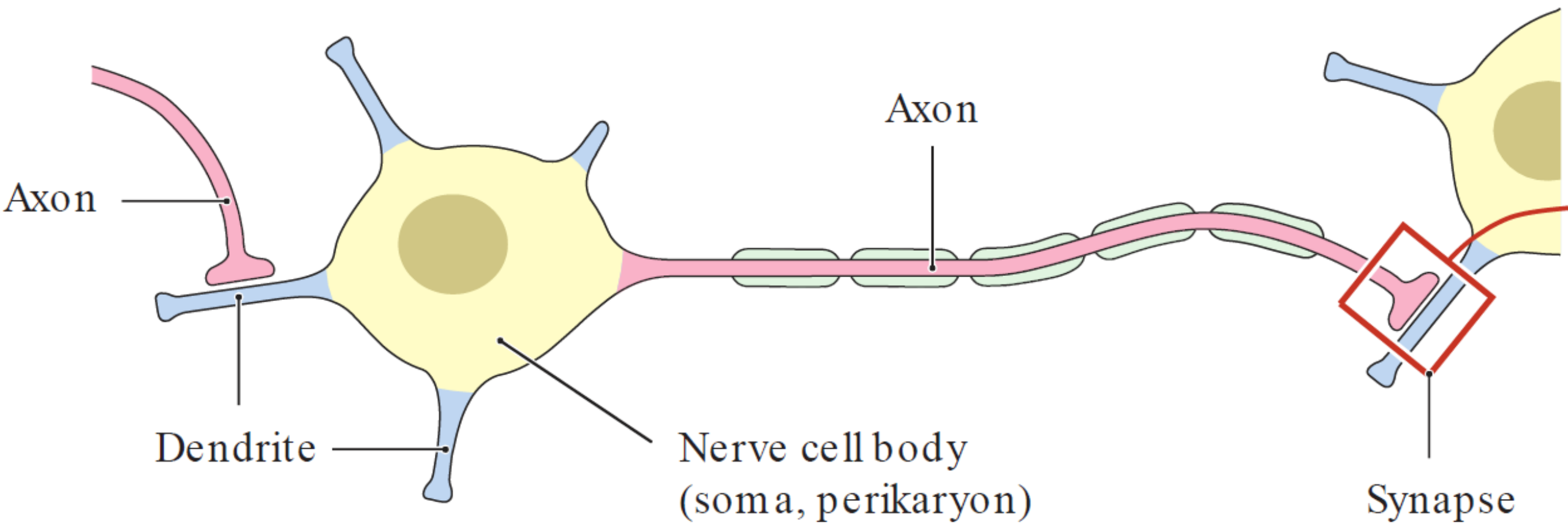


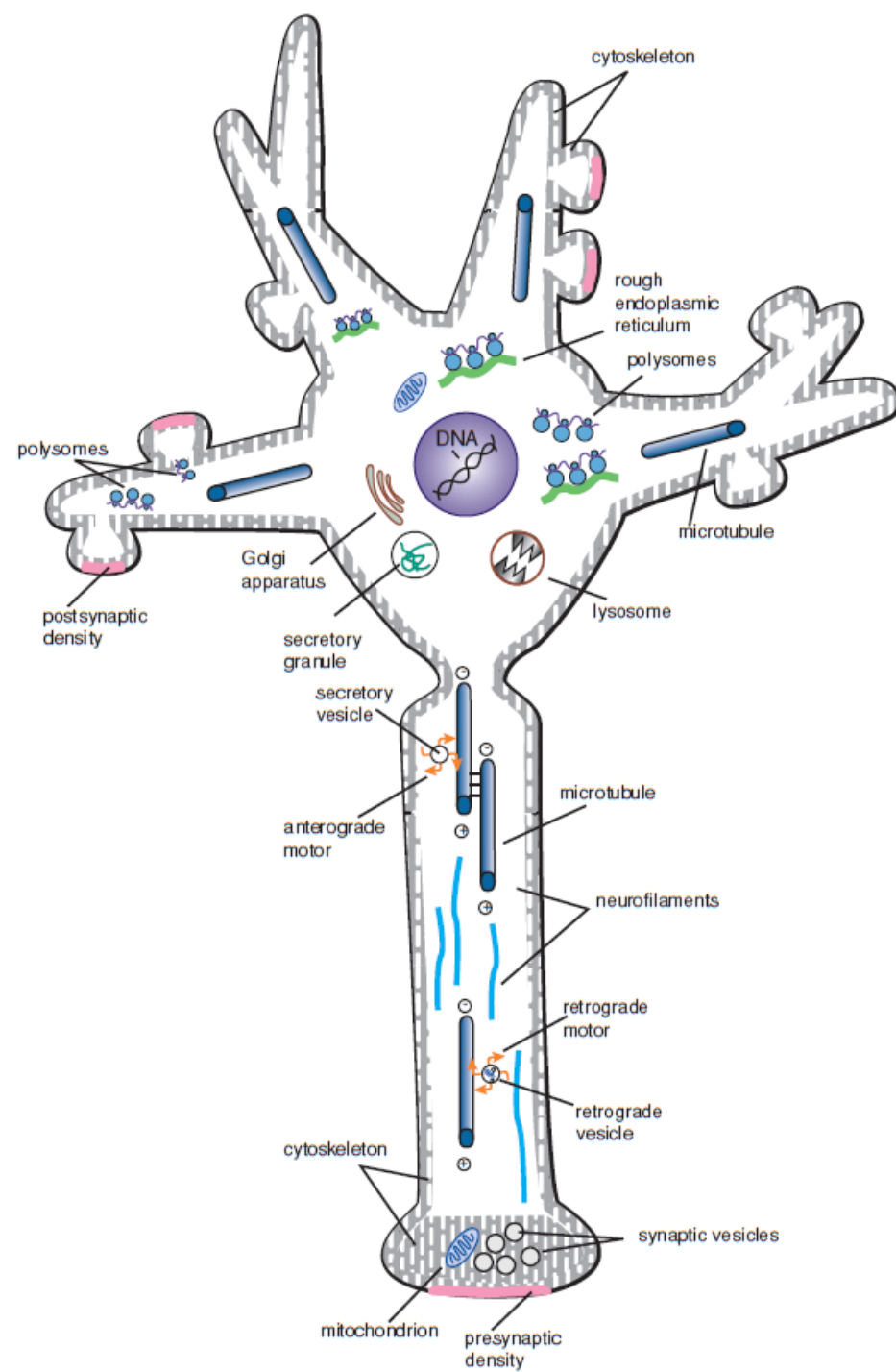
(C)



(D)

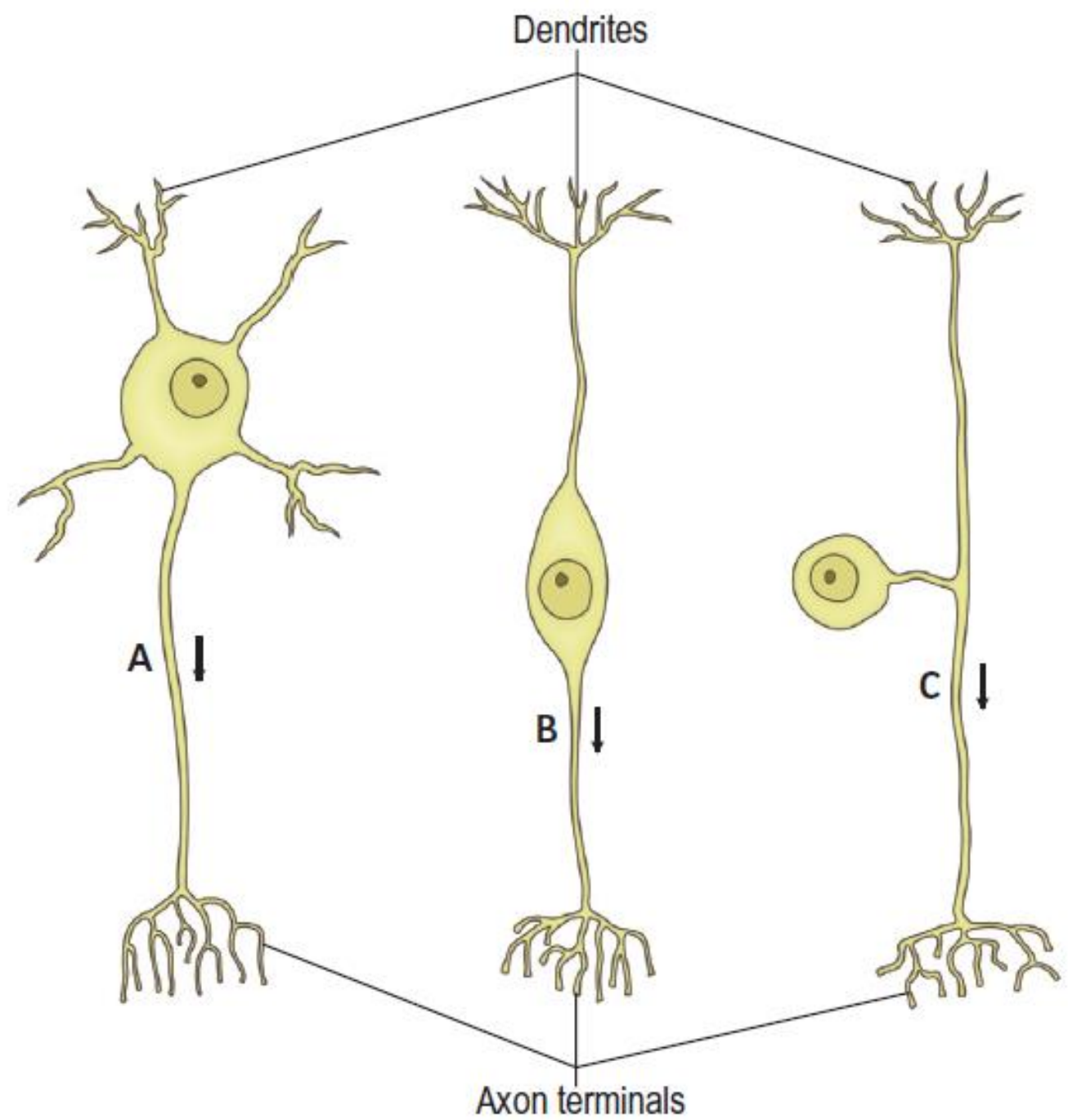


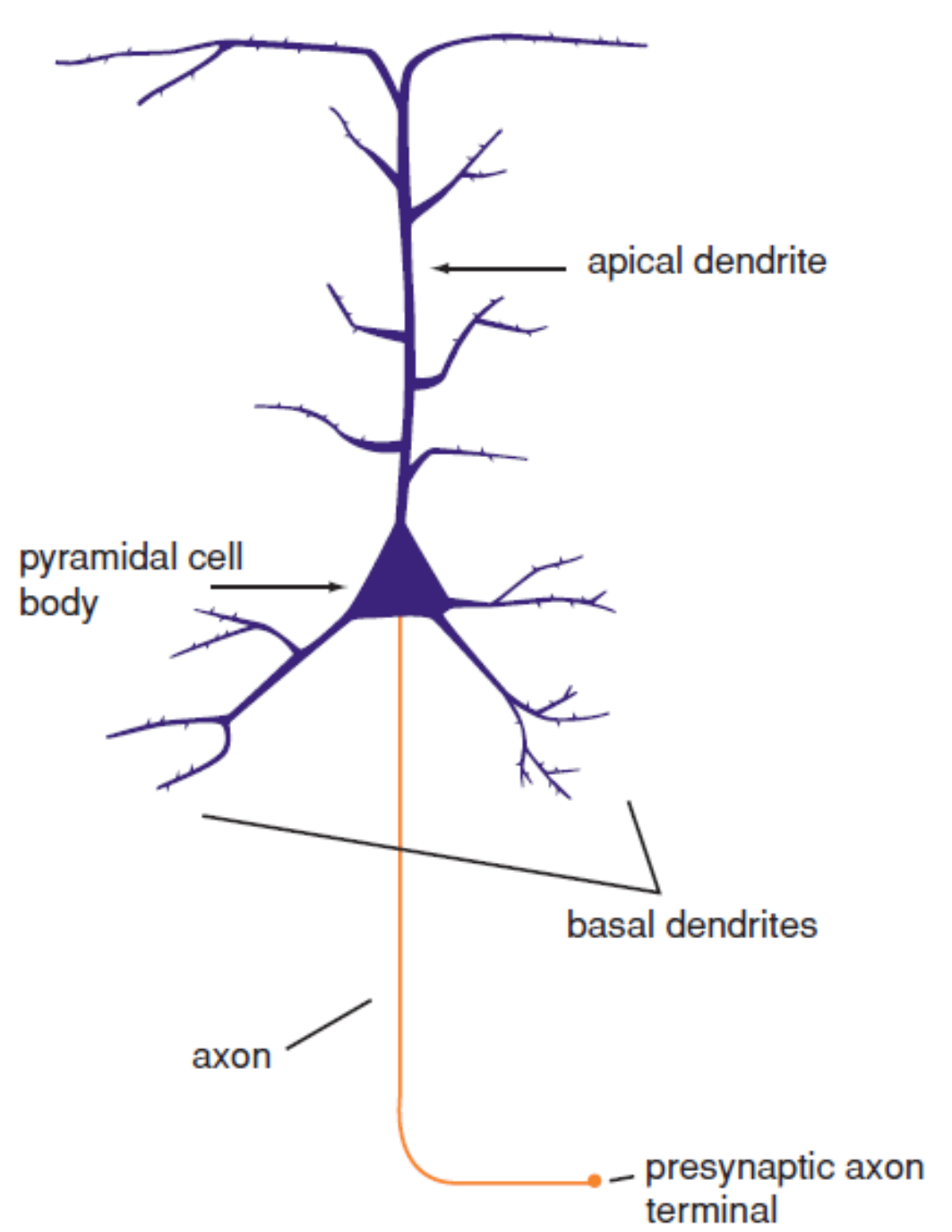
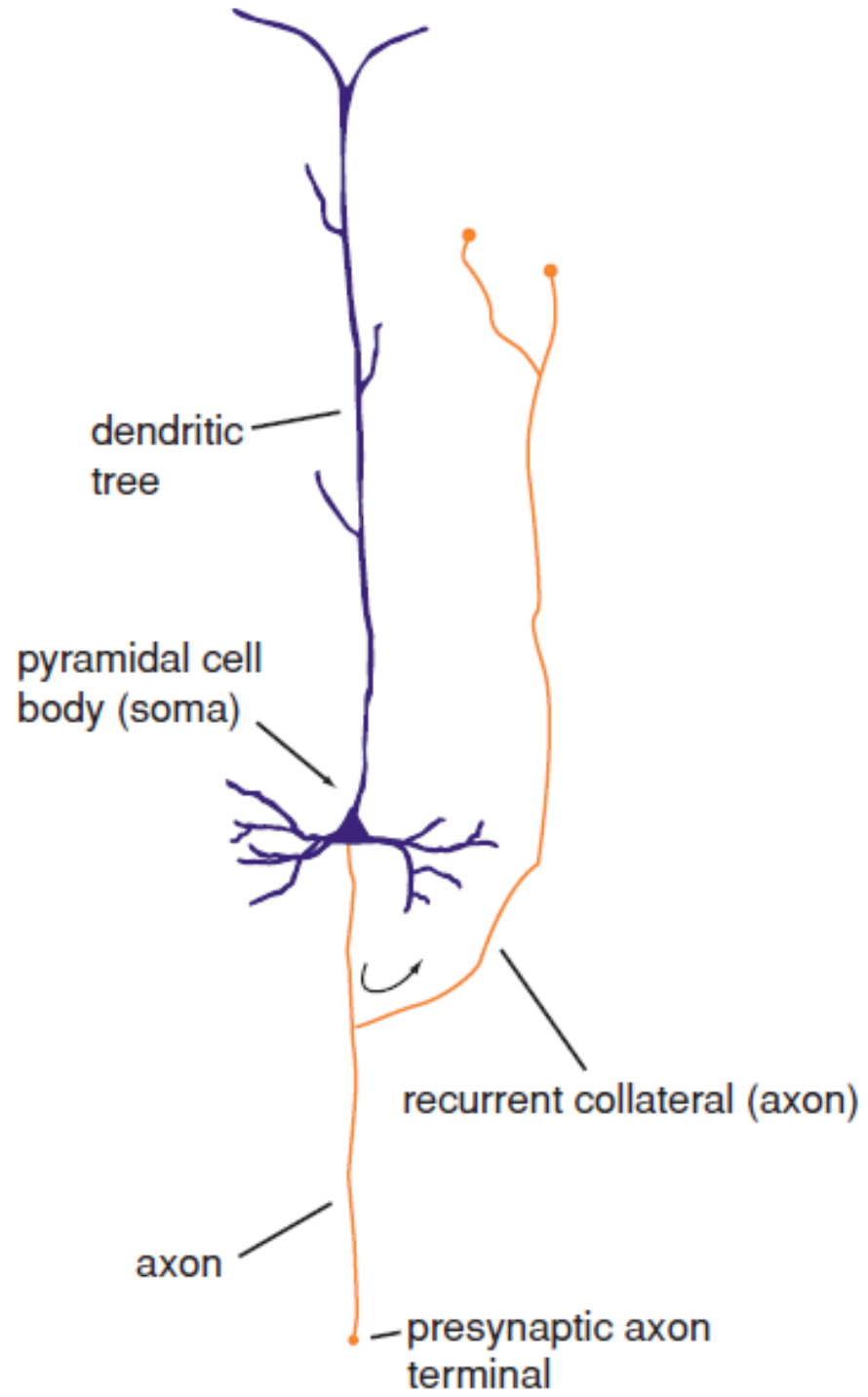




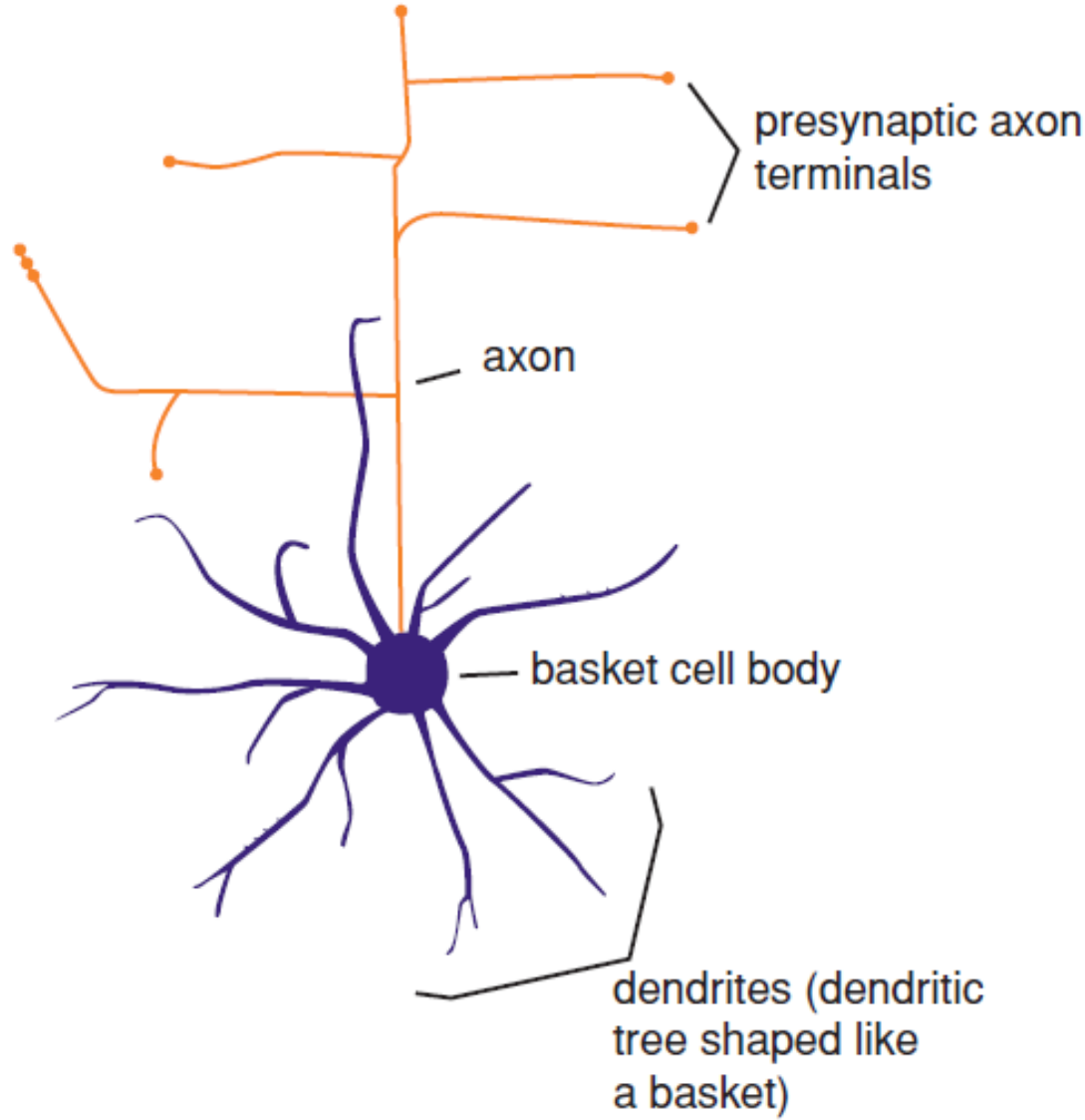
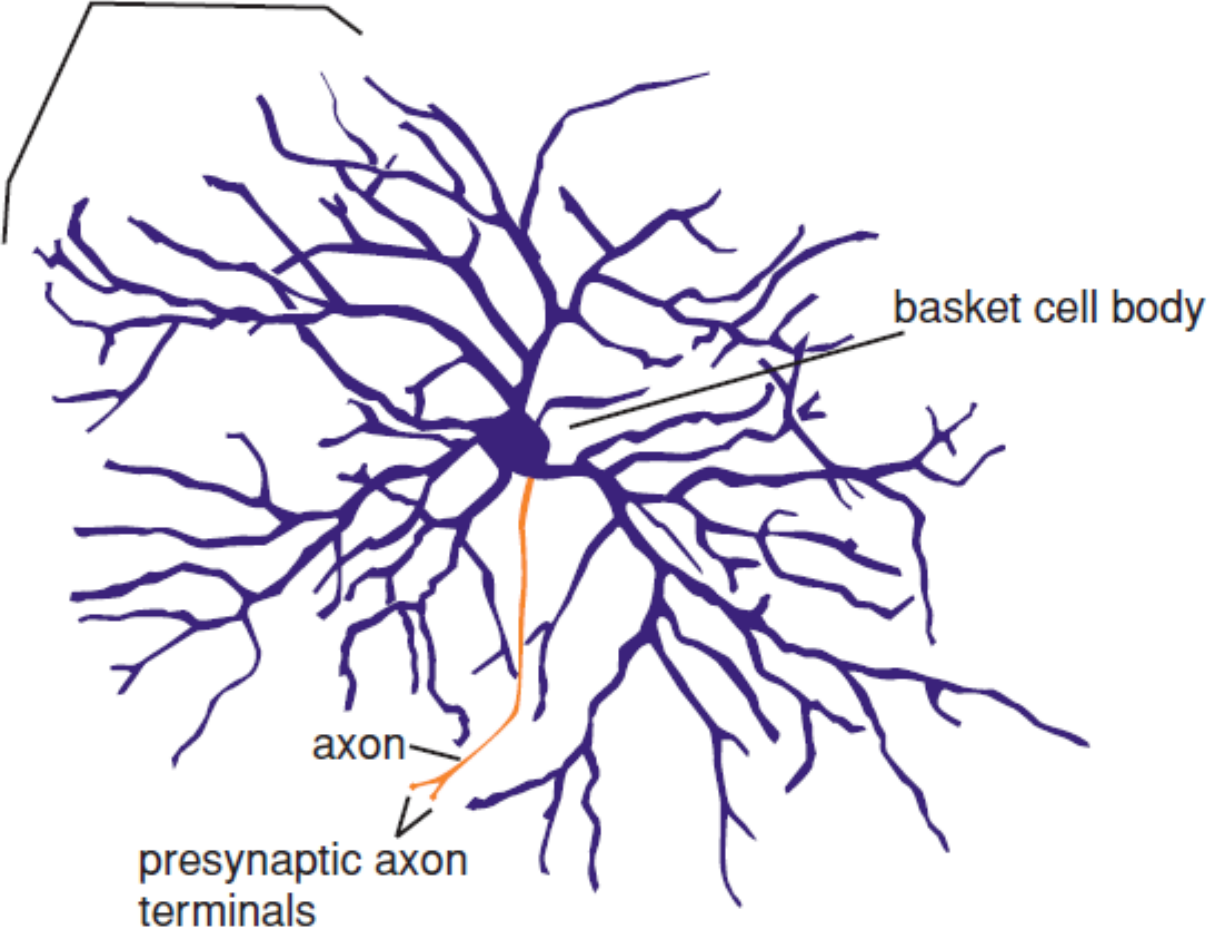
Clasificación Neuronas

- Procesos: Monopolares, Bipolares, Multipolares.
- Morfología Soma: Piramidales, Estrelladas, Fusiformes.
- Funcional: Motoras, Sensitivas, Asociativas.
- Somáticas – Vegetativas.
- Longitud del Axón:
 - Golgi tipo I
 - Golgi tipo II

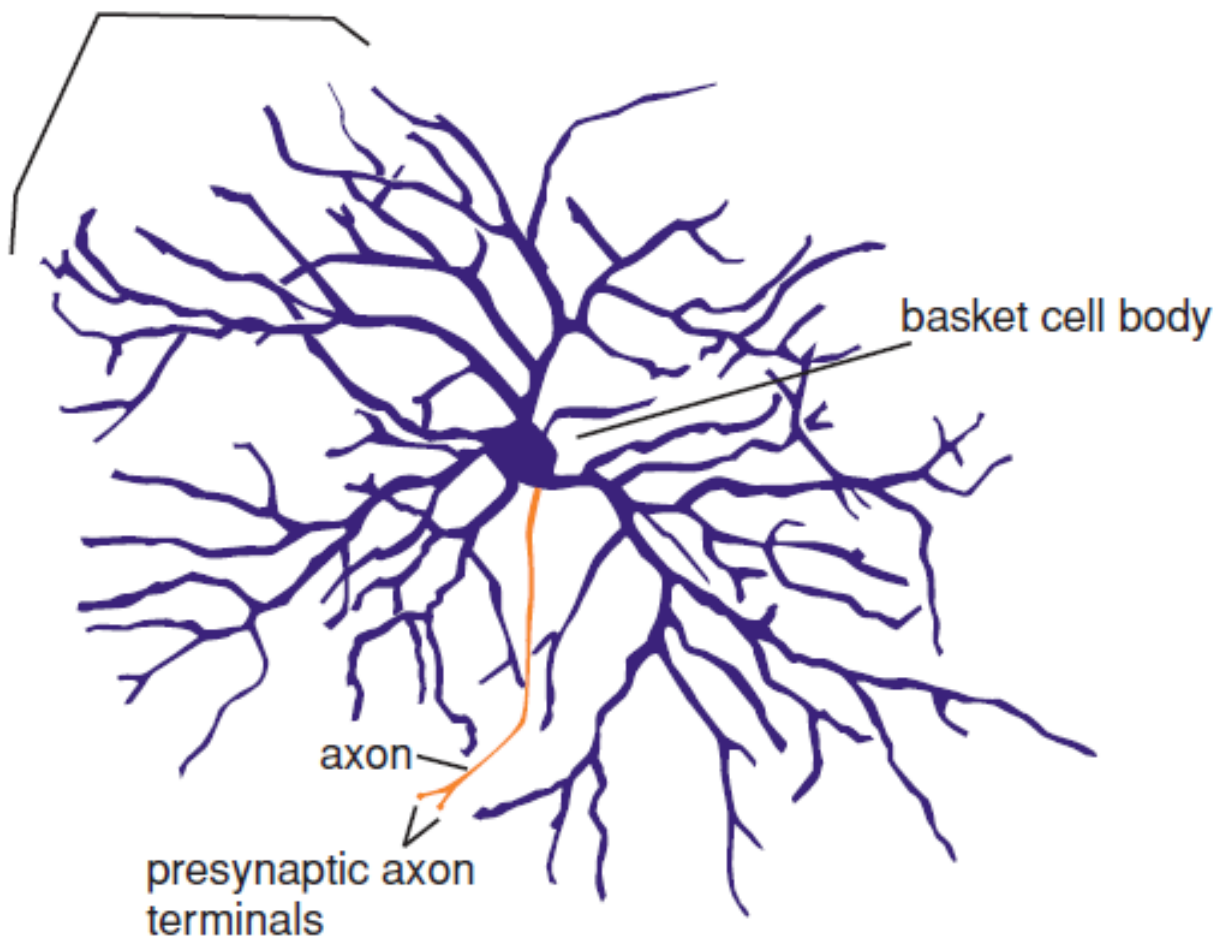




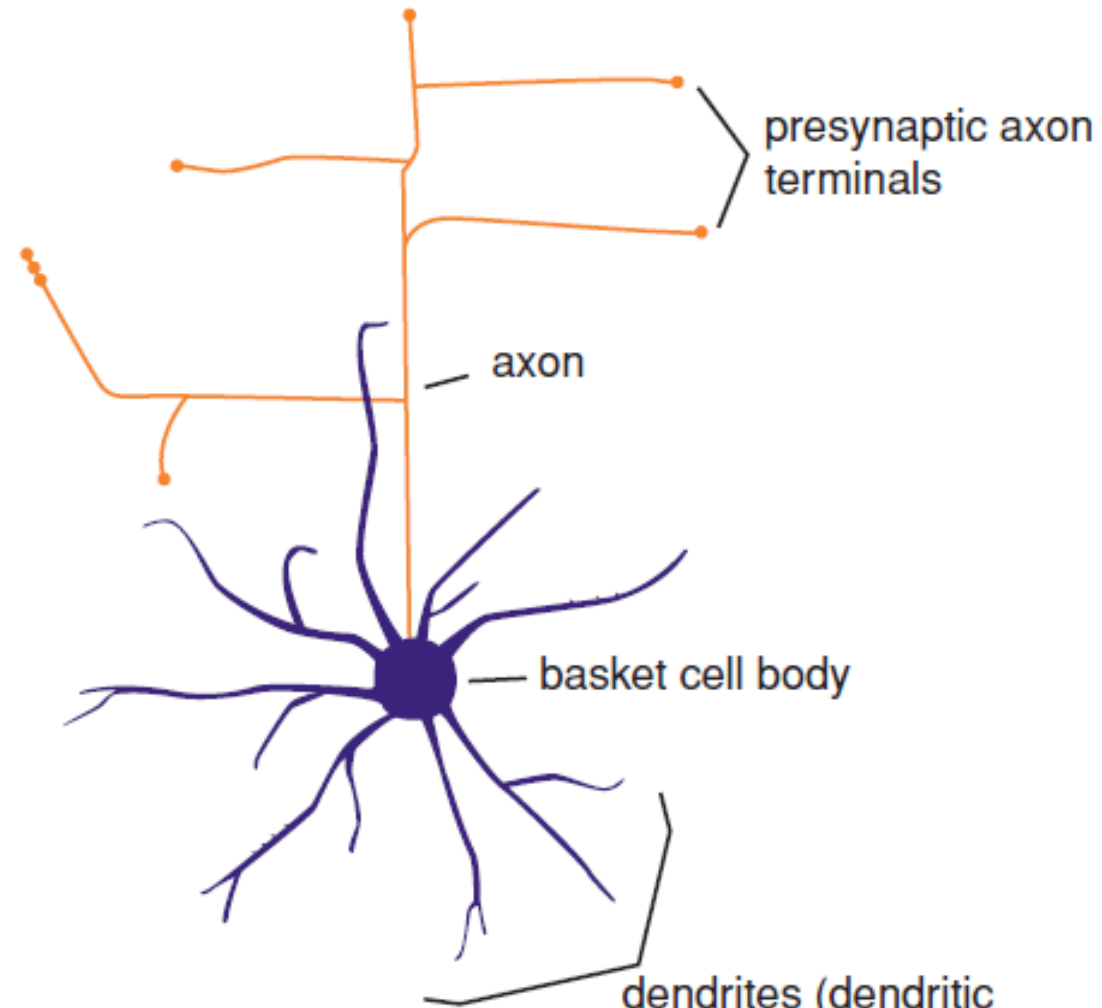
dendrites (dendritic tree shaped like a basket)



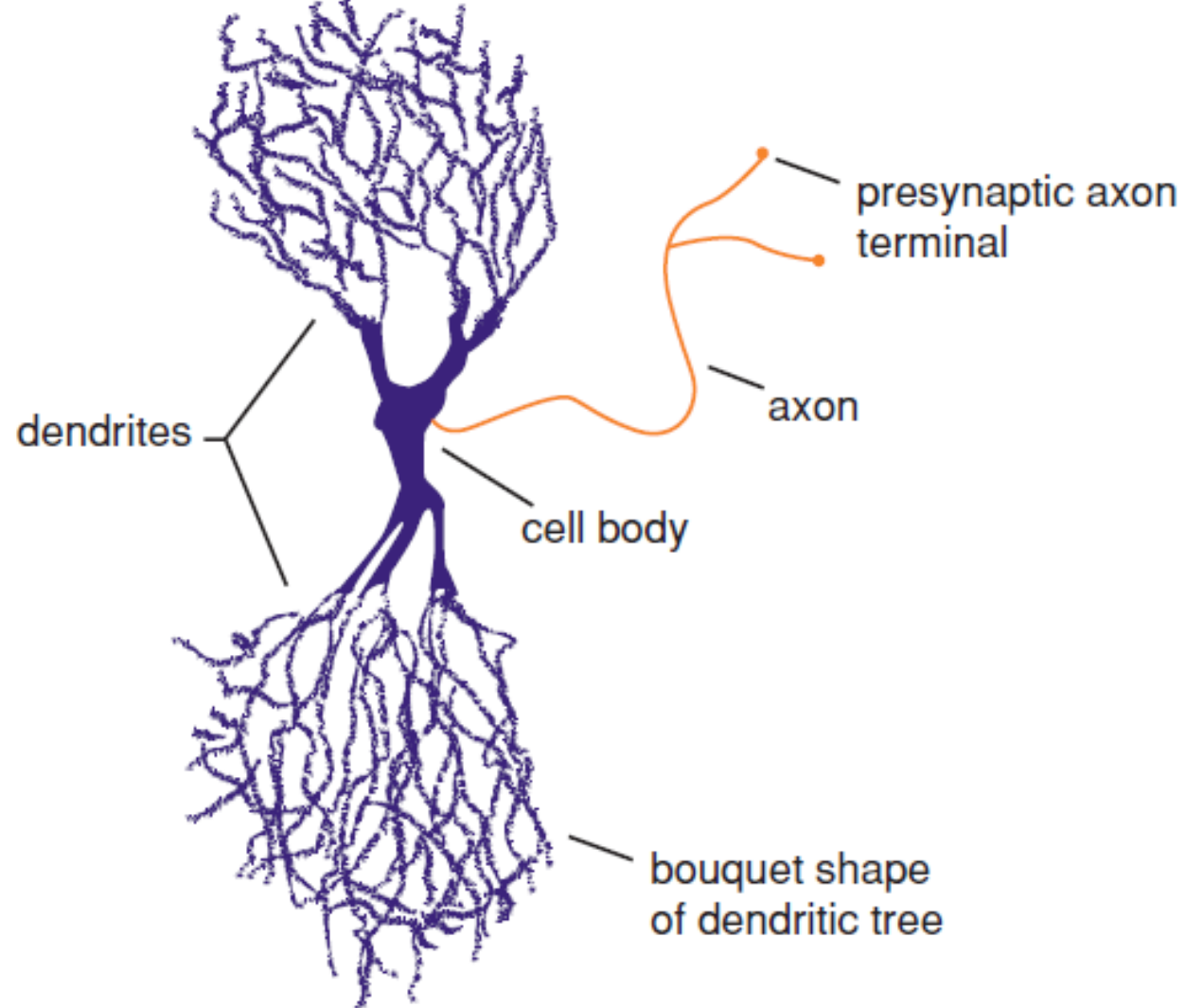
dendrites (dendritic tree shaped like a basket)



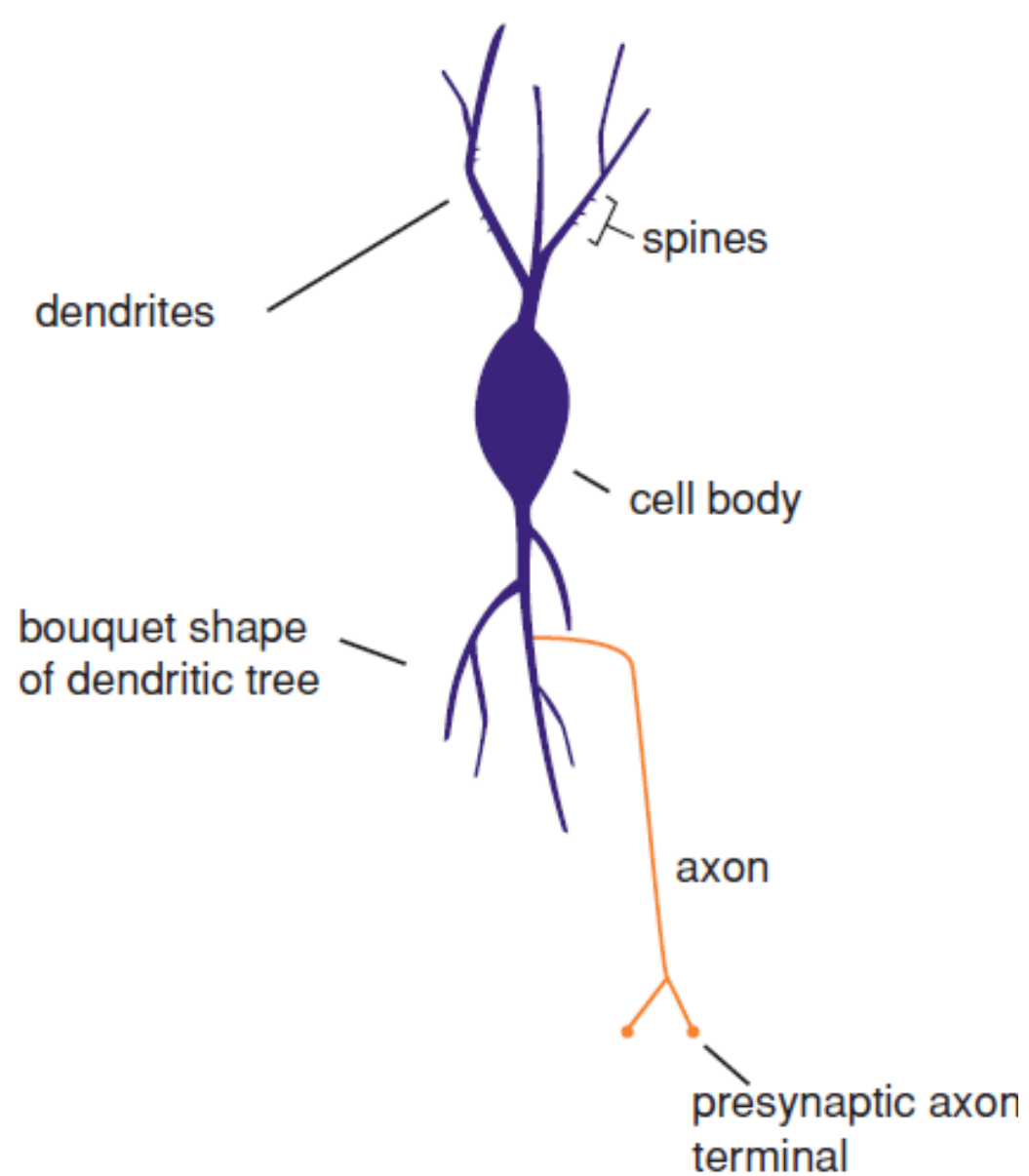
A *realistic basket cell*



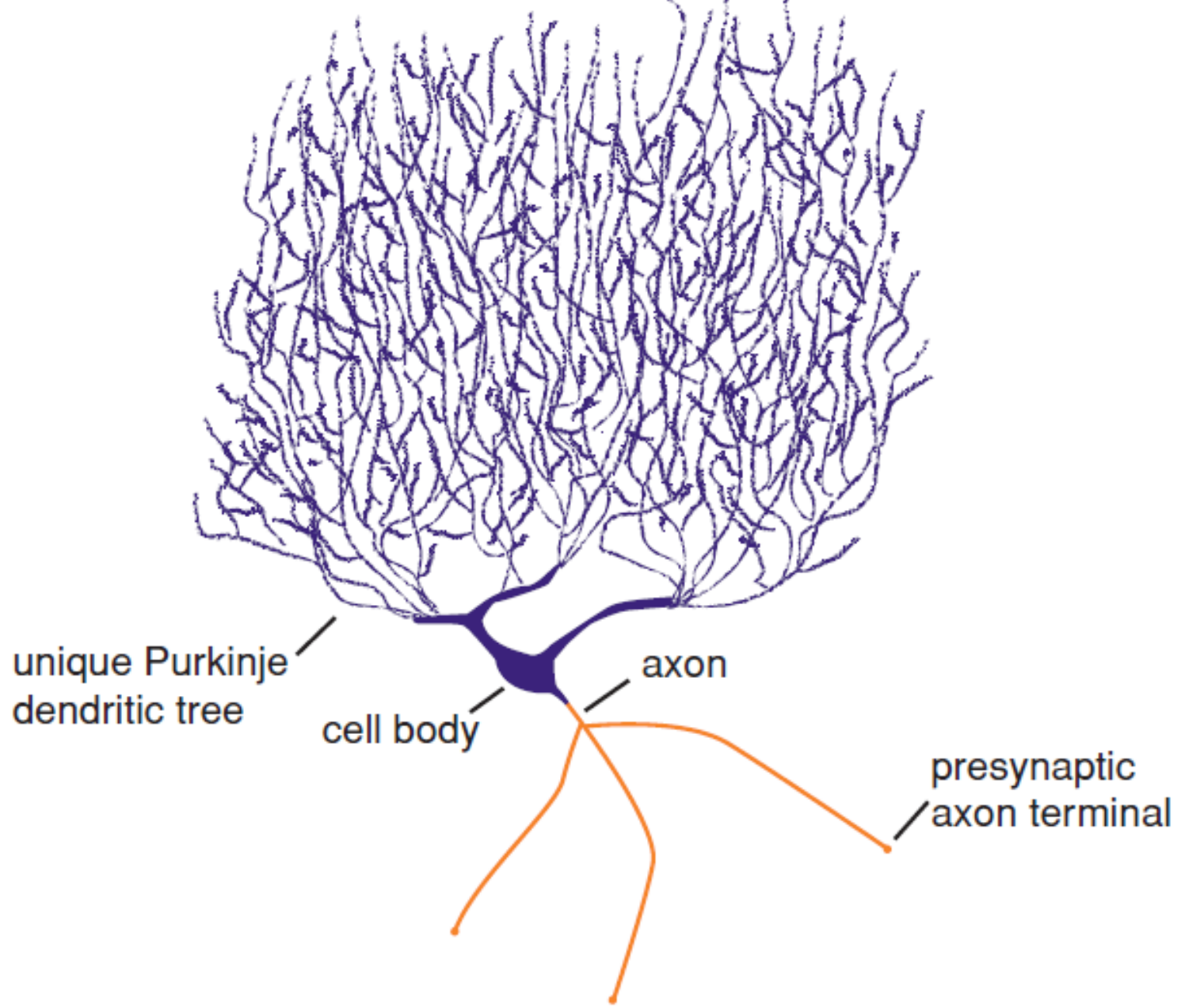
B *icon of basket cell*



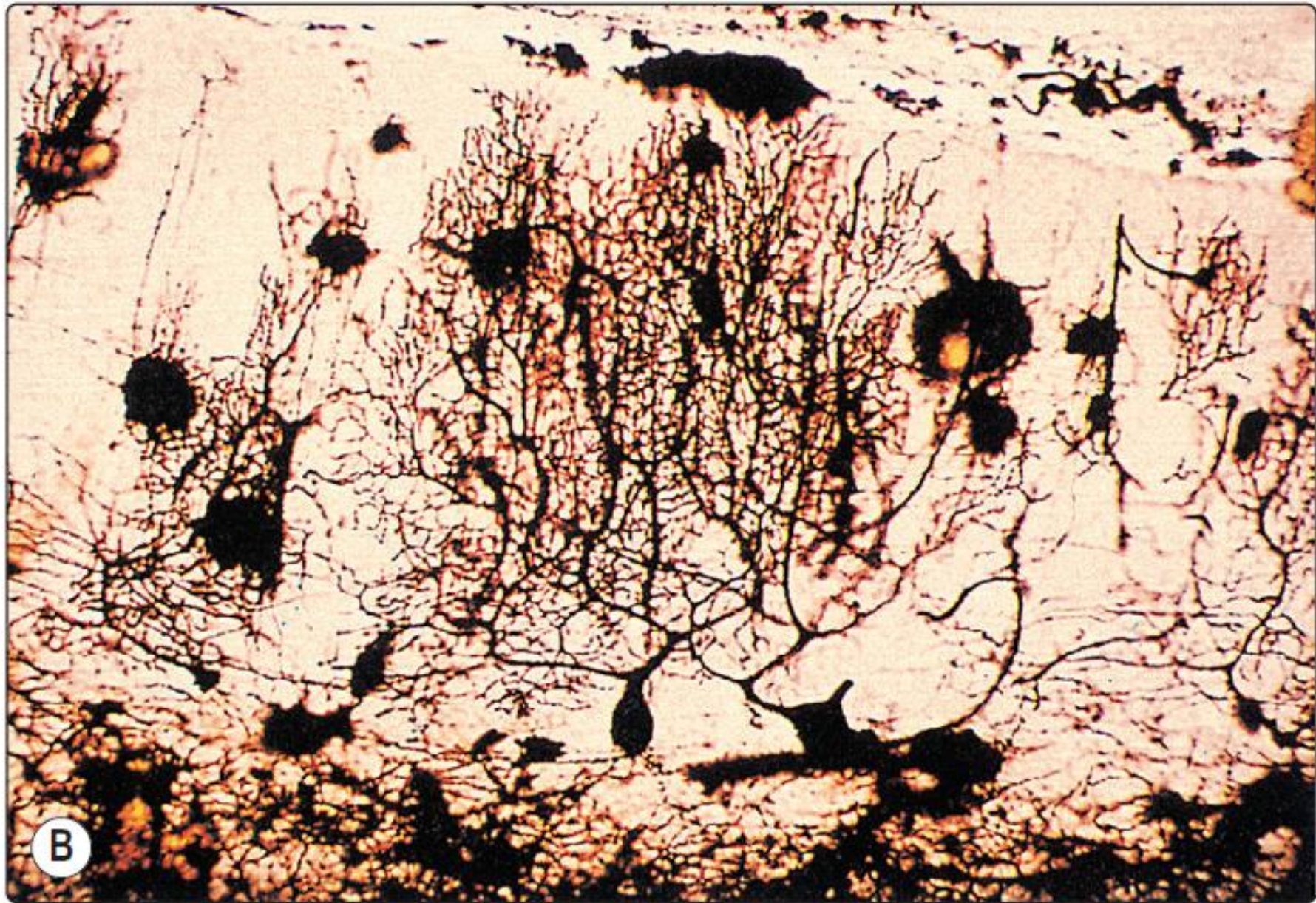A *realistic double bouquet cell*

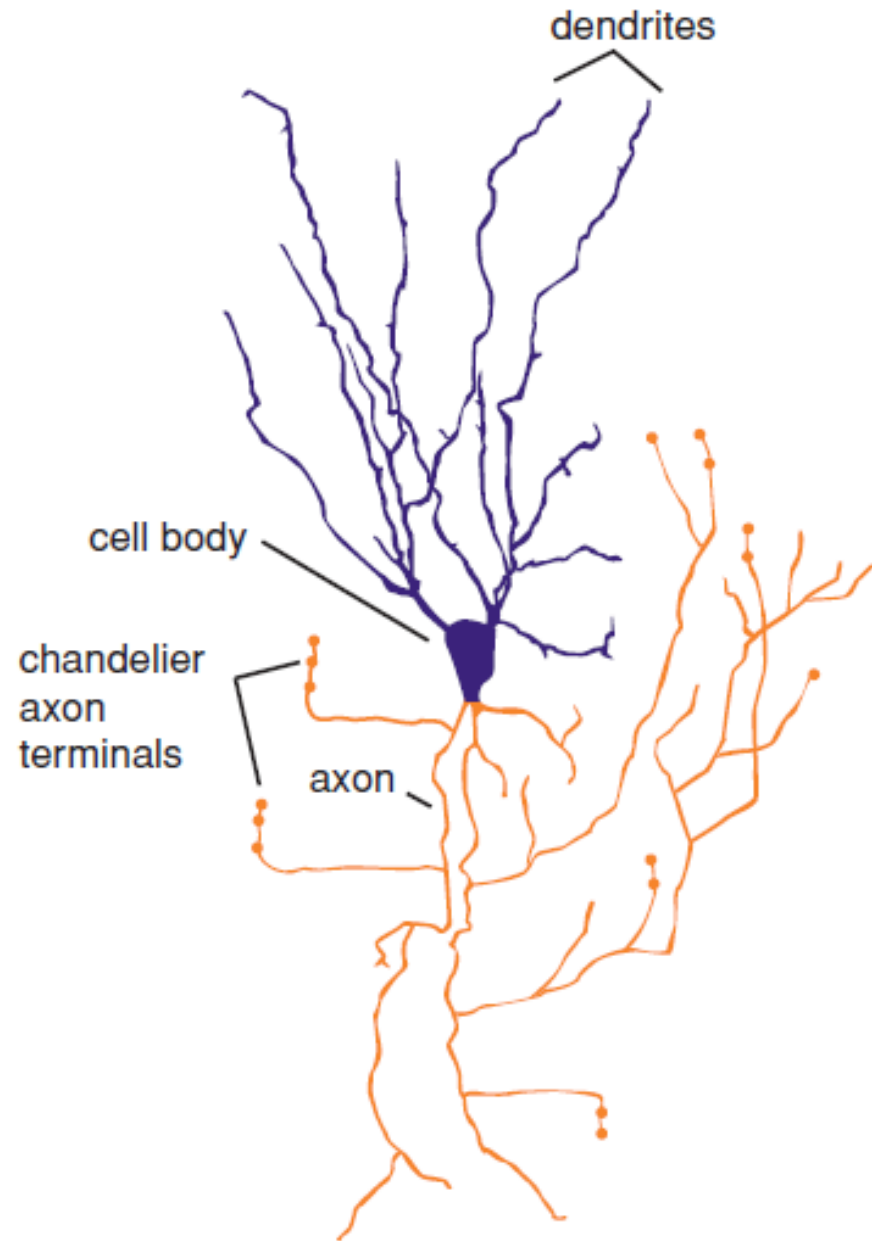


B *icon of double bouquet cell*

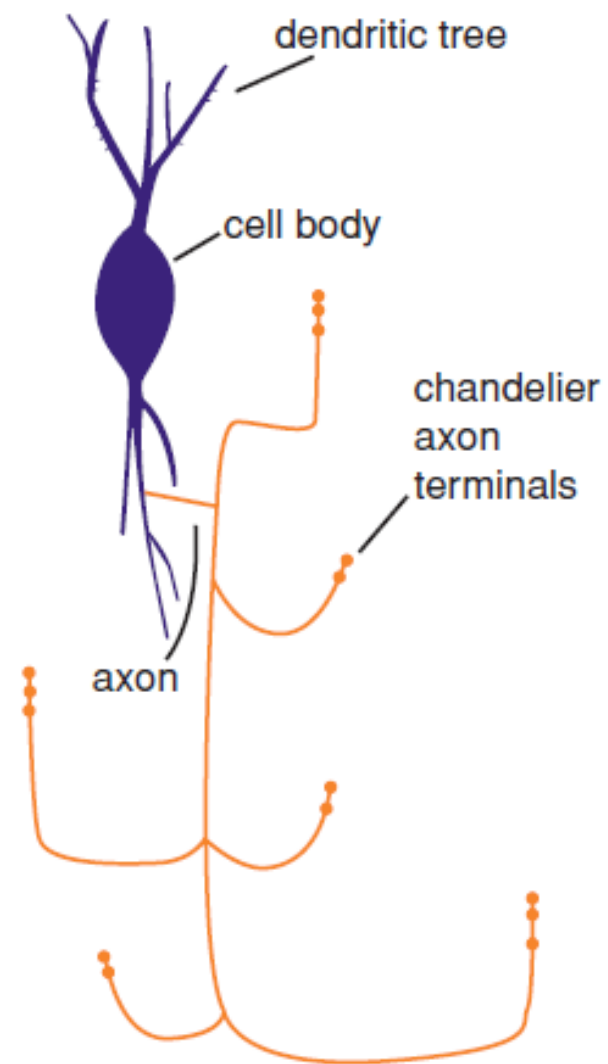


Purkinje cell

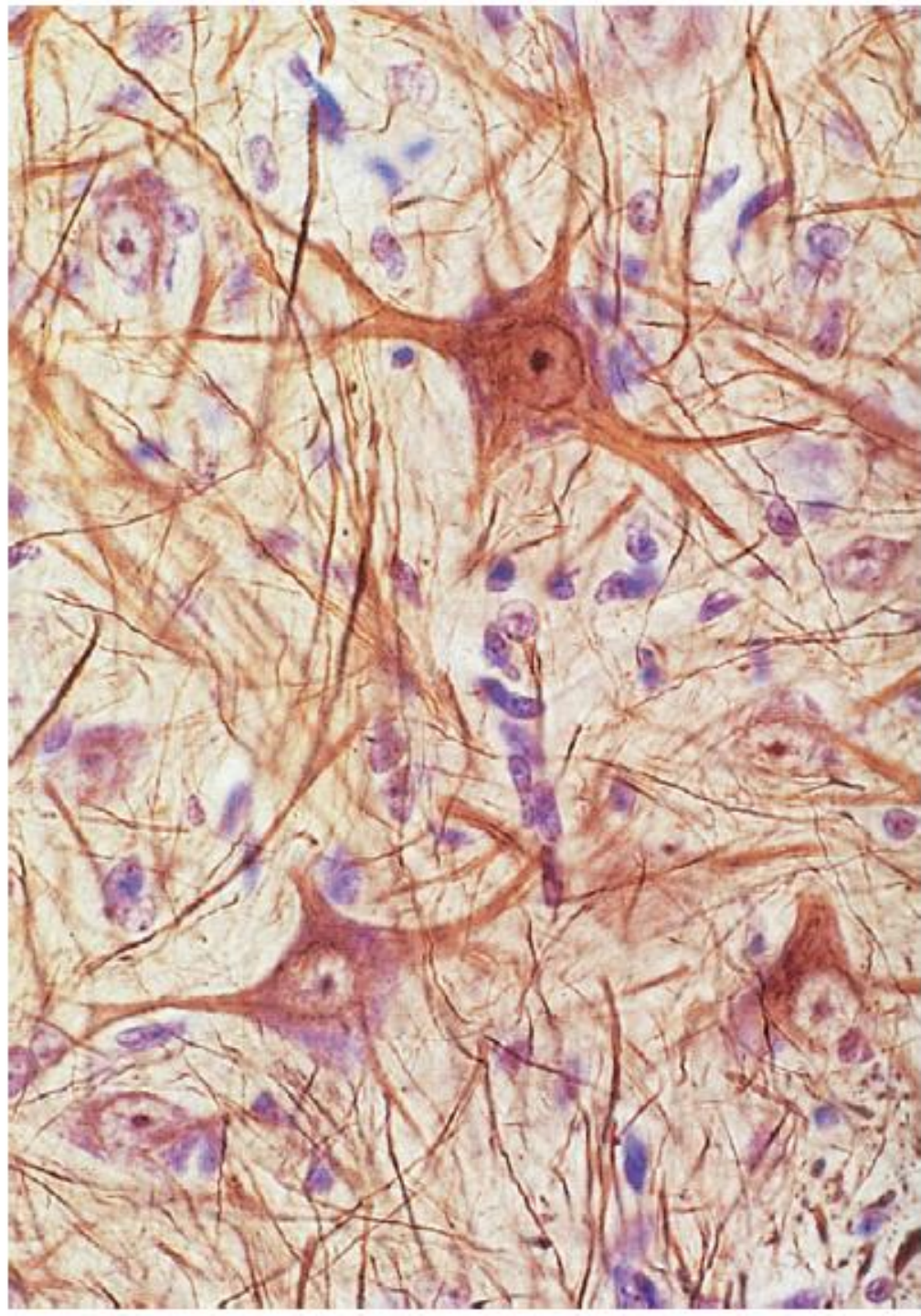


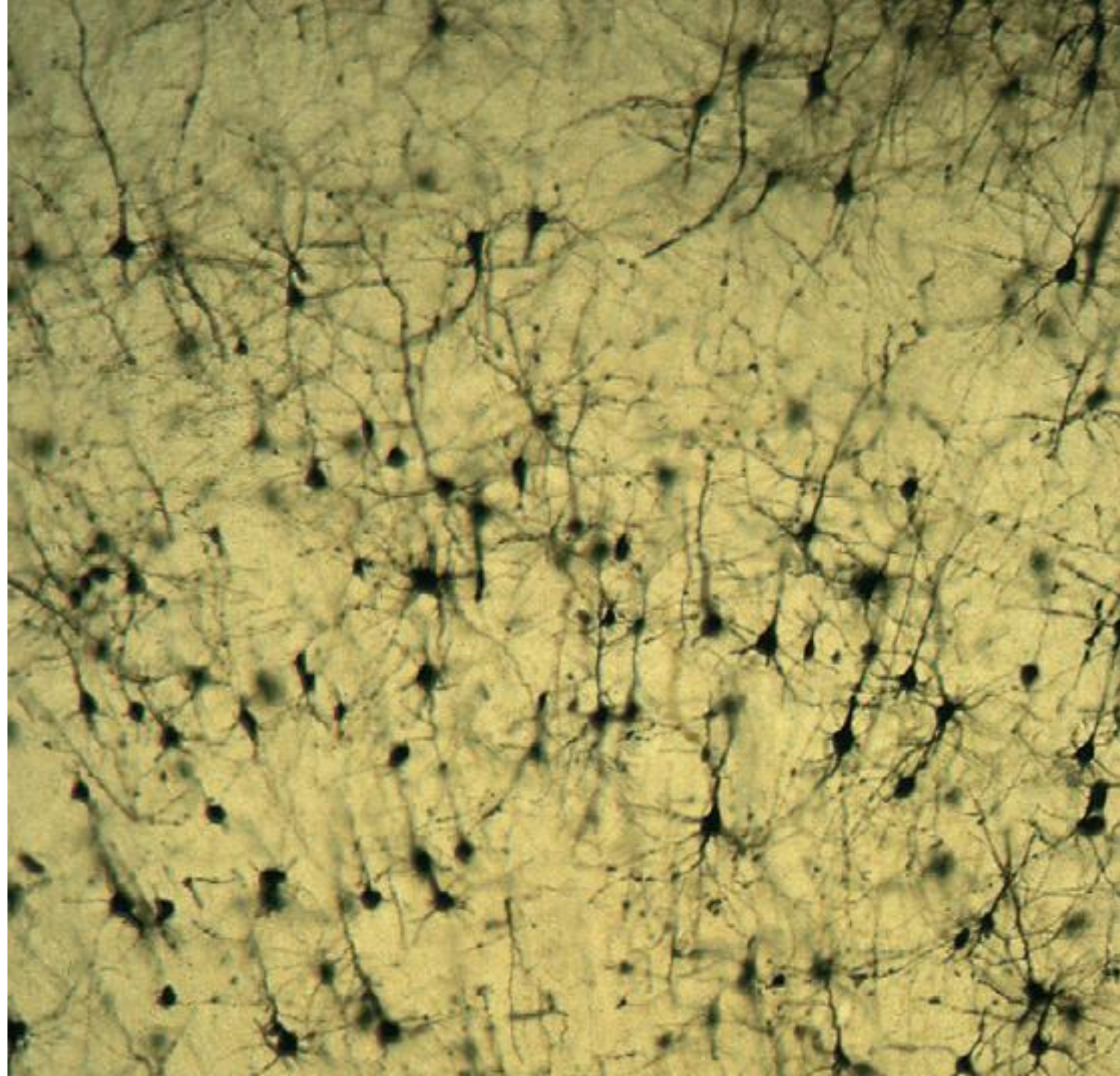


A *realistic chandelier neuron*

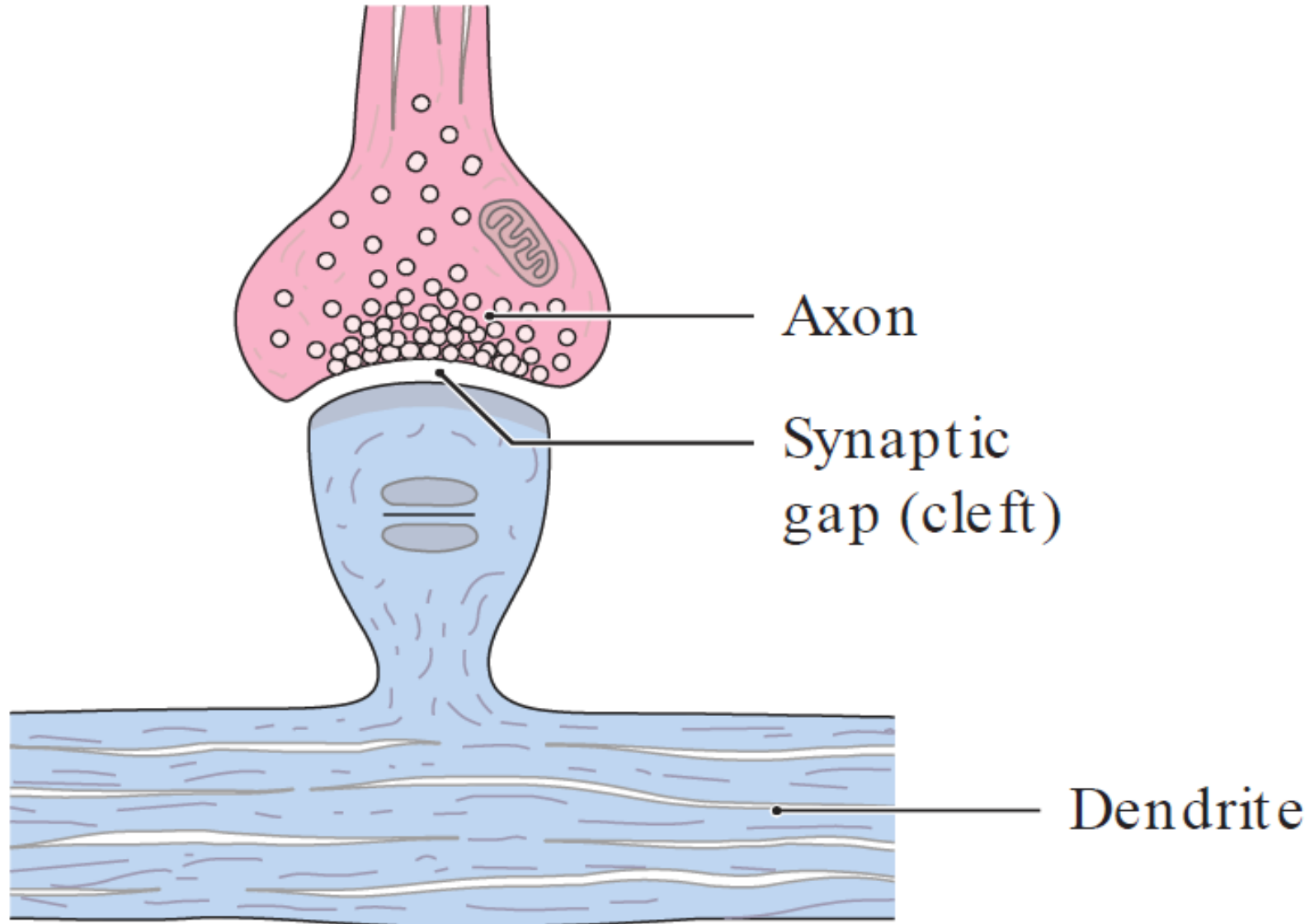


B *icon of chandelier neuron*

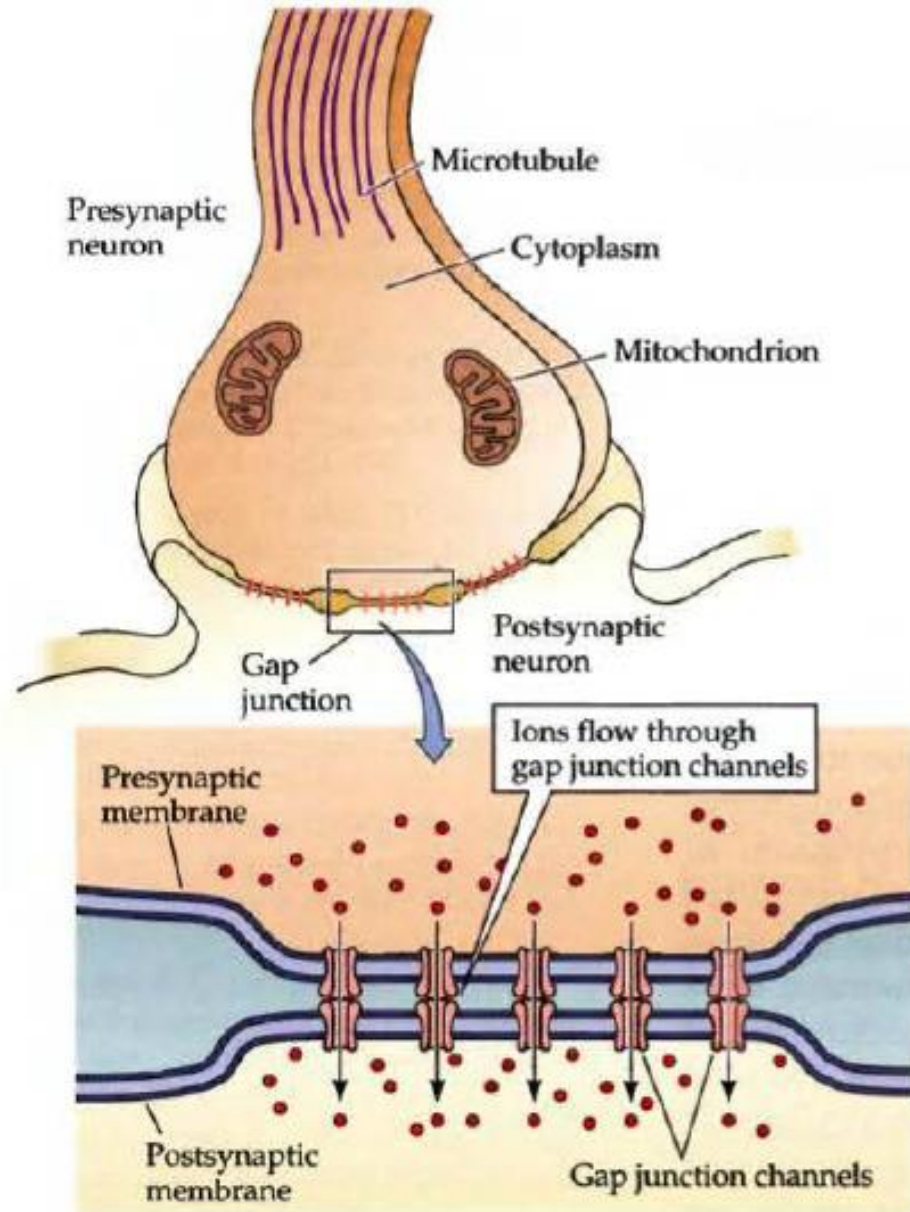




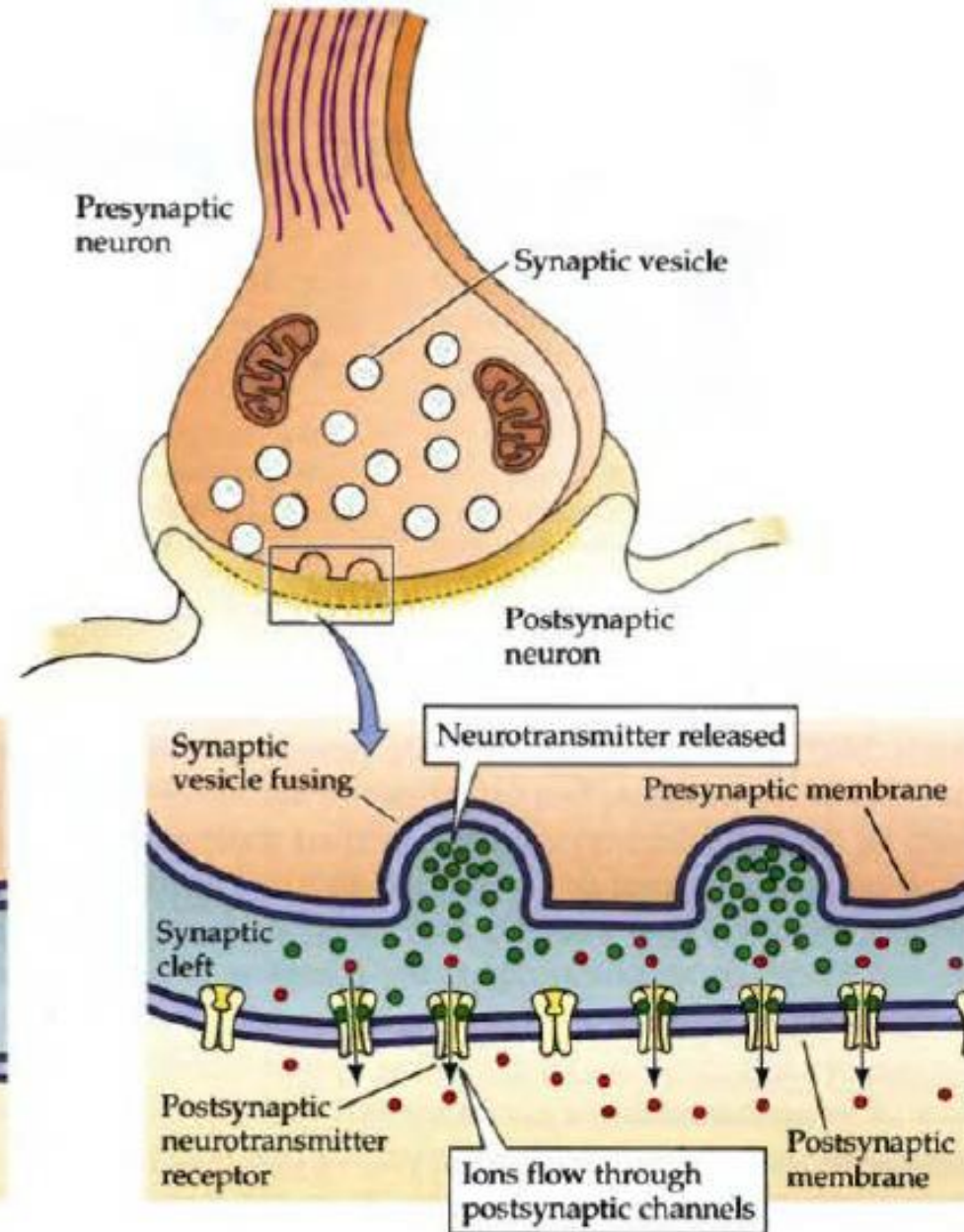
Sinpasis

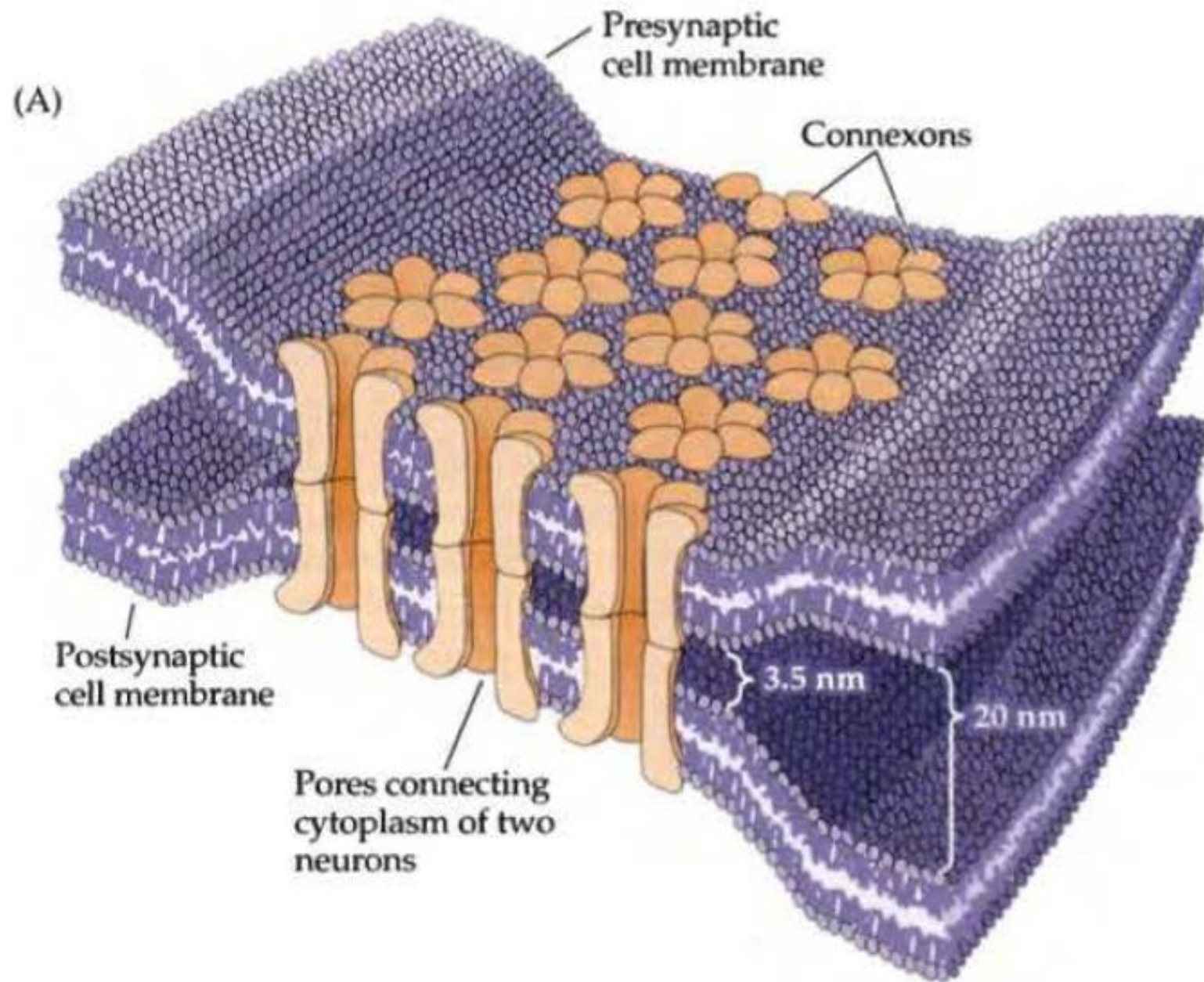


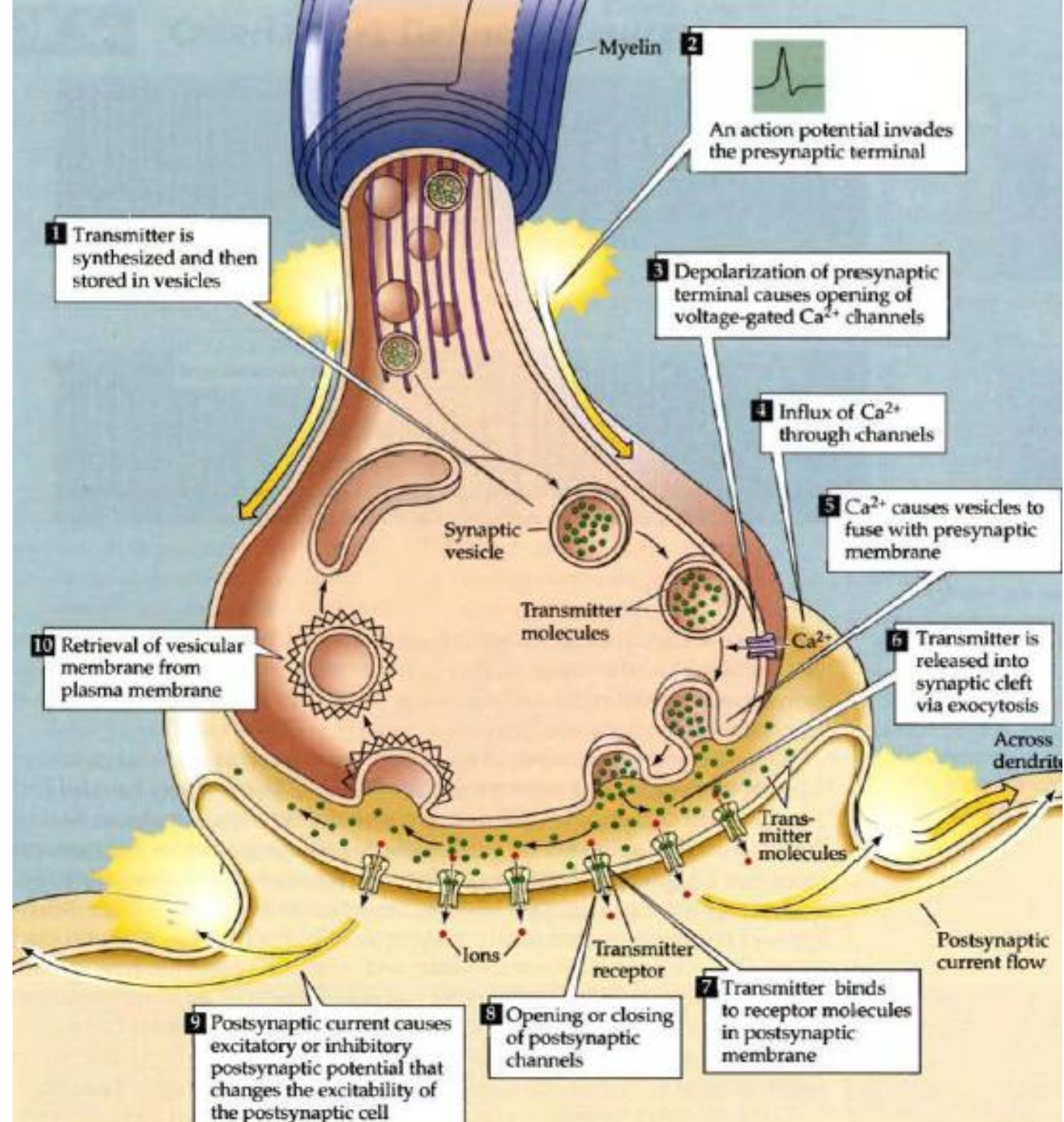
(A) ELECTRICAL SYNAPSE

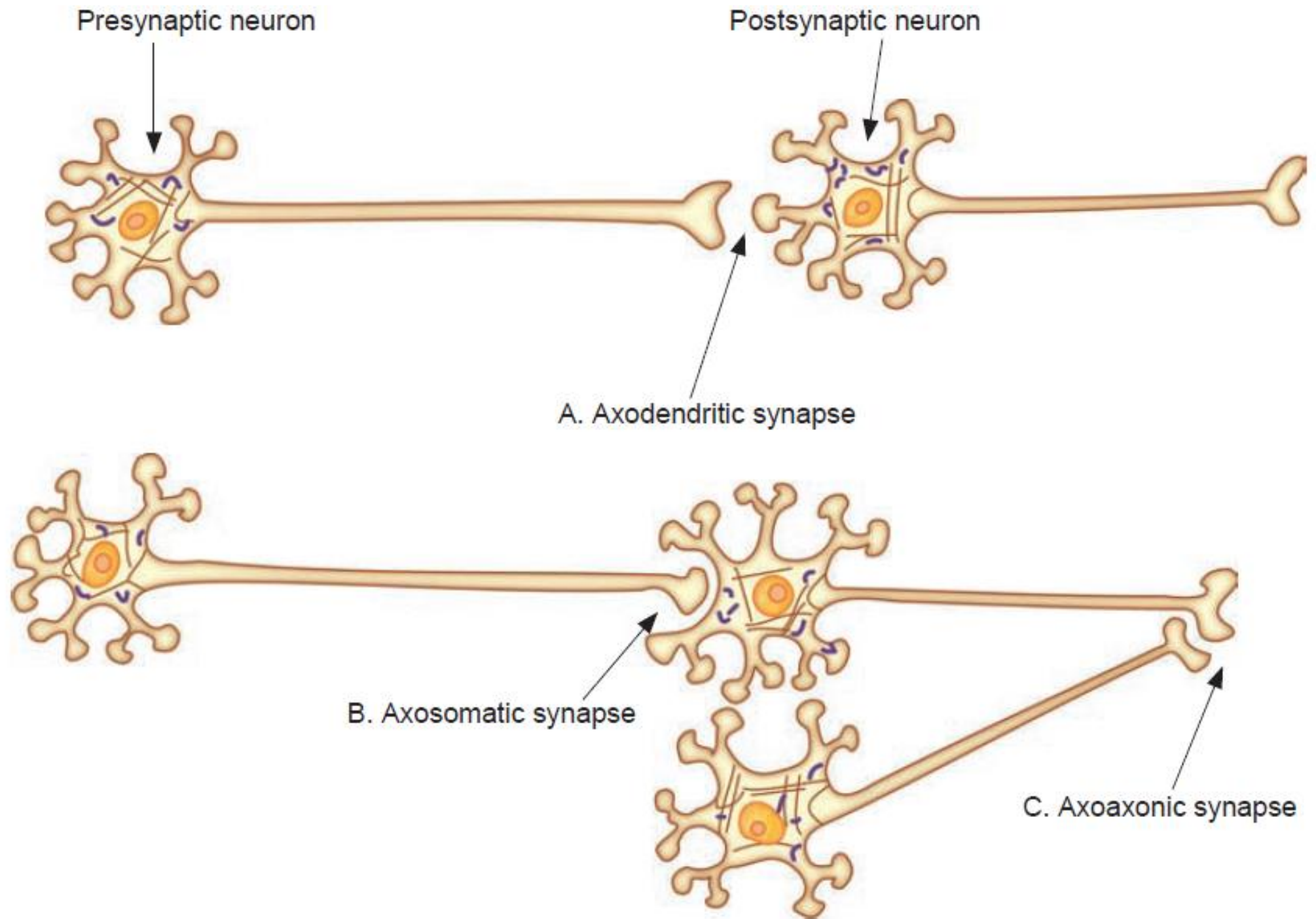


(B) CHEMICAL SYNAPSE









Presynaptic neuron

Postsynaptic neuron

A. Axodendritic synapse

B. Axosomatic synapse

C. Axoaxonic synapse

