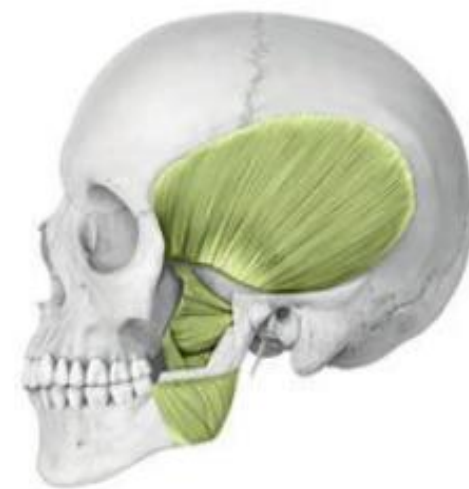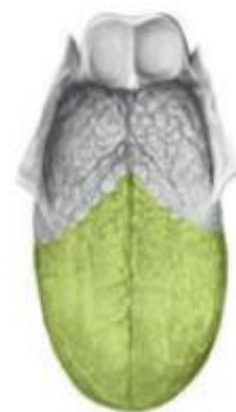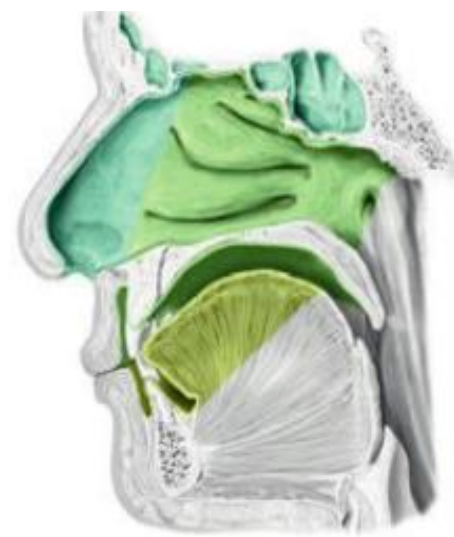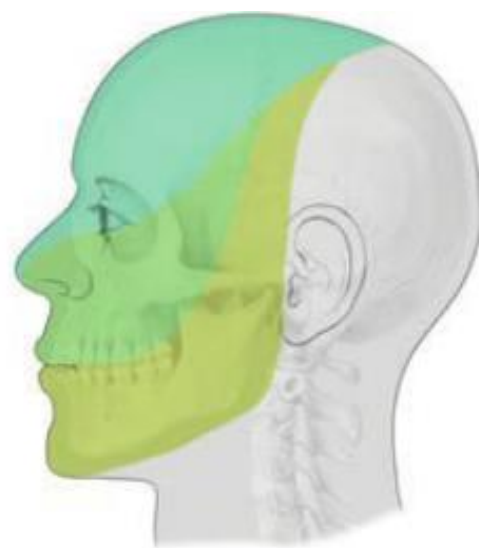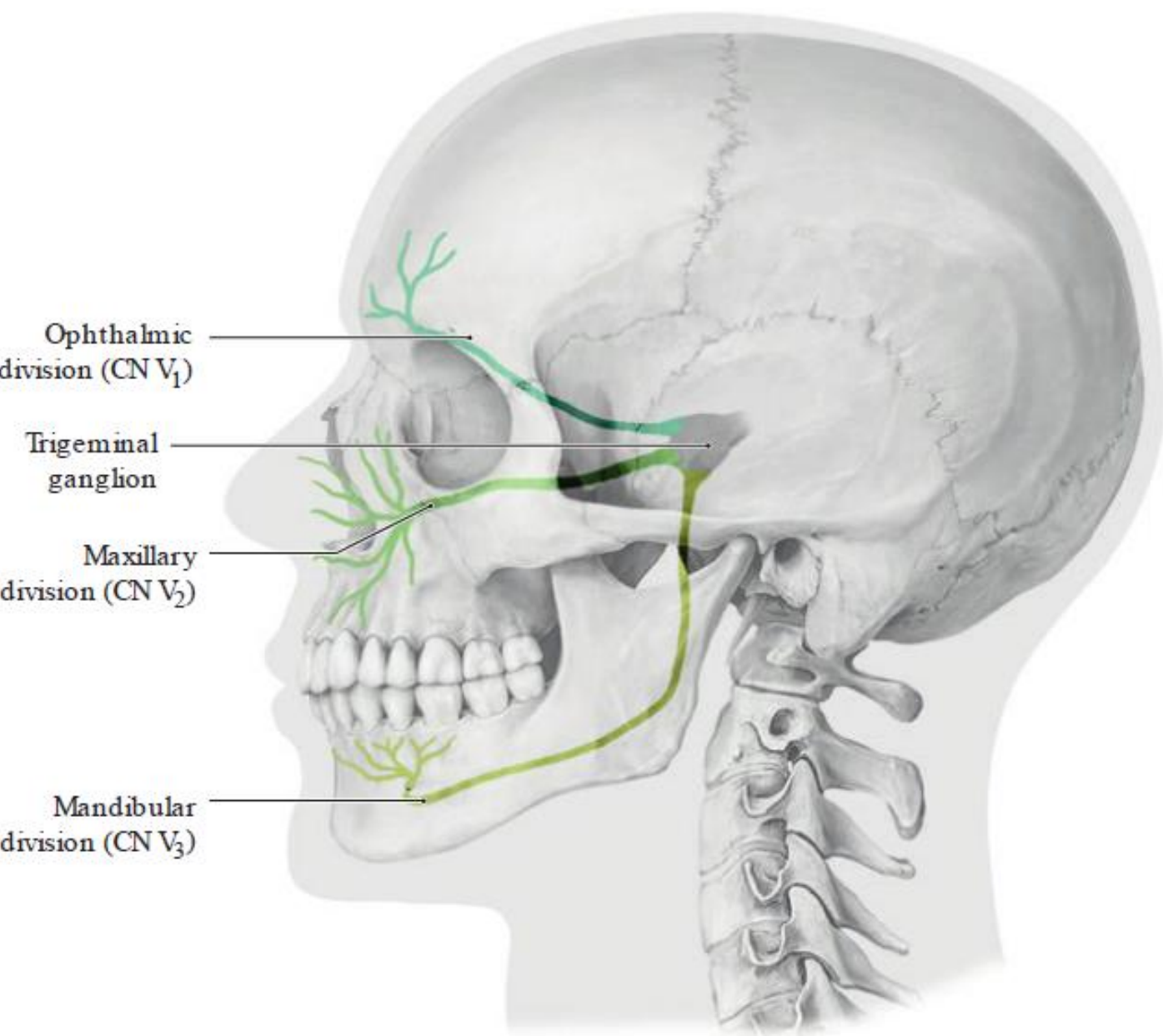
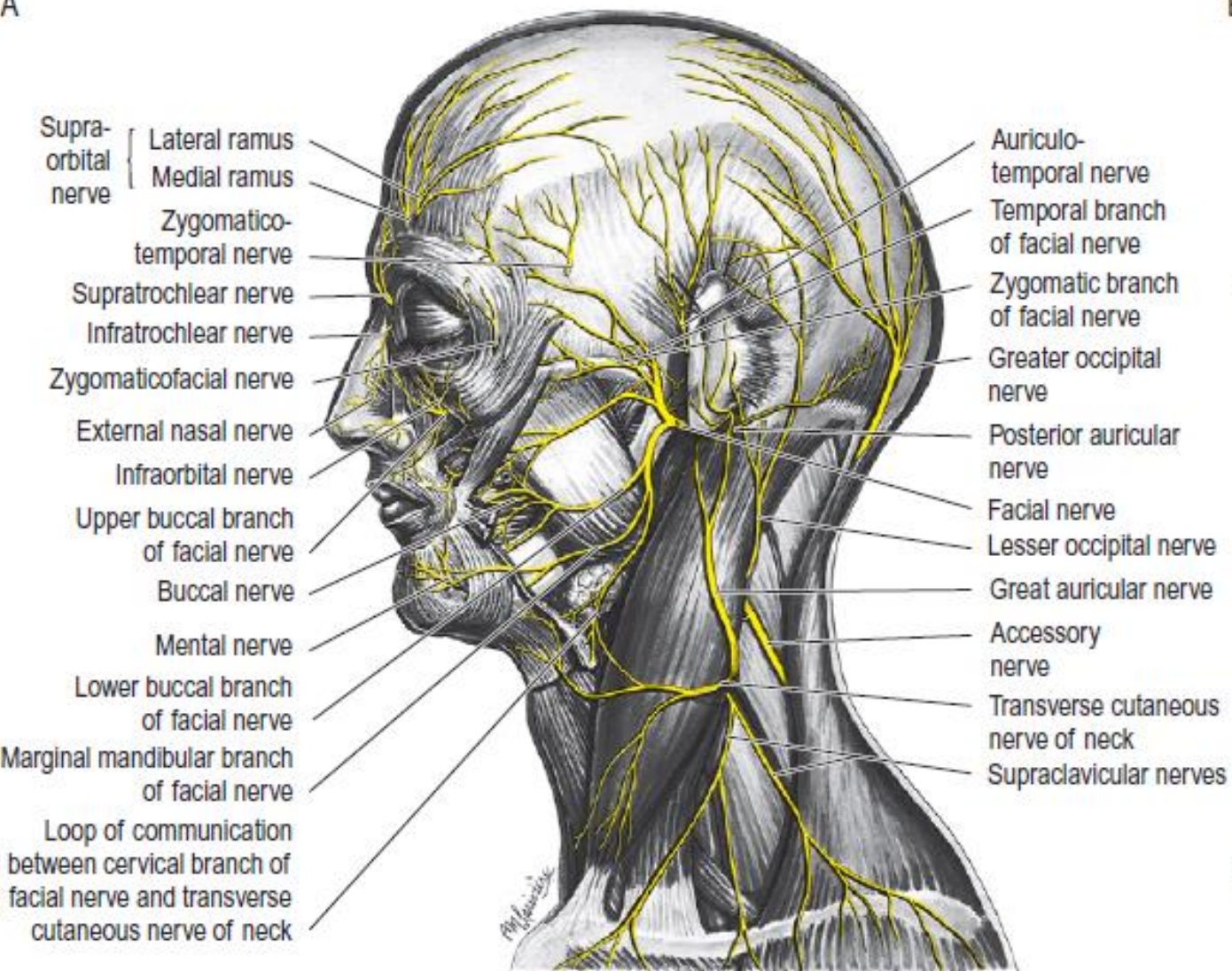


Pares Craneales

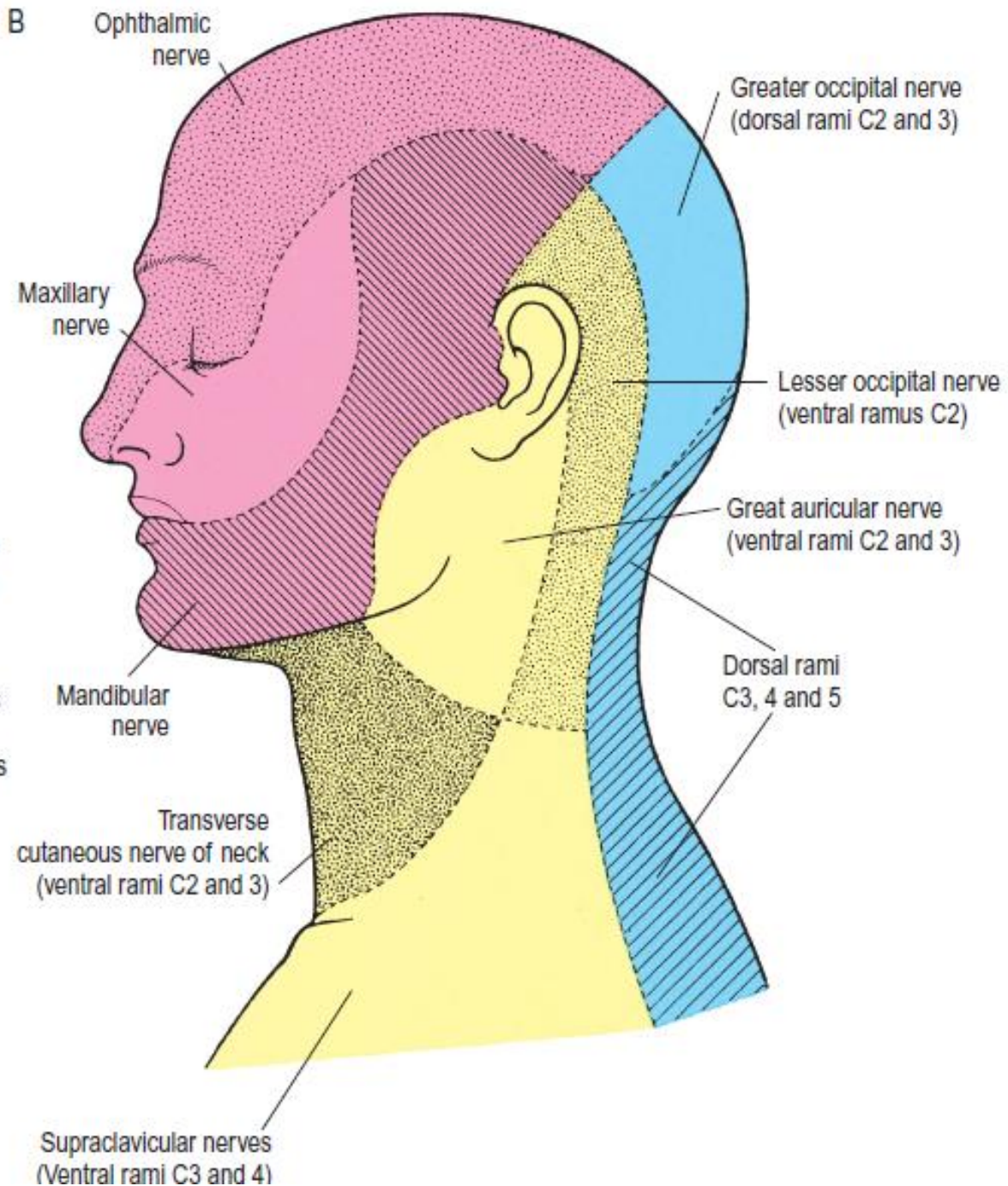
Nelson D. Villalba M.D. M.Sc.

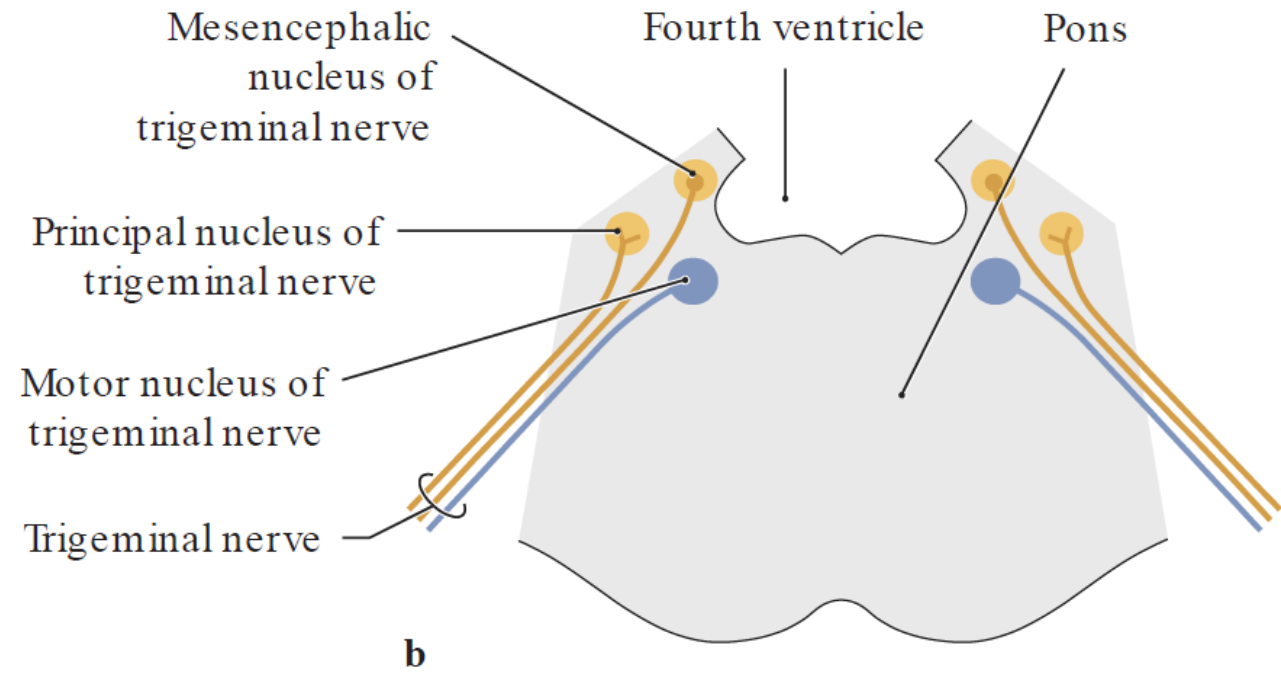
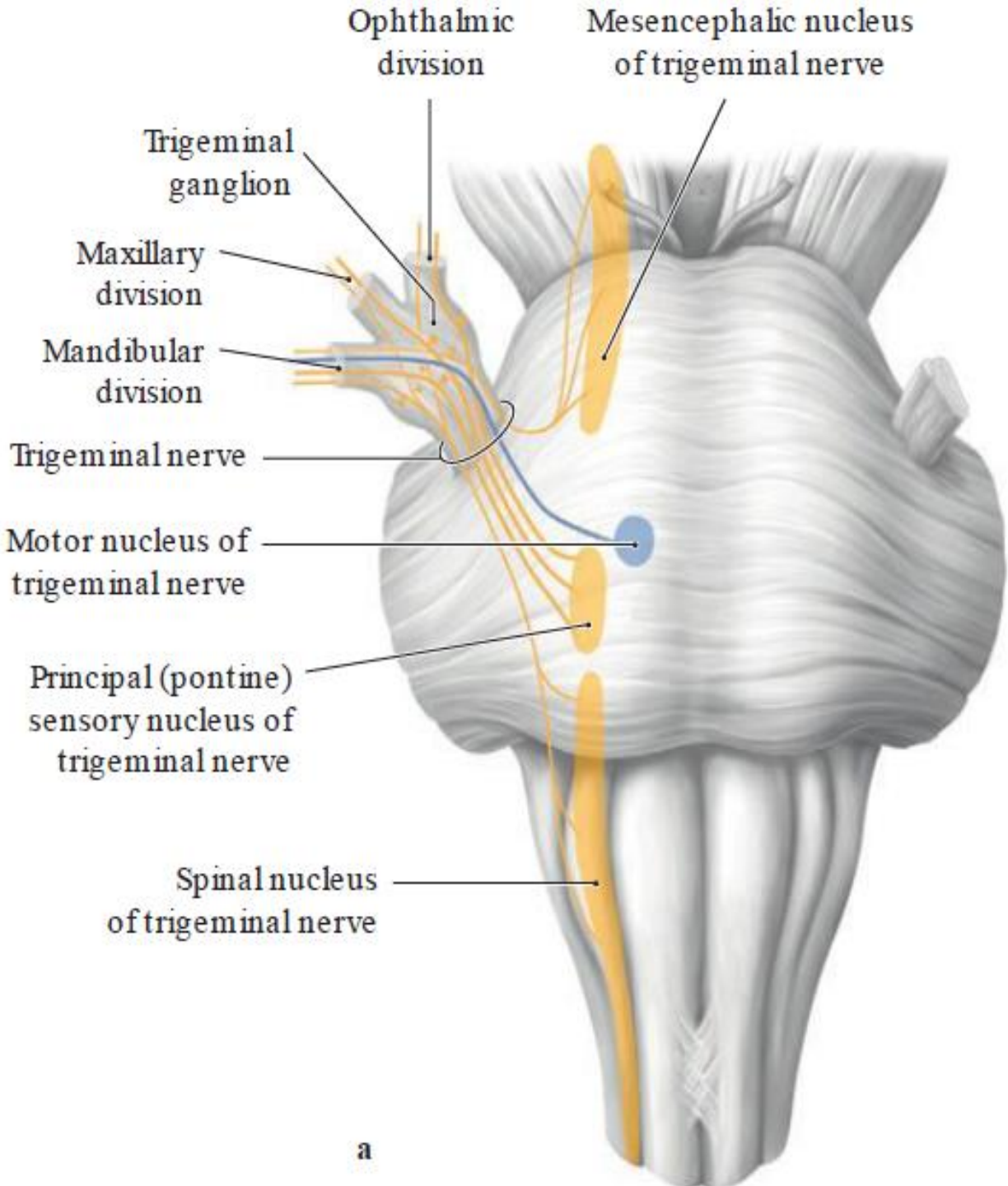


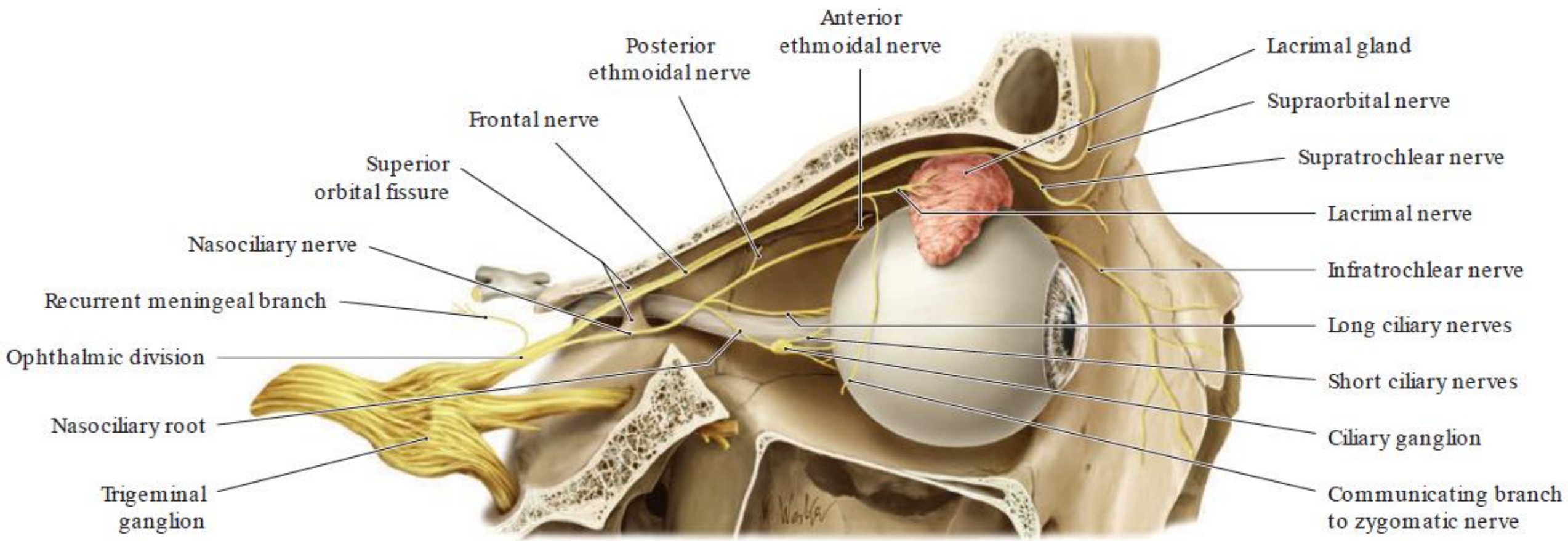
A

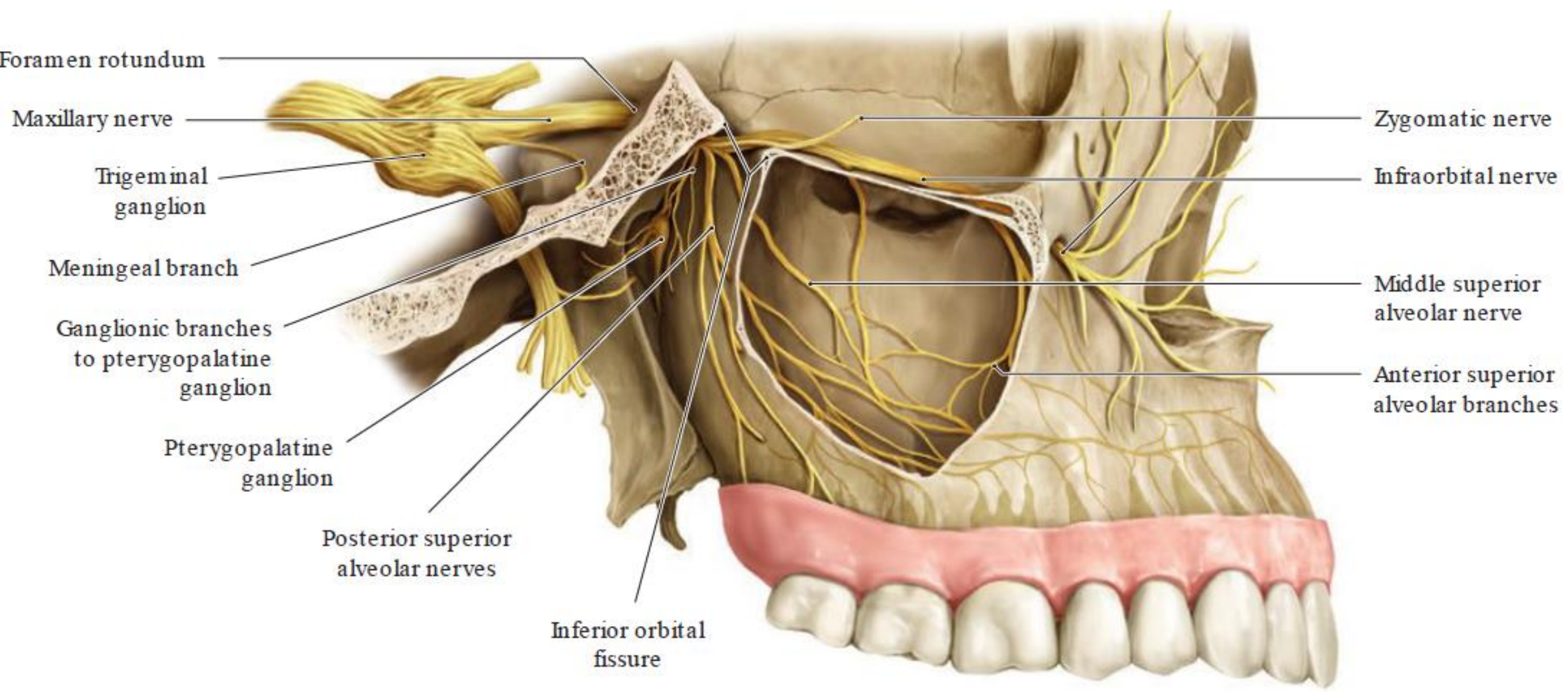


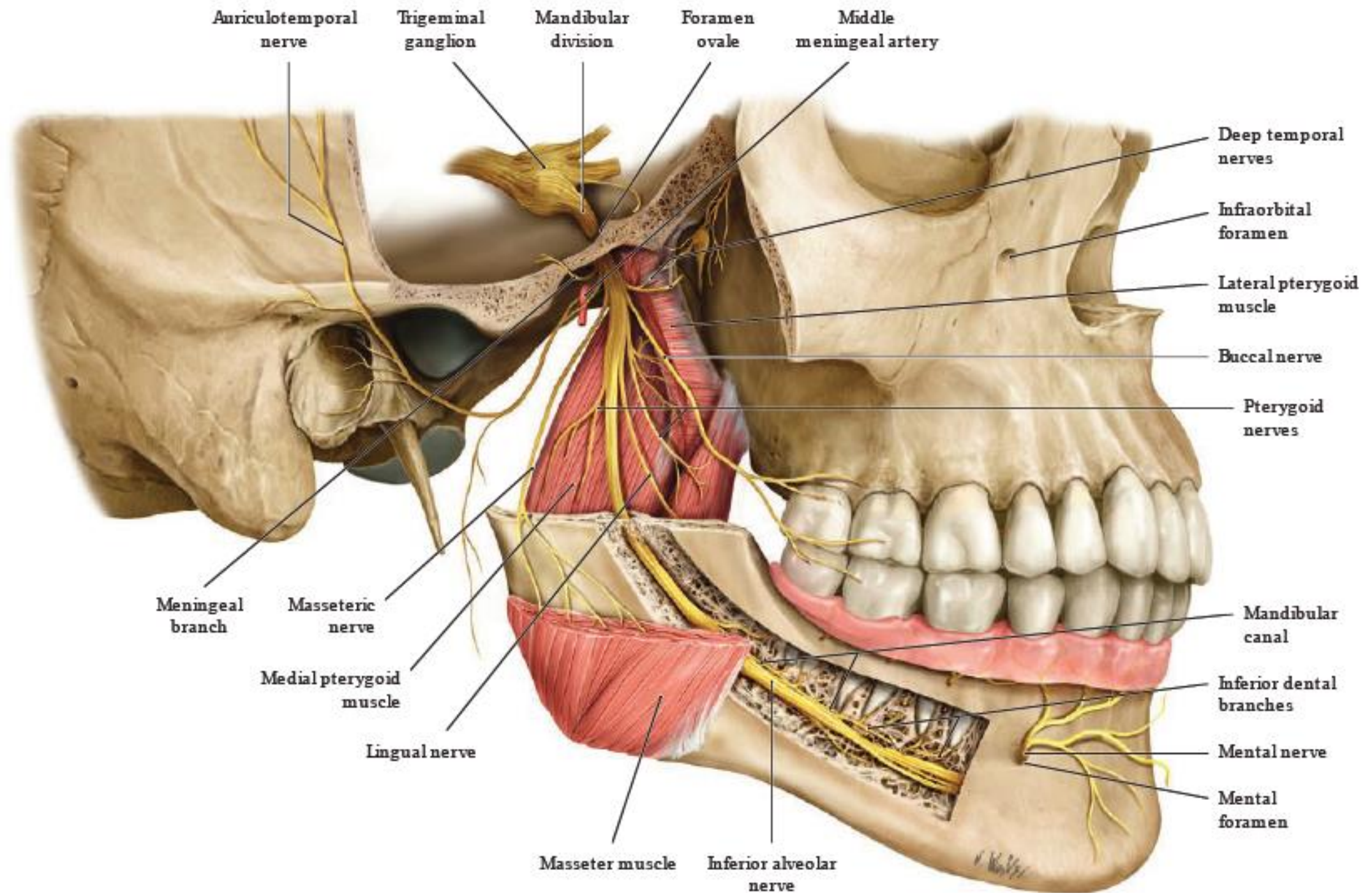
B

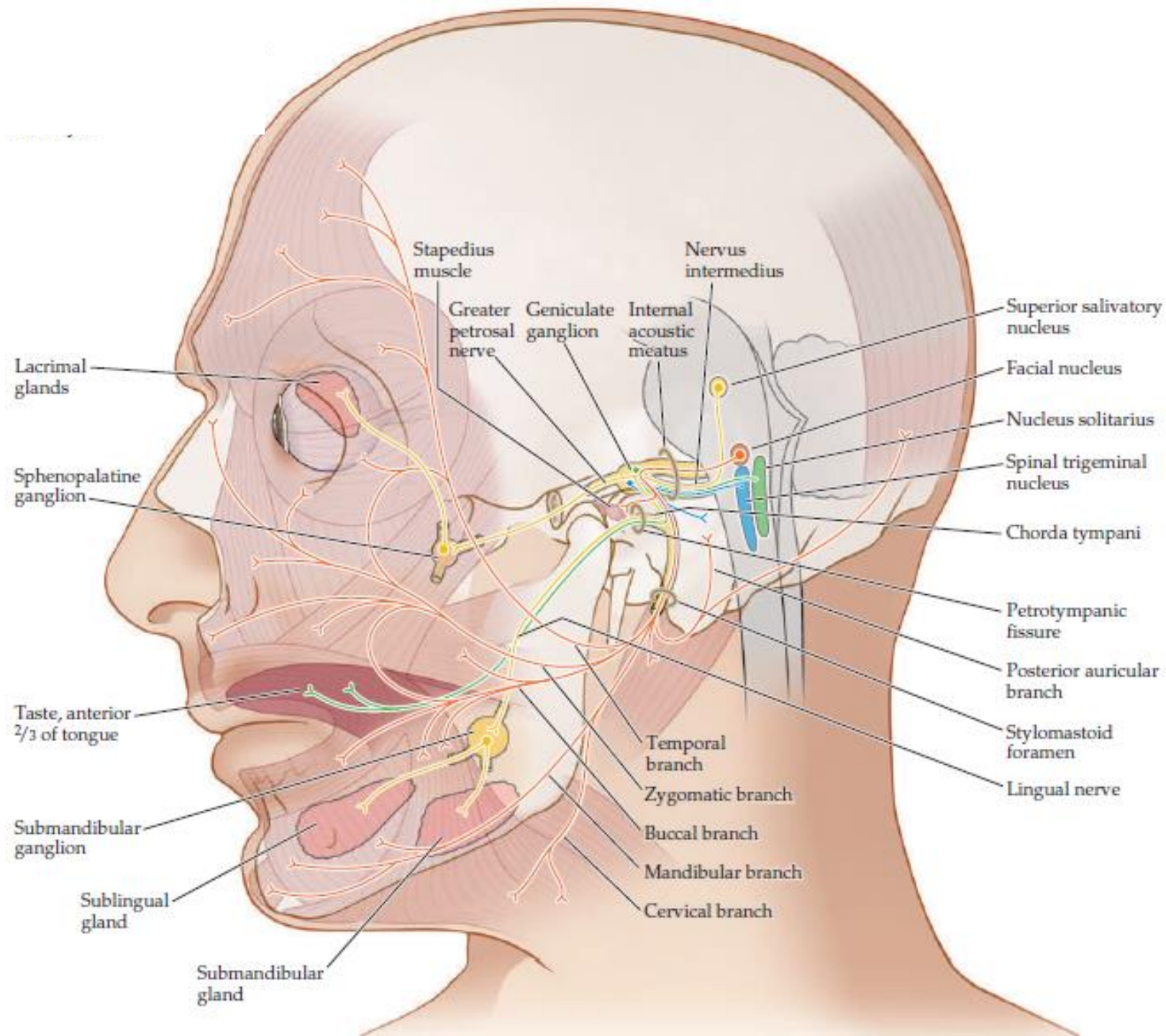


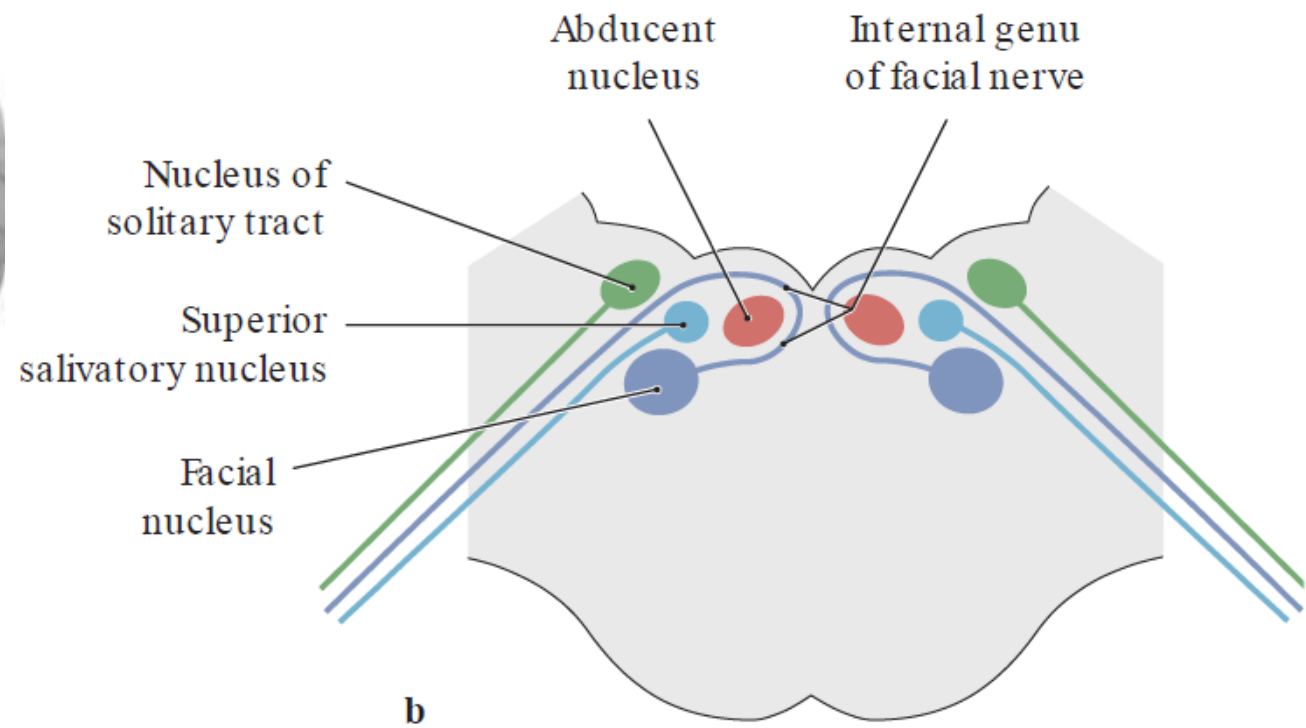
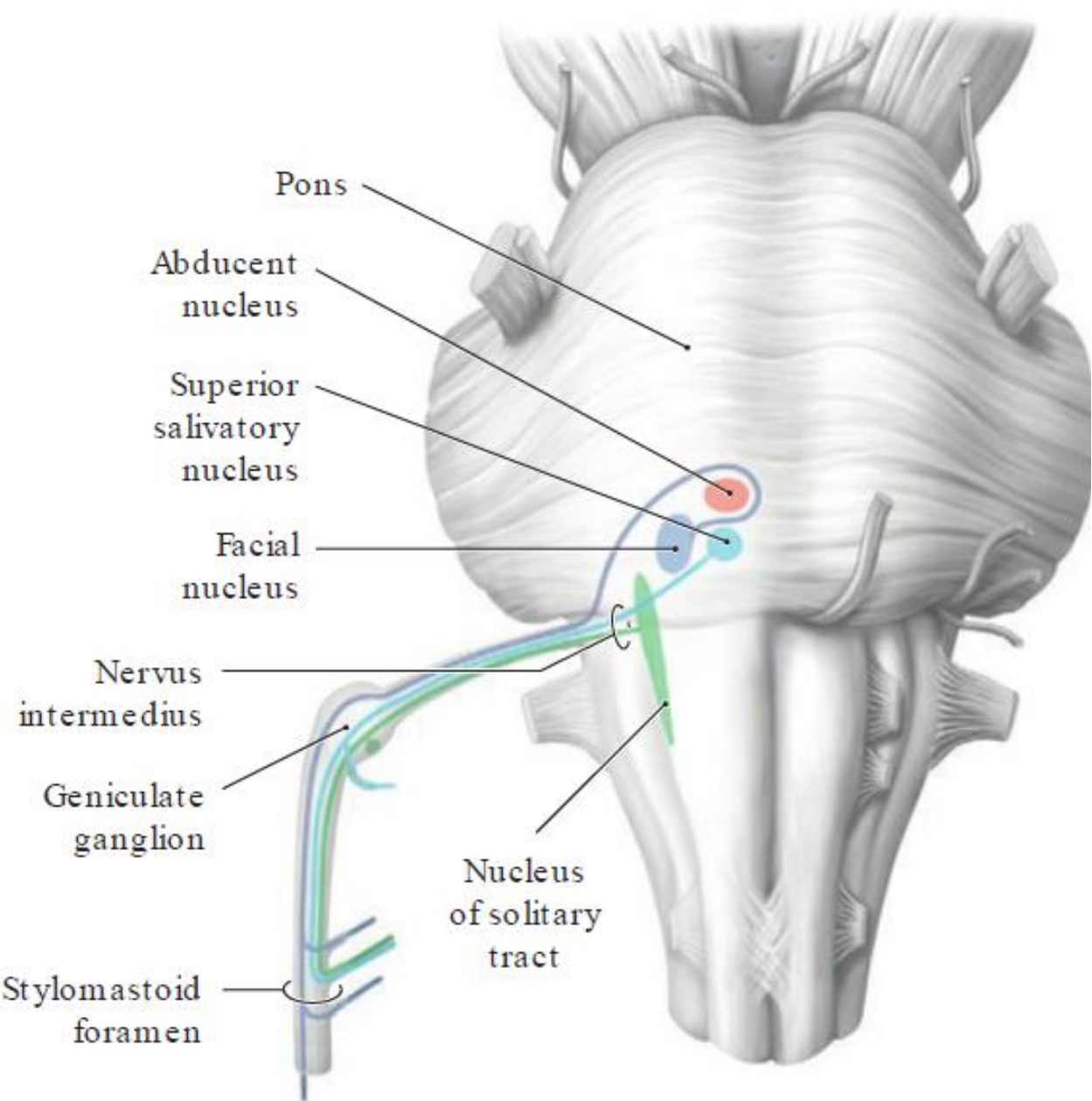


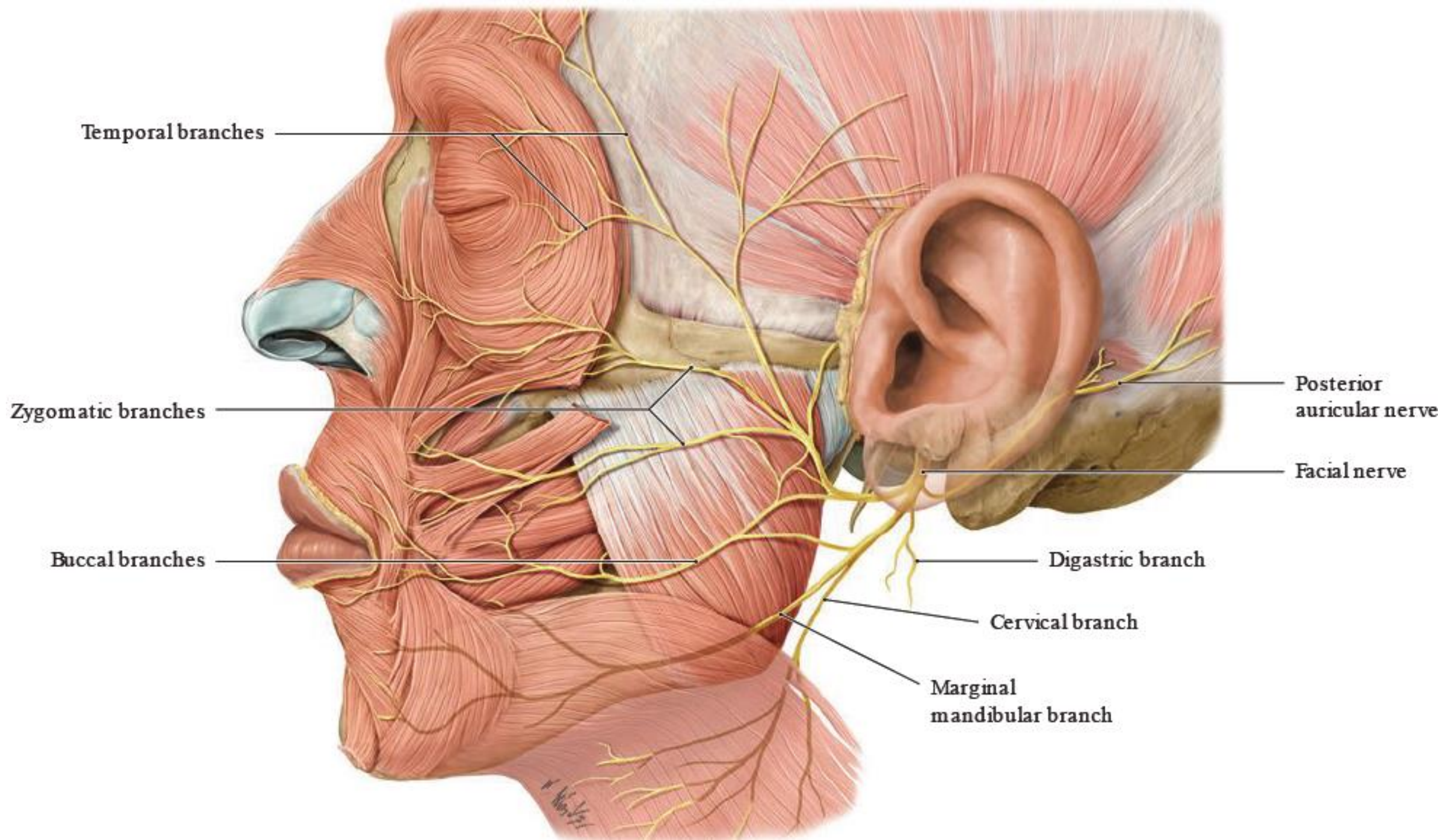


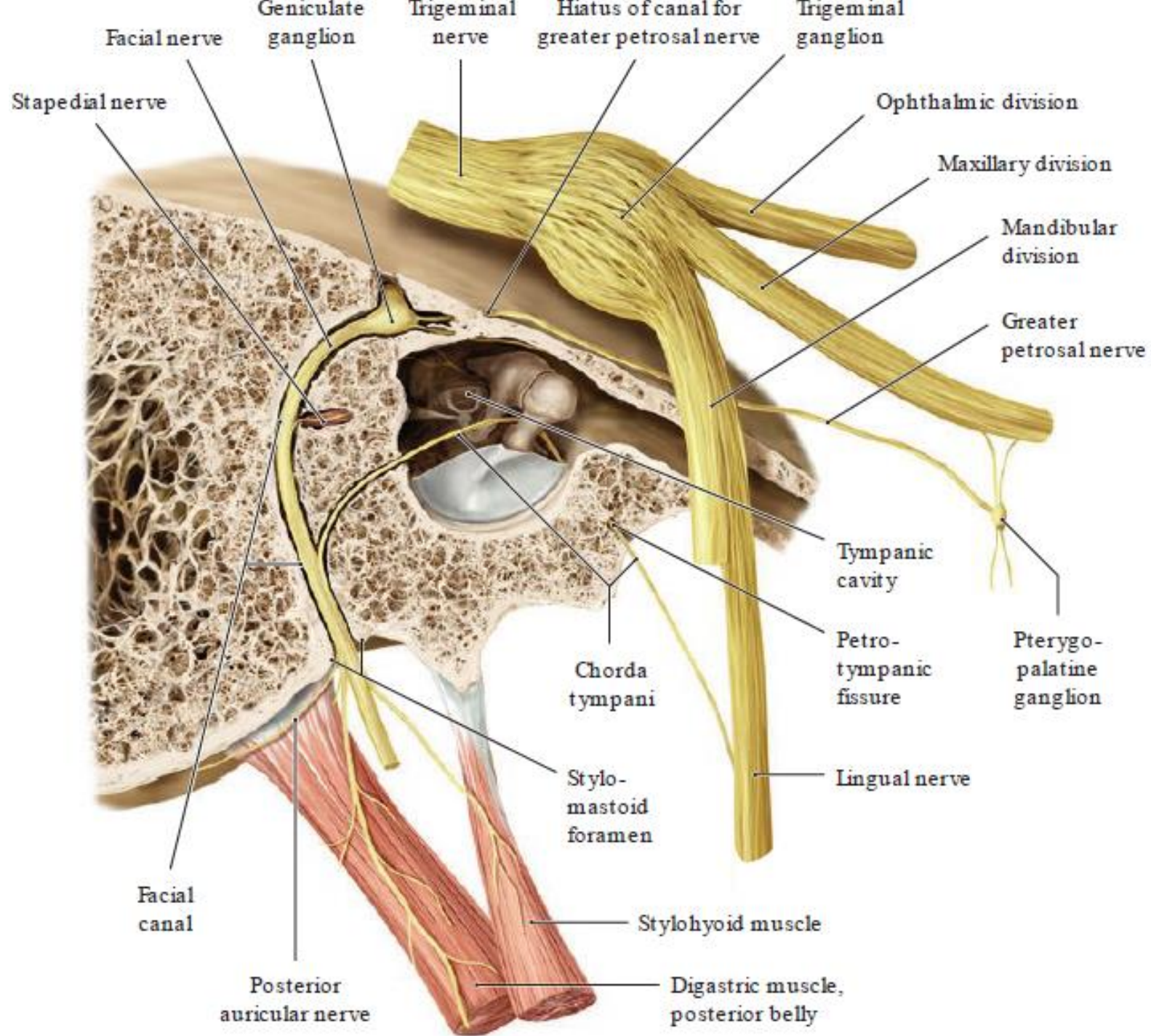


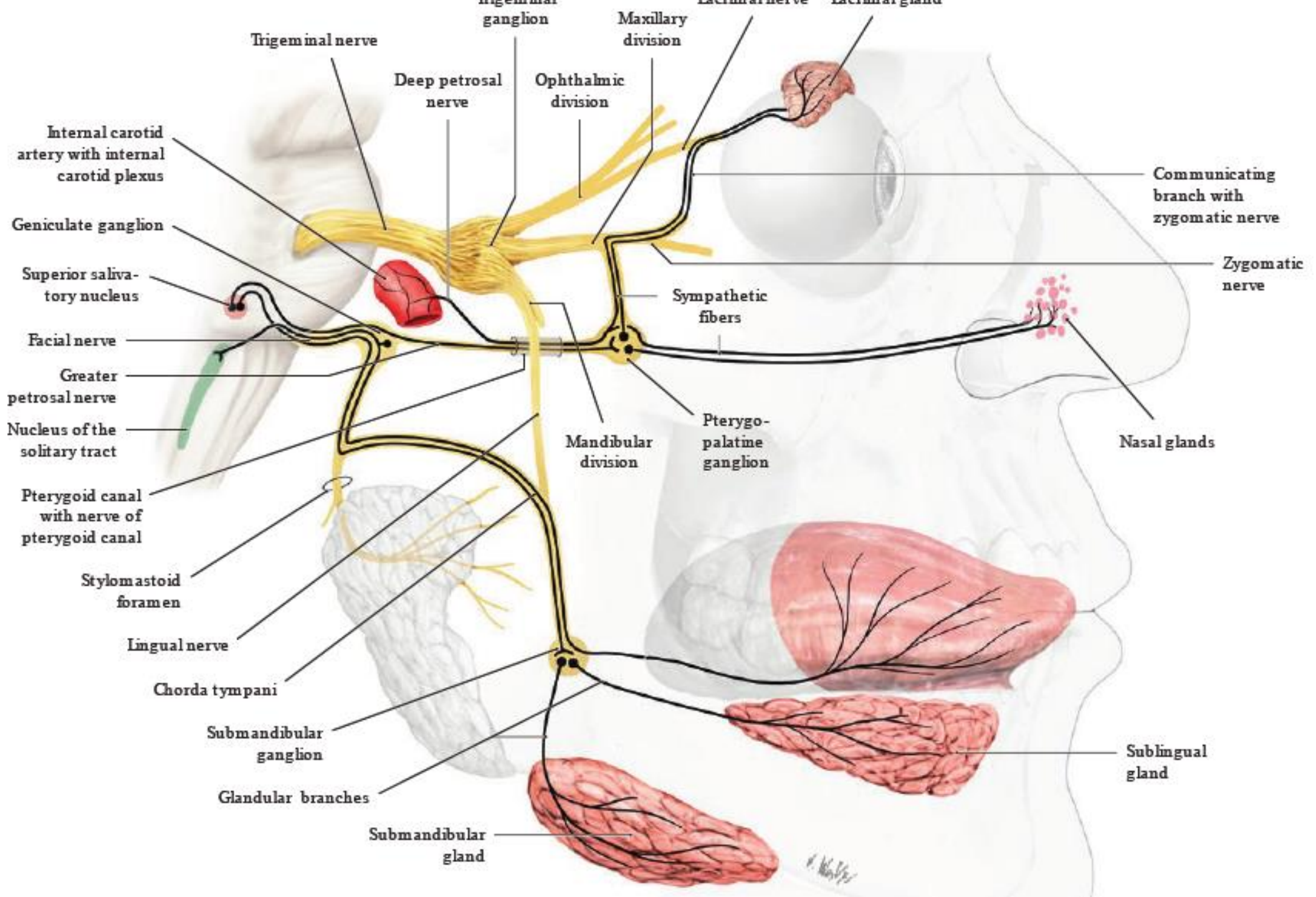


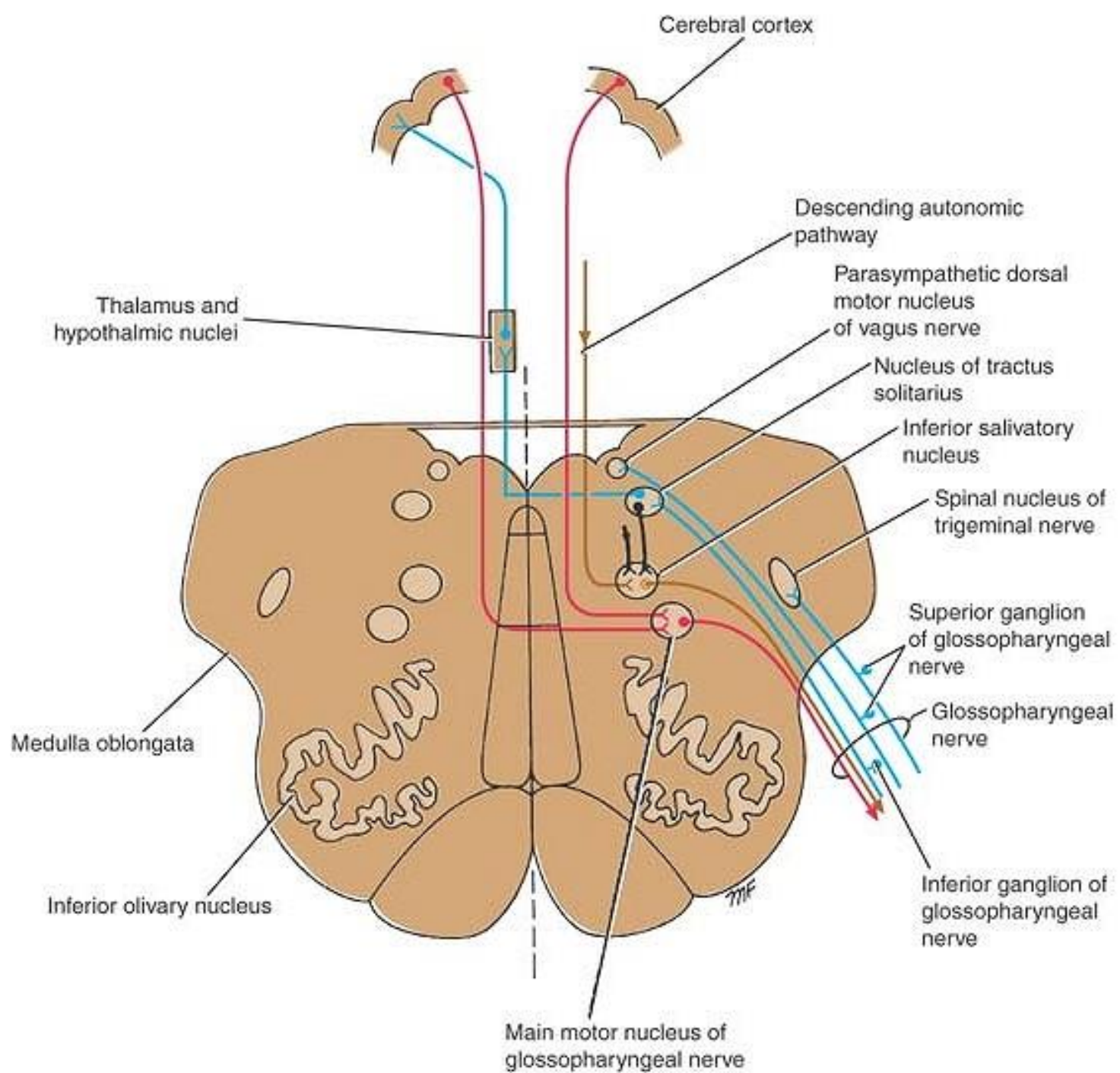


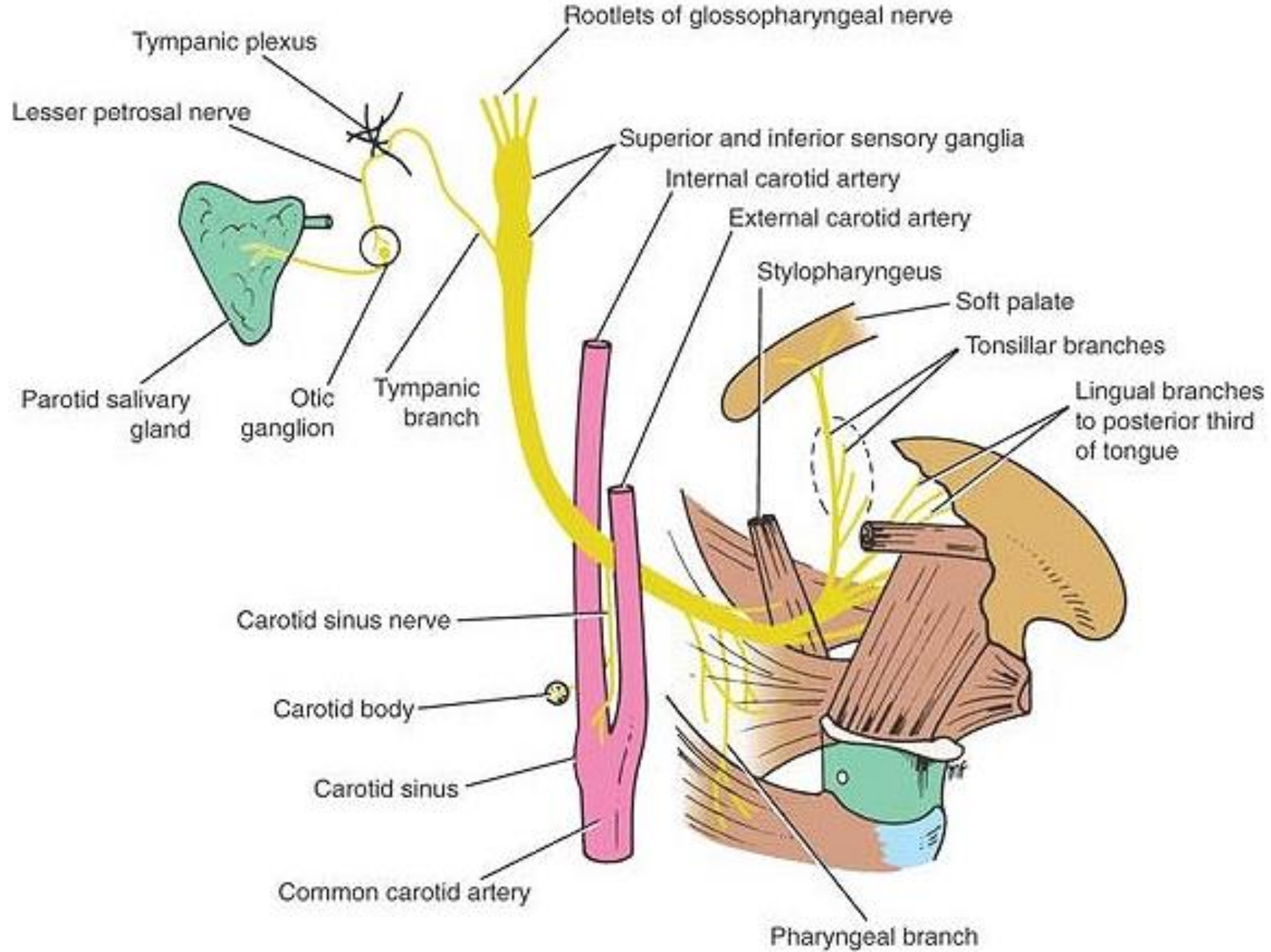


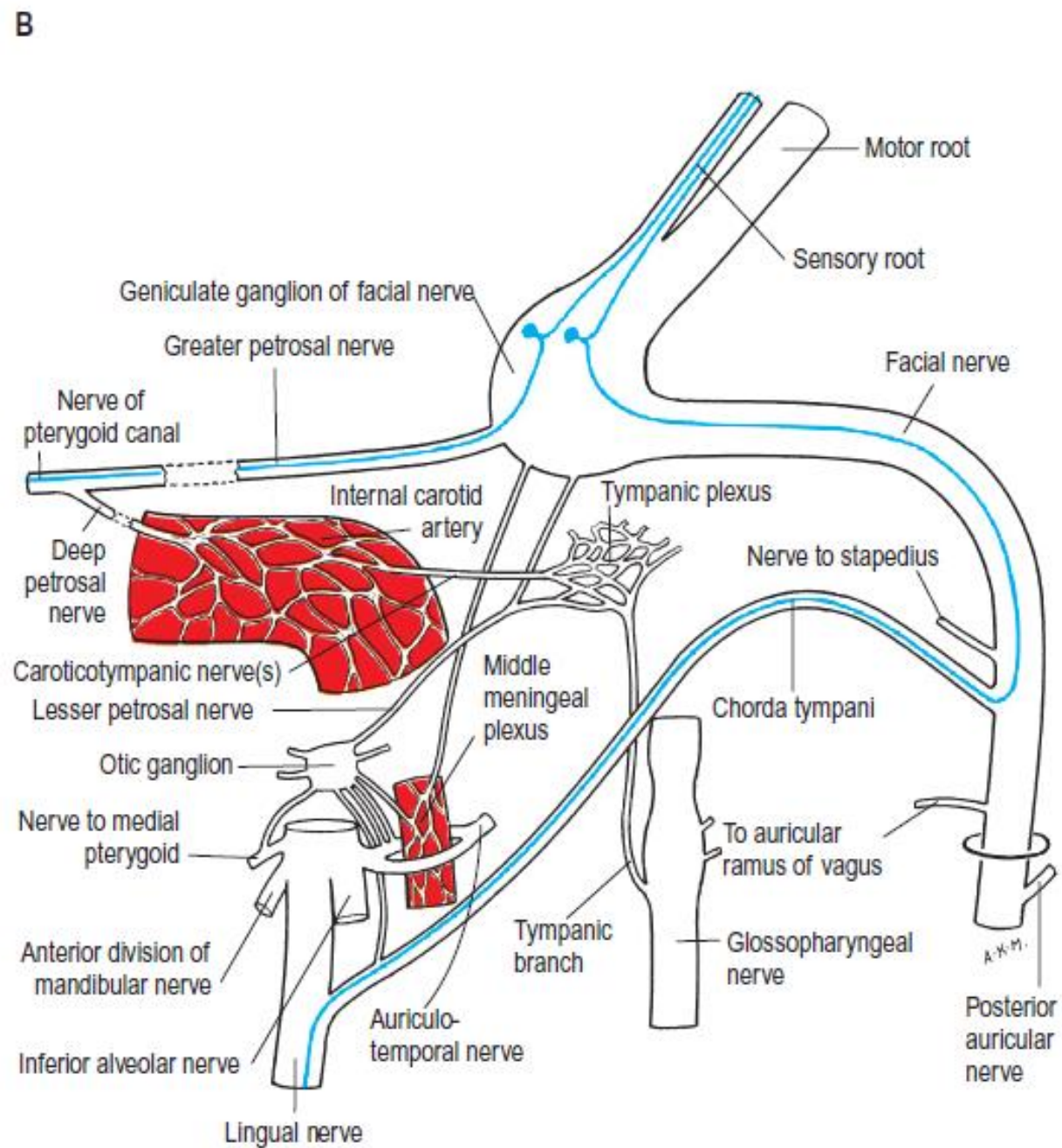
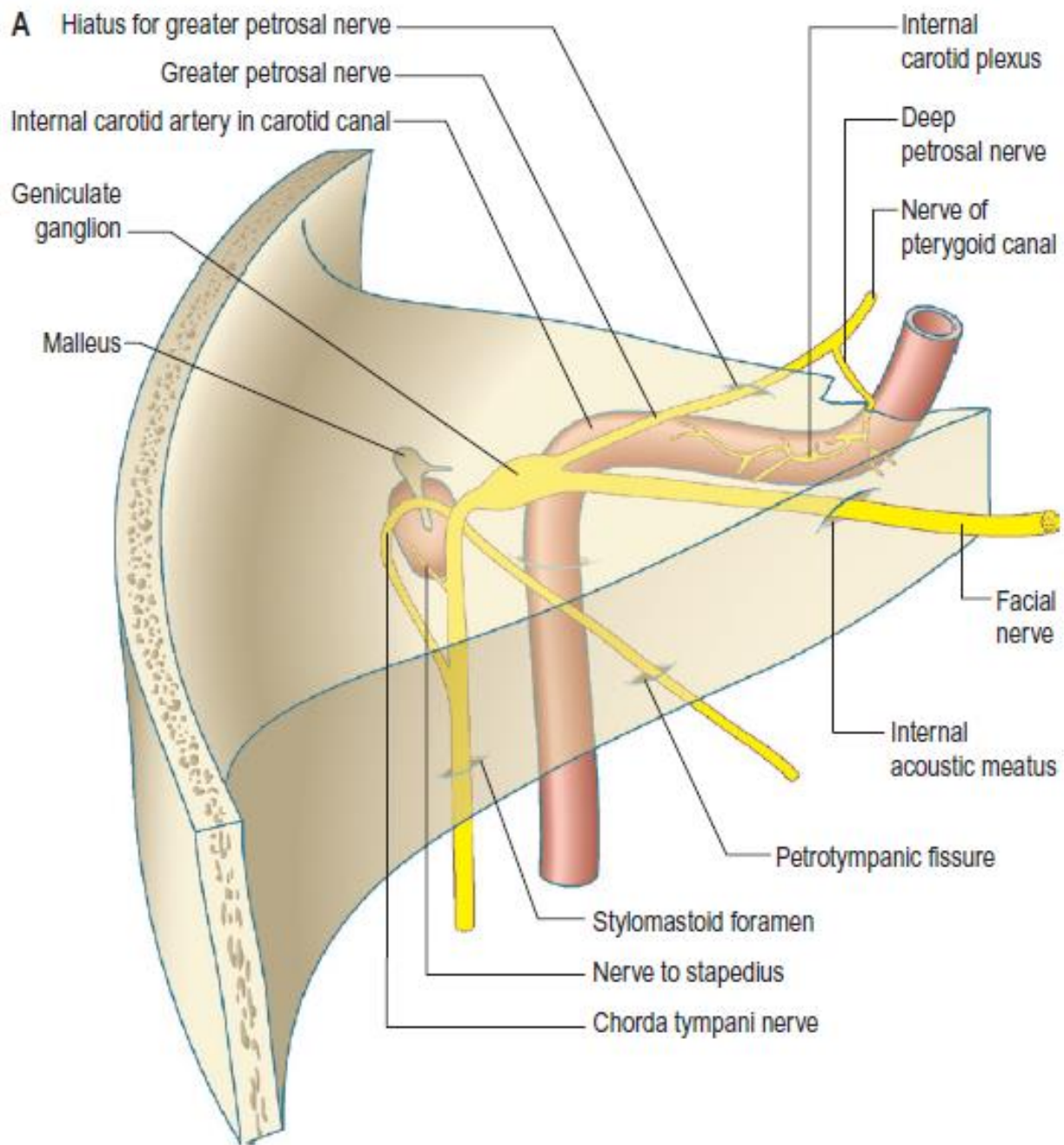


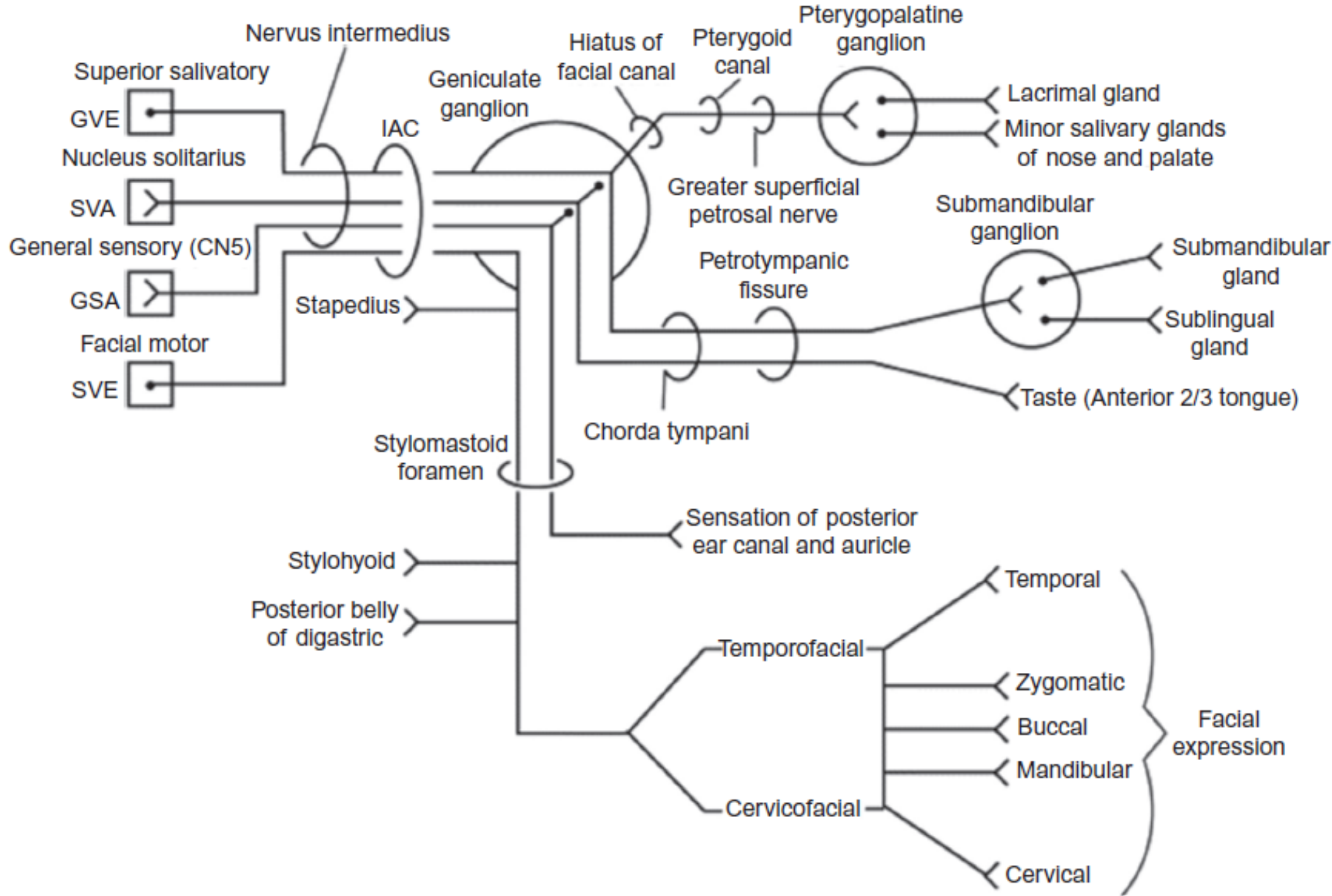












**A. Facial nerve lesion
(Bell's palsy)**

B. Supranuclear lesion

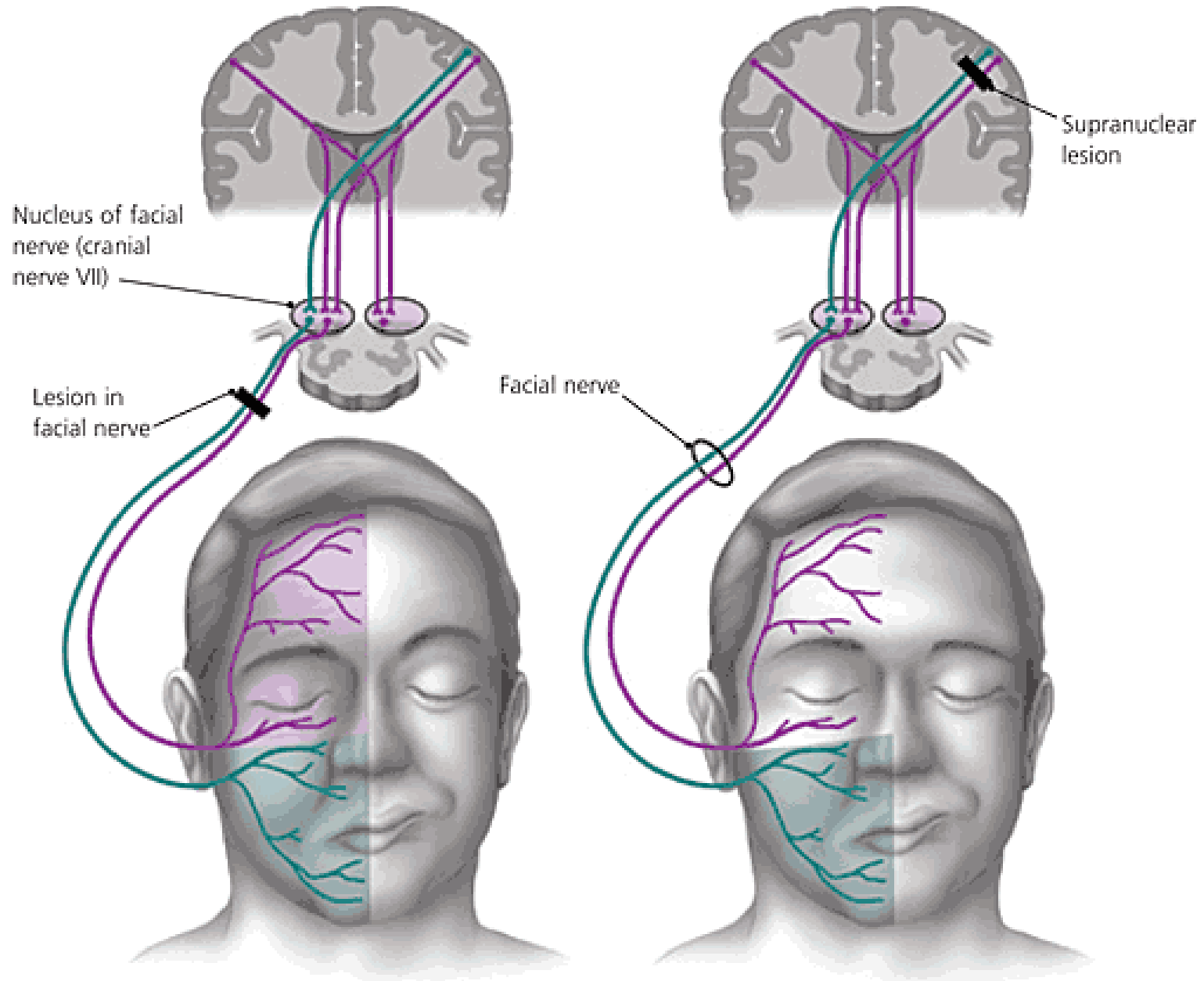
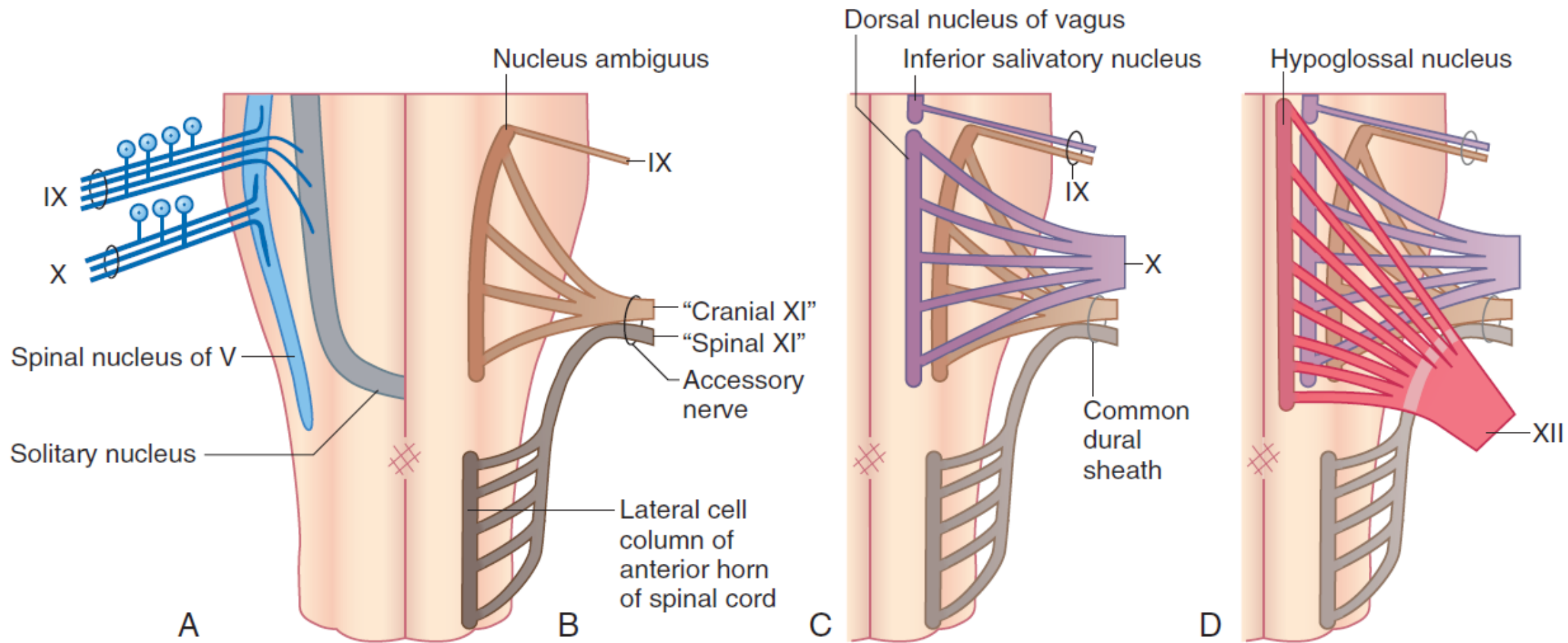
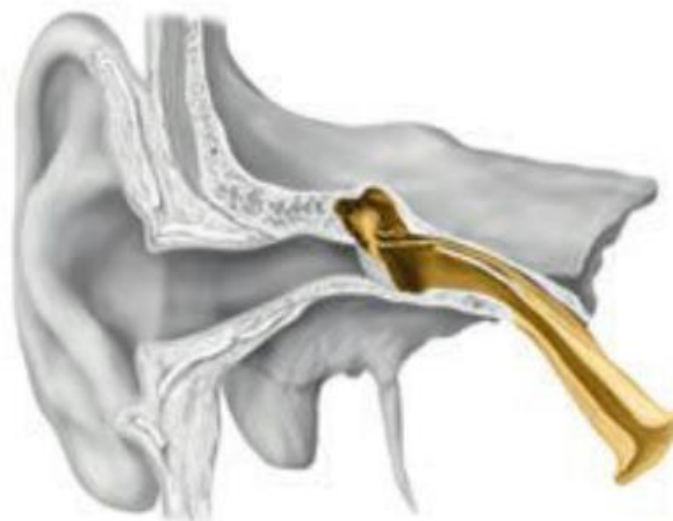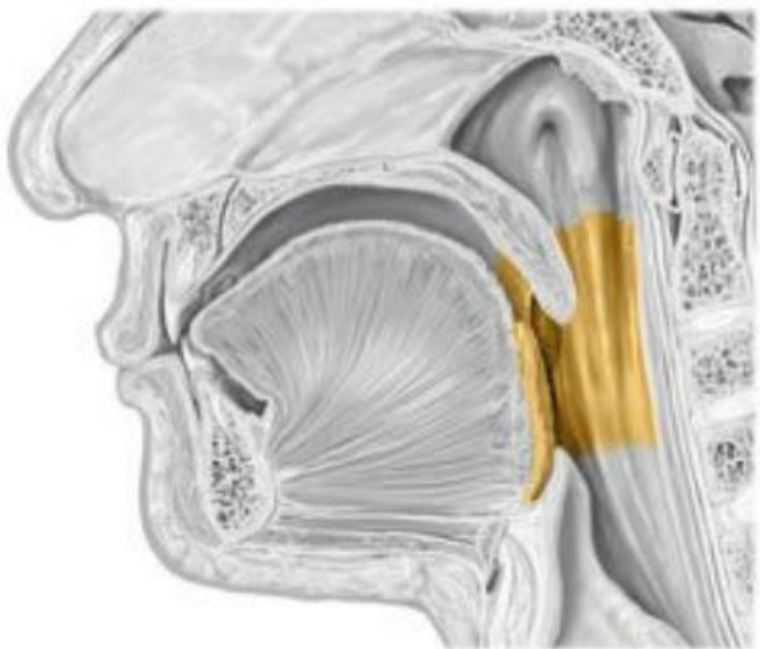
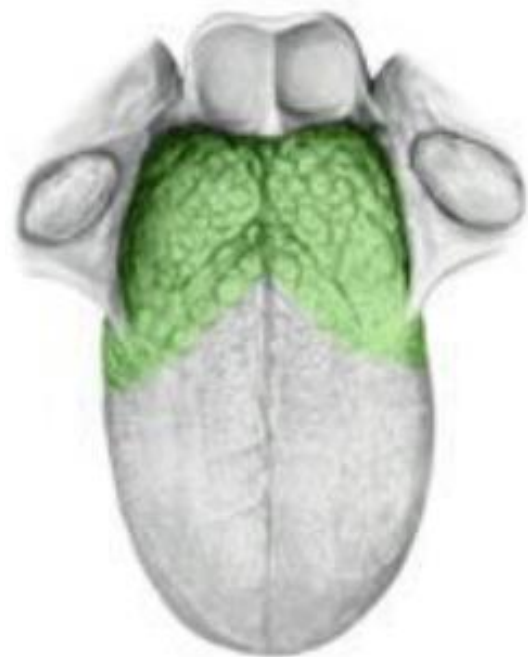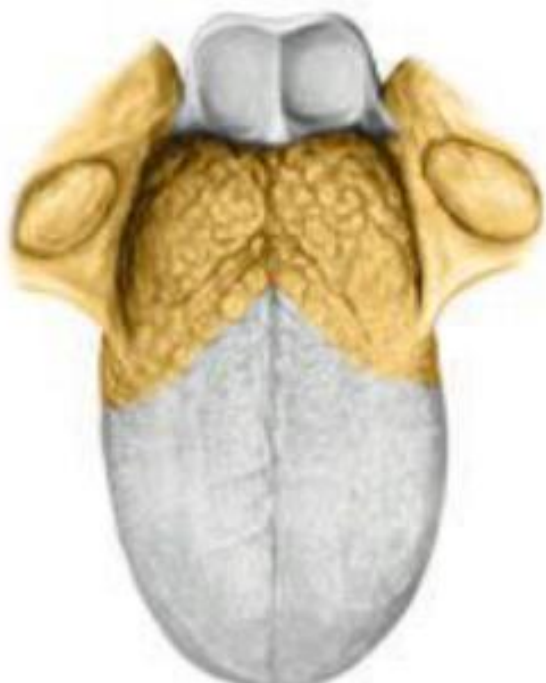
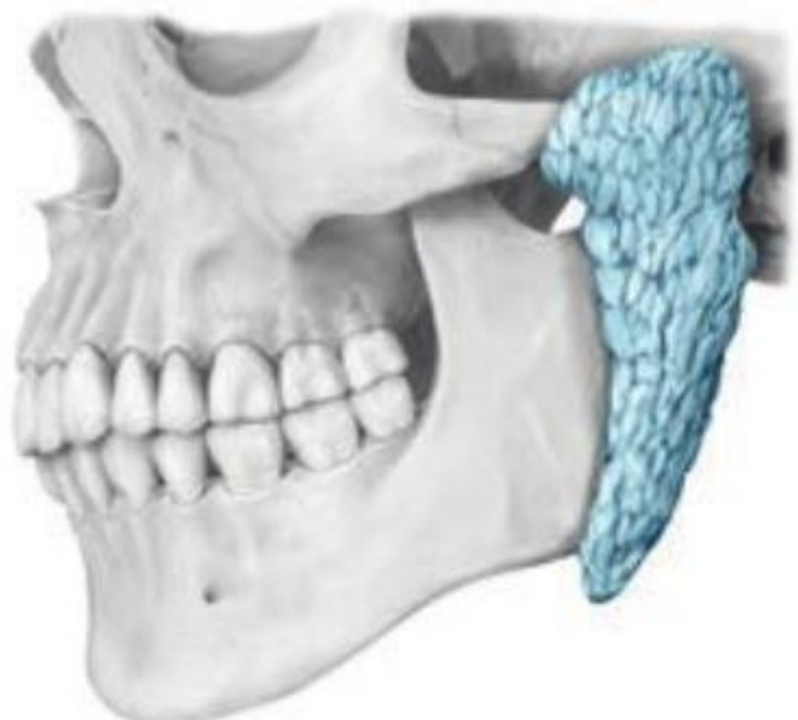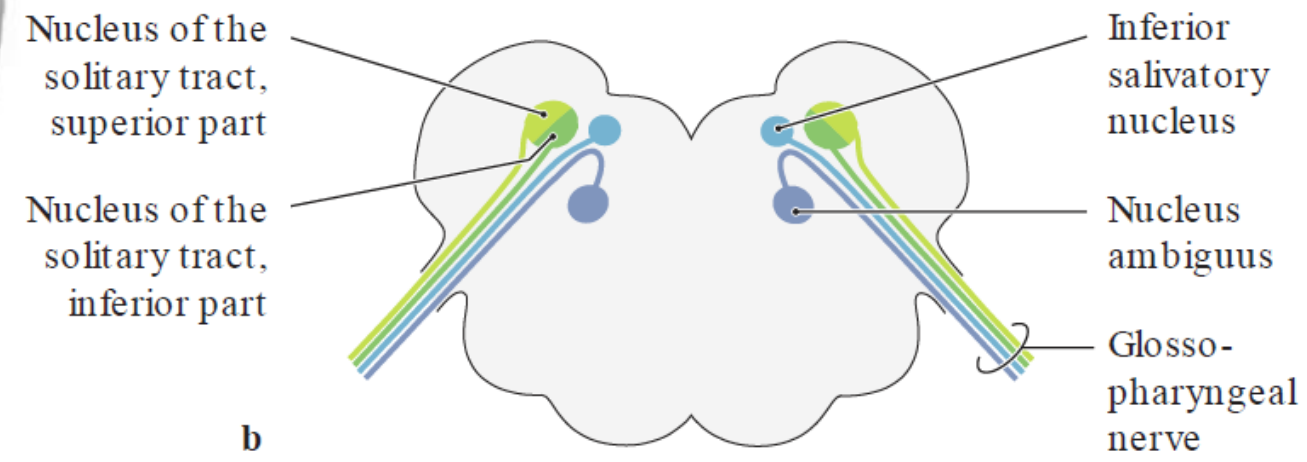
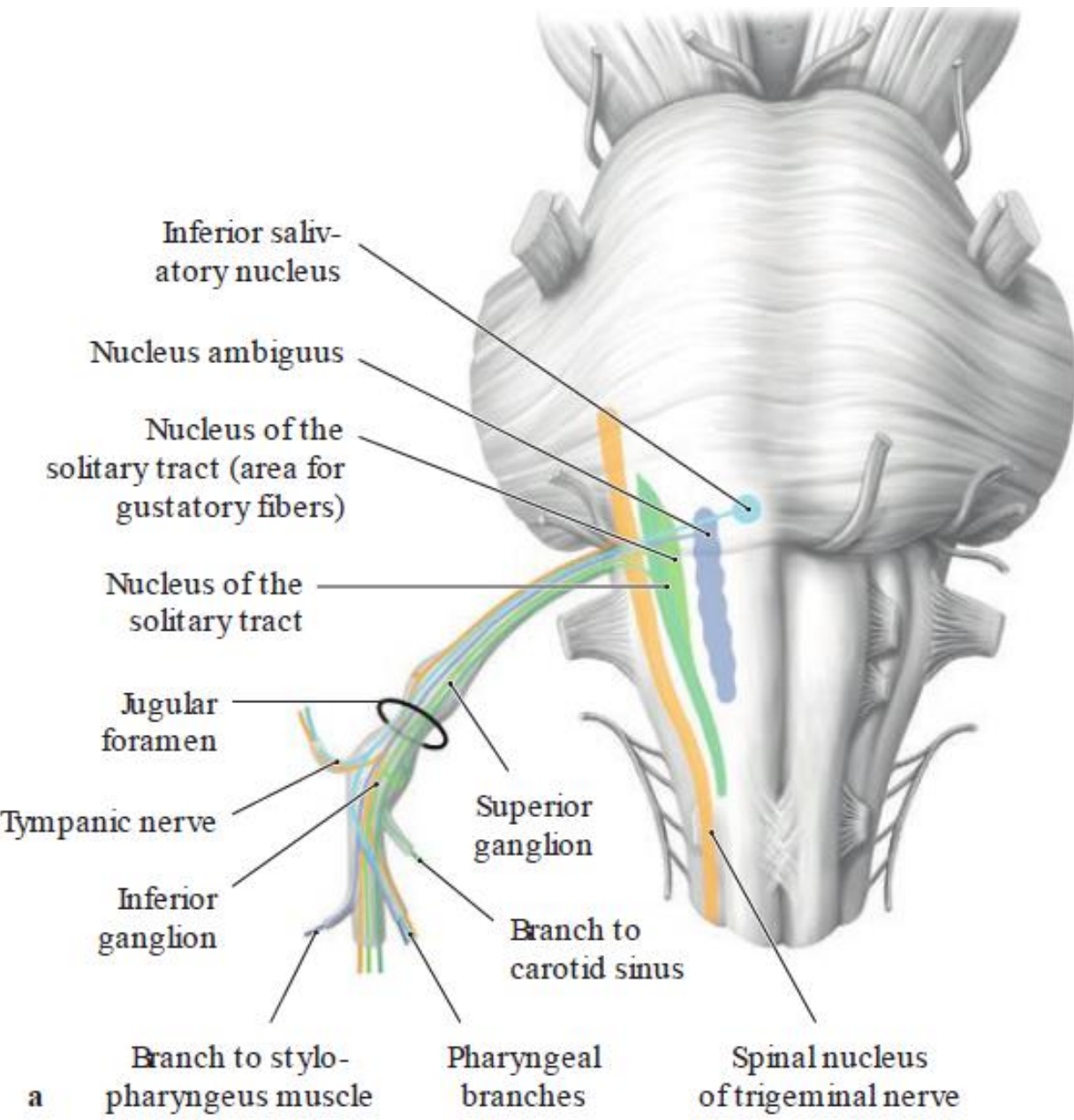


TABLE 22.1 Brainstem reflexes involving the facial nerve

	Corneal Reflex	Sucking Reflex	Blinking to Light	Blinking to Noise	Sound Attenuation
Receptor	Cornea	Lips	Retina	Cochlea	Cochlea
Afferent	Ophthalmic nerve	Mandibular nerve	Optic nerve	Cochlear nucleus	Cochlear nucleus
First synapse	Spinal nucleus of trigeminal	Pontine nucleus of trigeminal	Superior colliculus	Inferior colliculus	Superior olivary nucleus
Second synapse	Facial nucleus	Facial nucleus	Facial nucleus	Facial nucleus	Facial nucleus
Muscle	Orbicularis oculi	Orbicularis oris	Orbicularis oculi	Orbicularis oculi	Stapedius







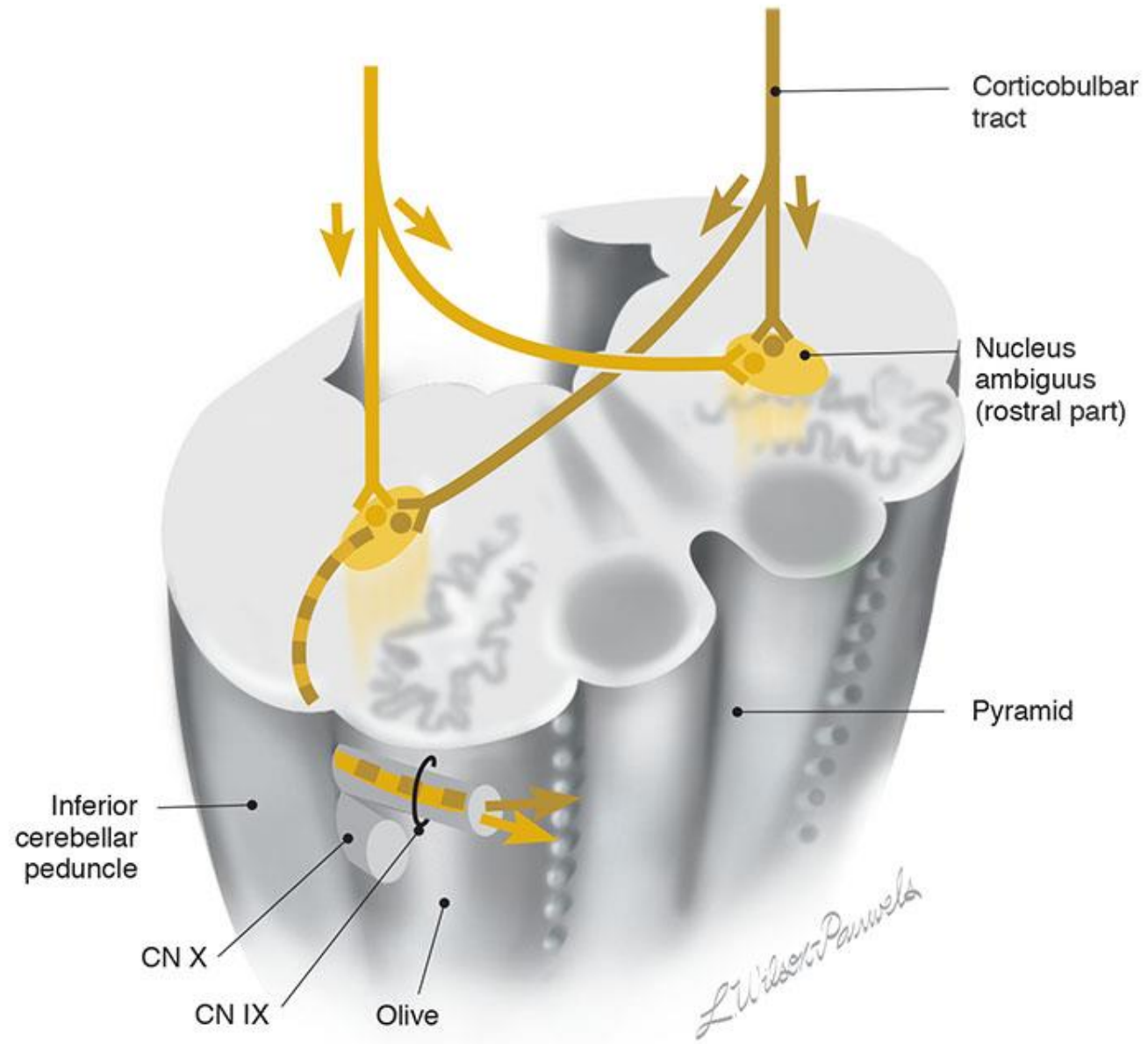


Figure IX-8 Branchial motor component of the glossopharyngeal nerve (section through the rostral part of the medulla).

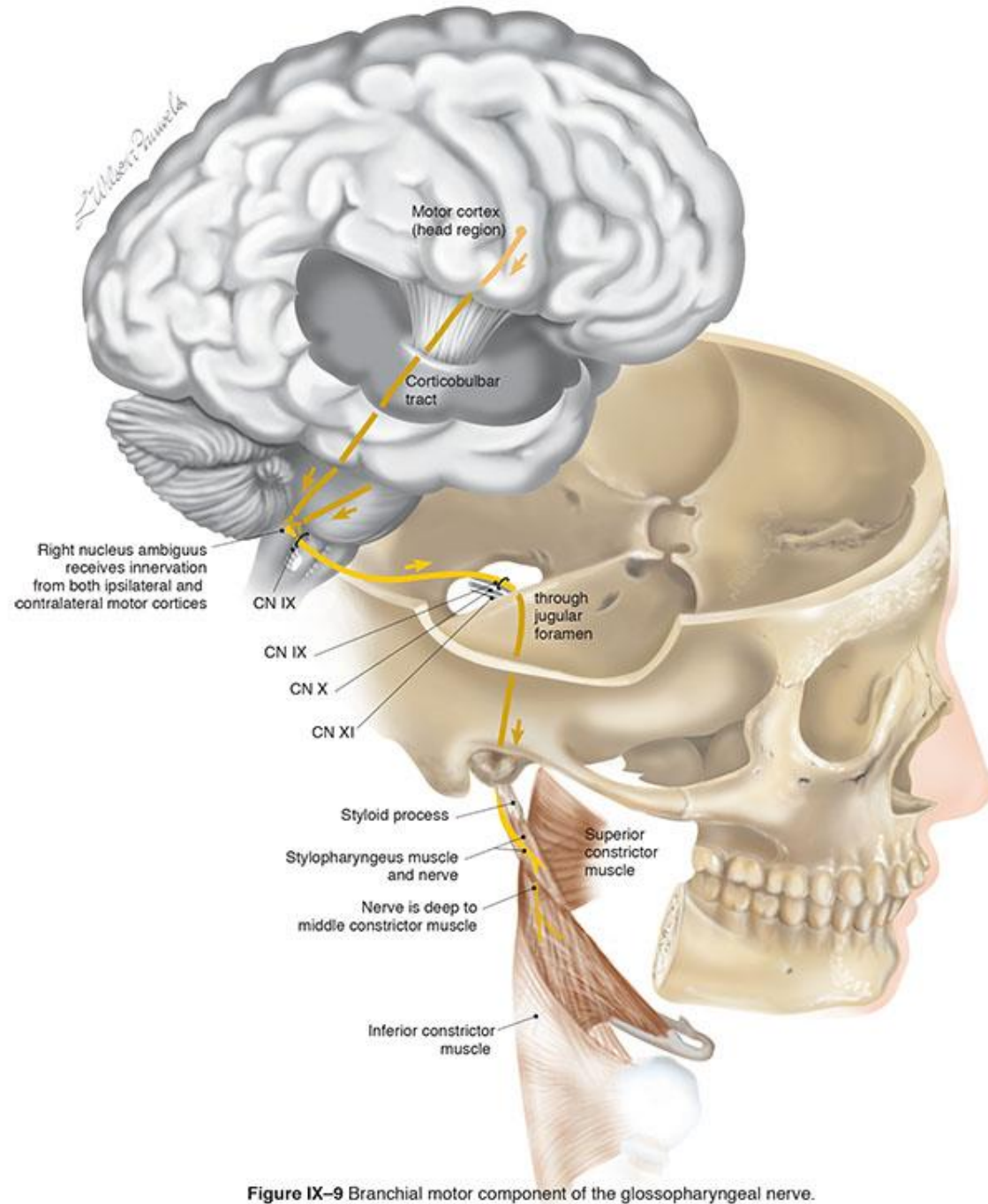


Figure IX-9 Branchial motor component of the glossopharyngeal nerve.

From Cranial Nerves 3rd Ed. ©2010, Wilson-Pauwels, Stewart, Akesson, Spacey, PMPH-USA

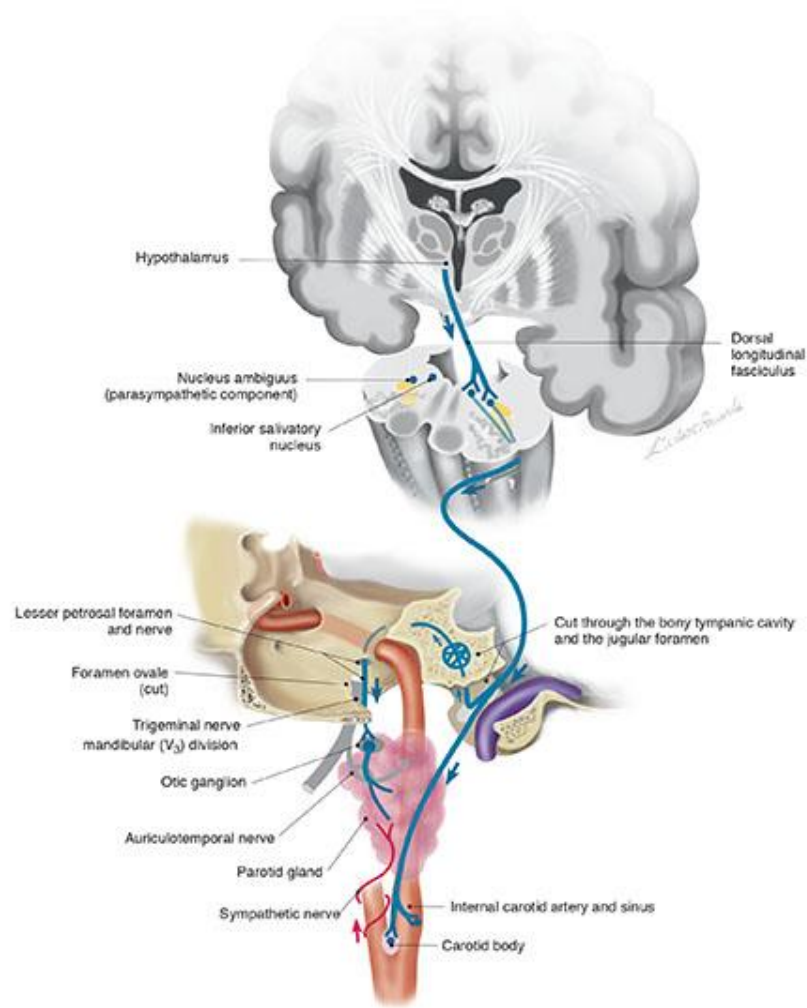
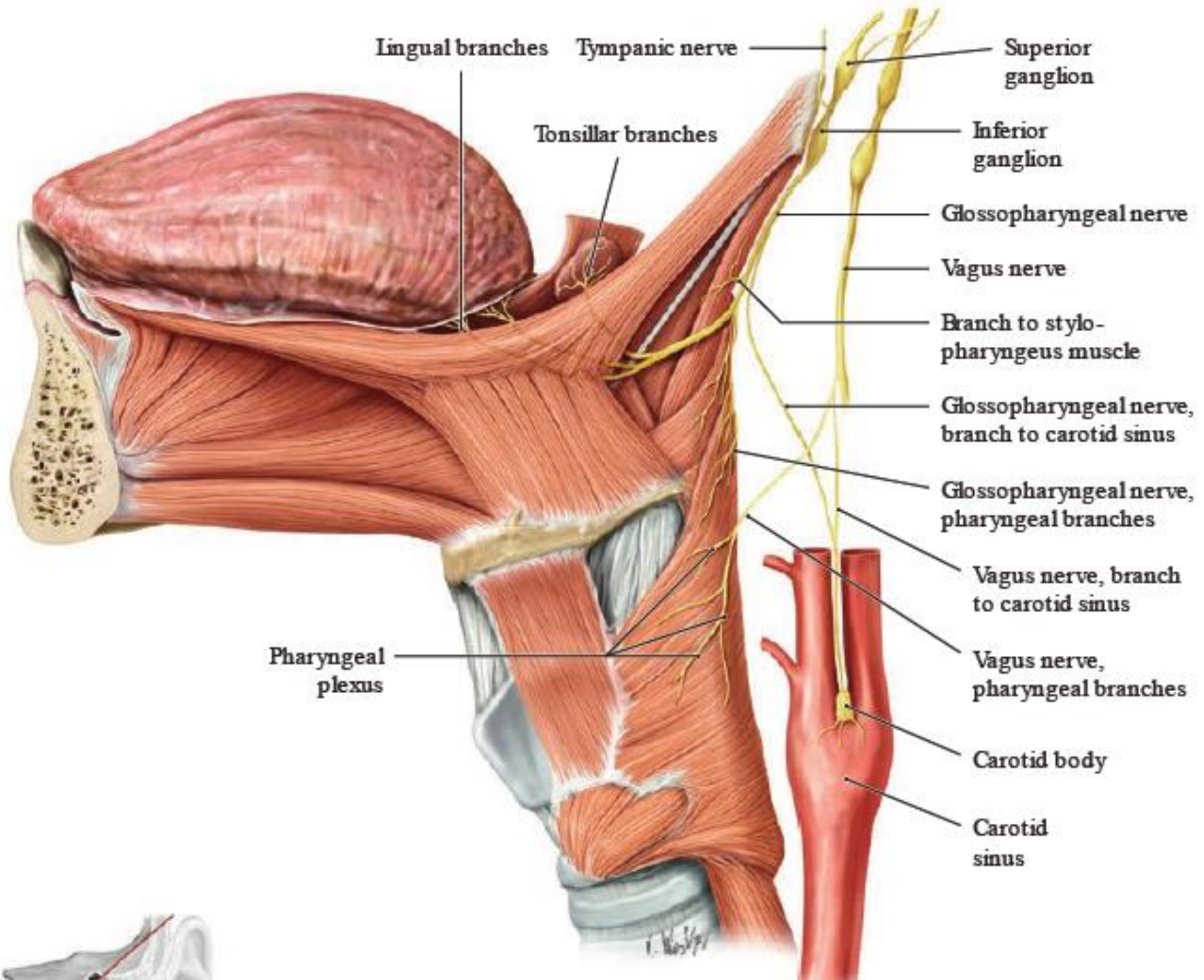
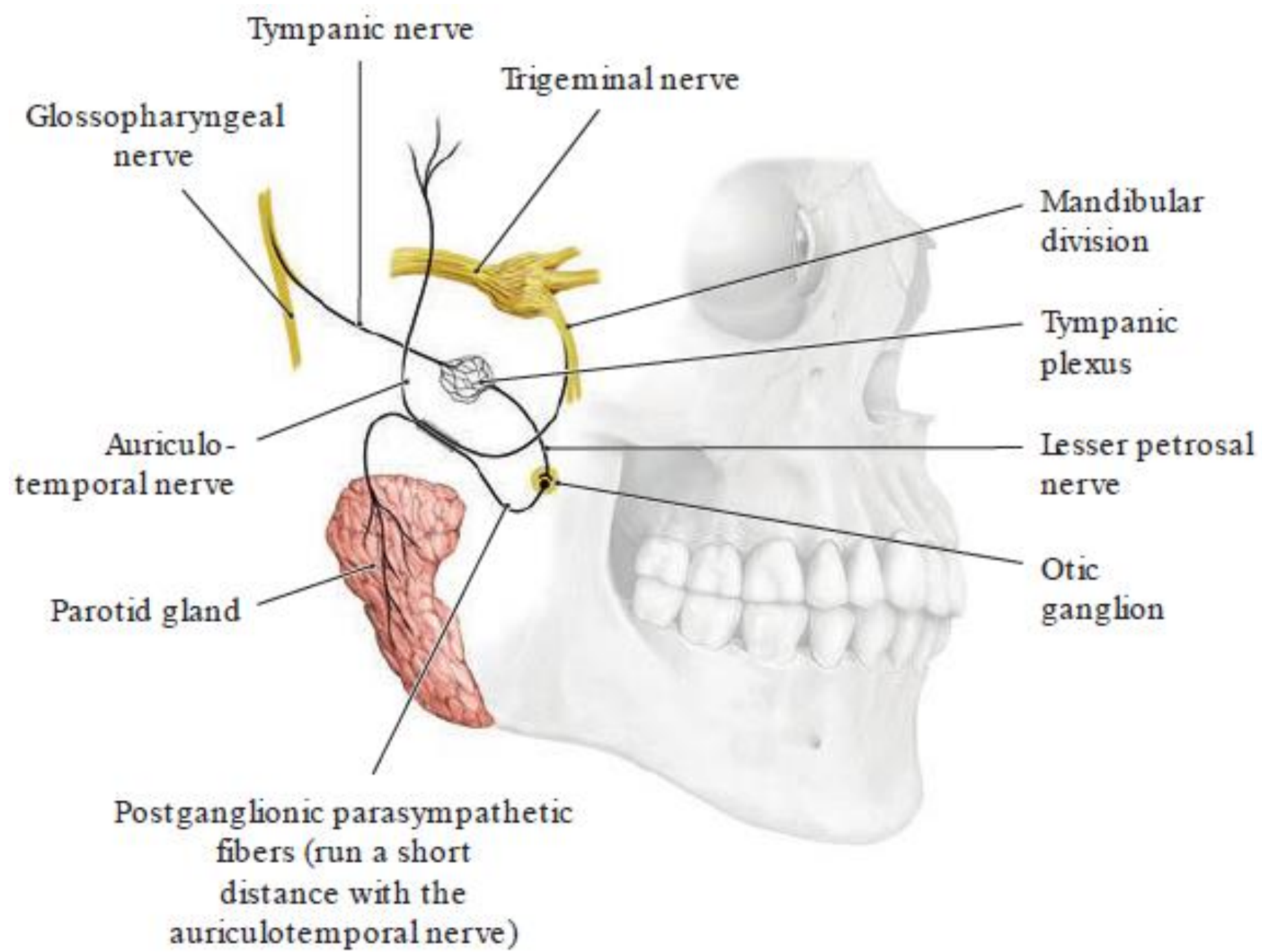
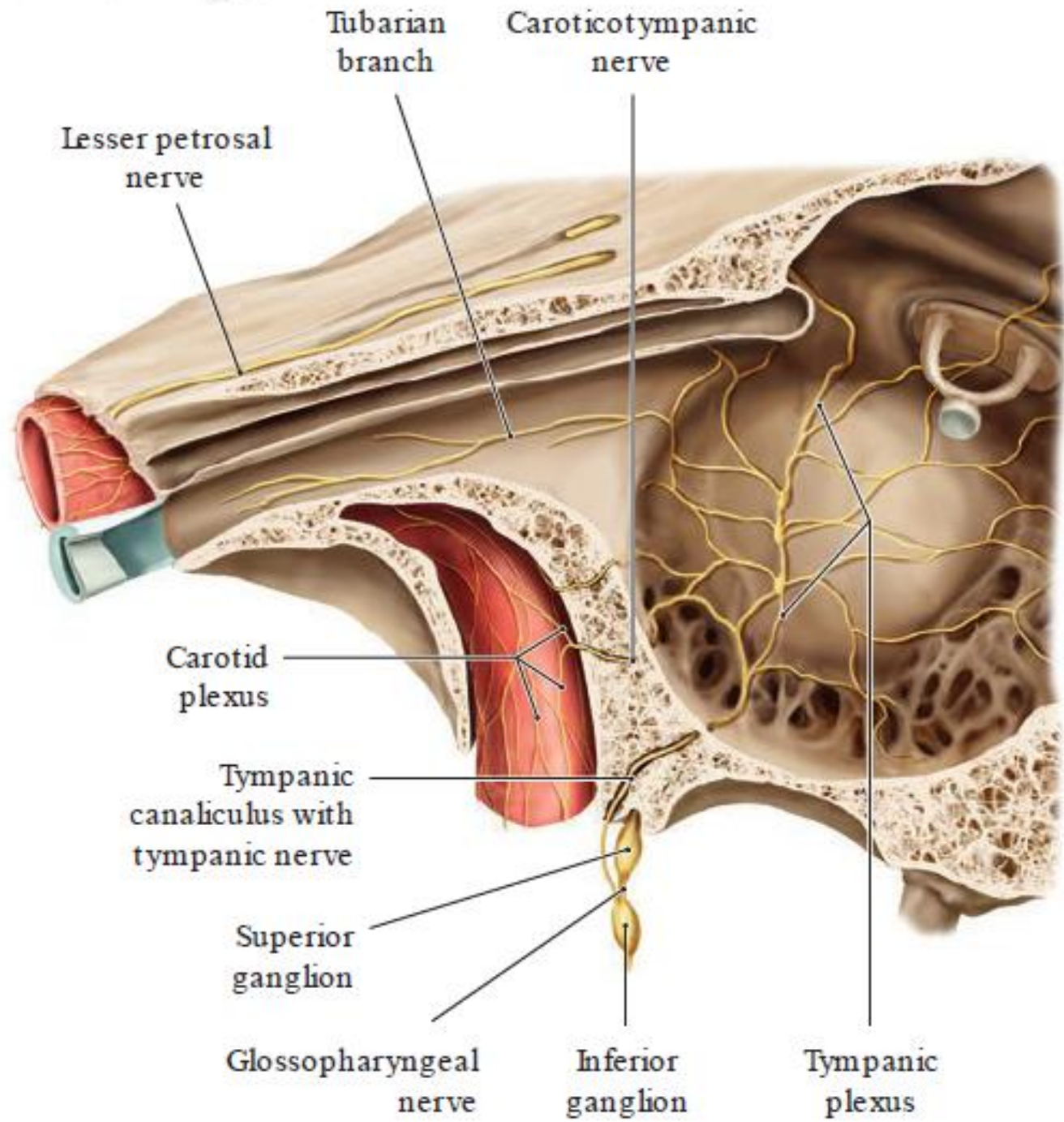


Figure IX-11 Parasympathetic motor components of the glossopharyngeal nerve (CN IX) to: parotid gland, internal carotid artery and sinus, and carotid body.

From Cranial Nerves 3rd Ed. ©2010, Wilson-Pauwels, Stewart, Akesson, Spacey, PMPH-USA







Tubarian branch

Carotidotympanic nerve

Lesser petrosal nerve

Carotid plexus

Tympanic canaliculus with tympanic nerve

Superior ganglion

Glossopharyngeal nerve

Inferior ganglion

Tympanic plexus

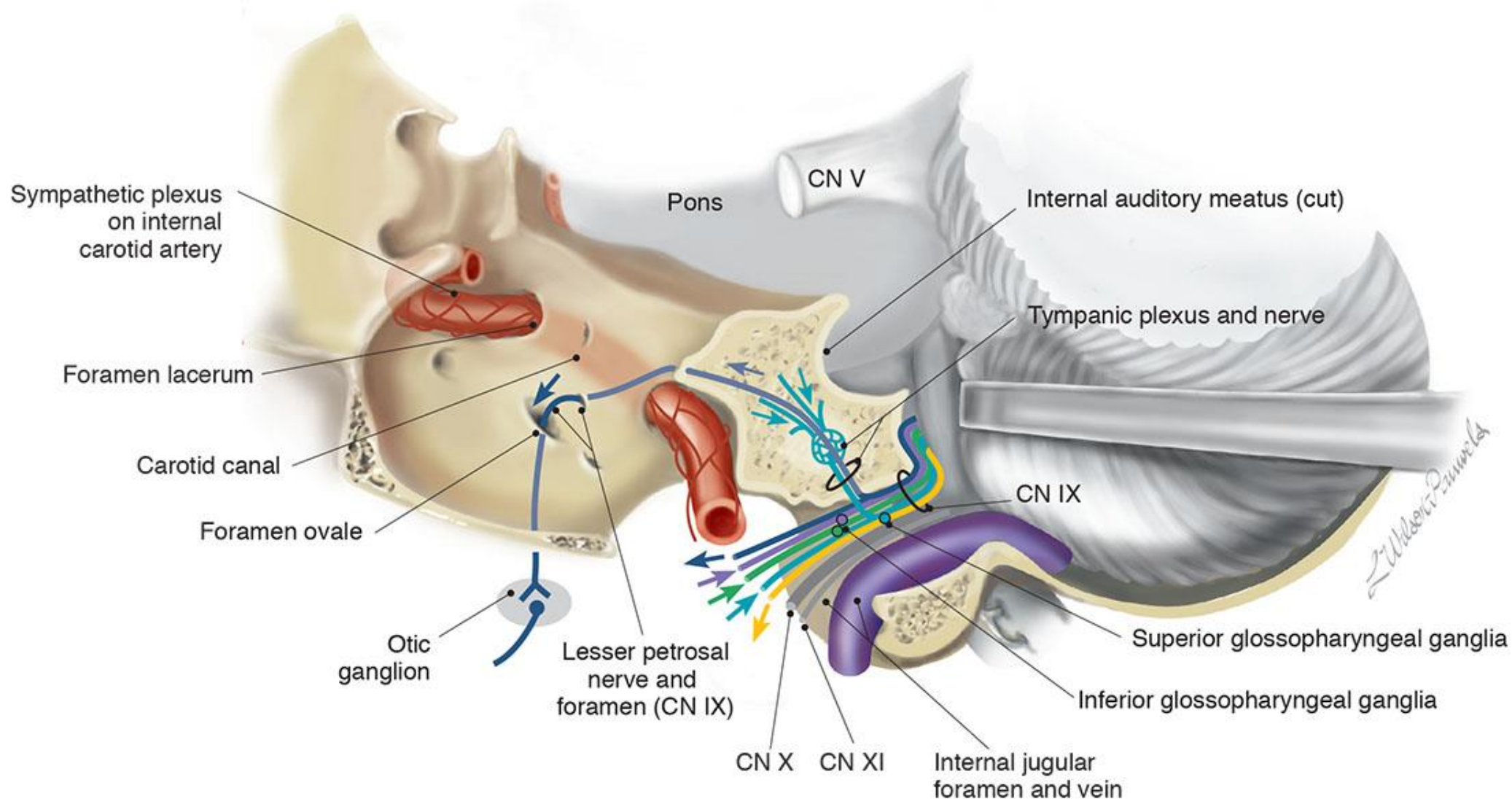


Figure IX-2 Tympanic branch of cranial nerve IX (cut through the petrous temporal bone).

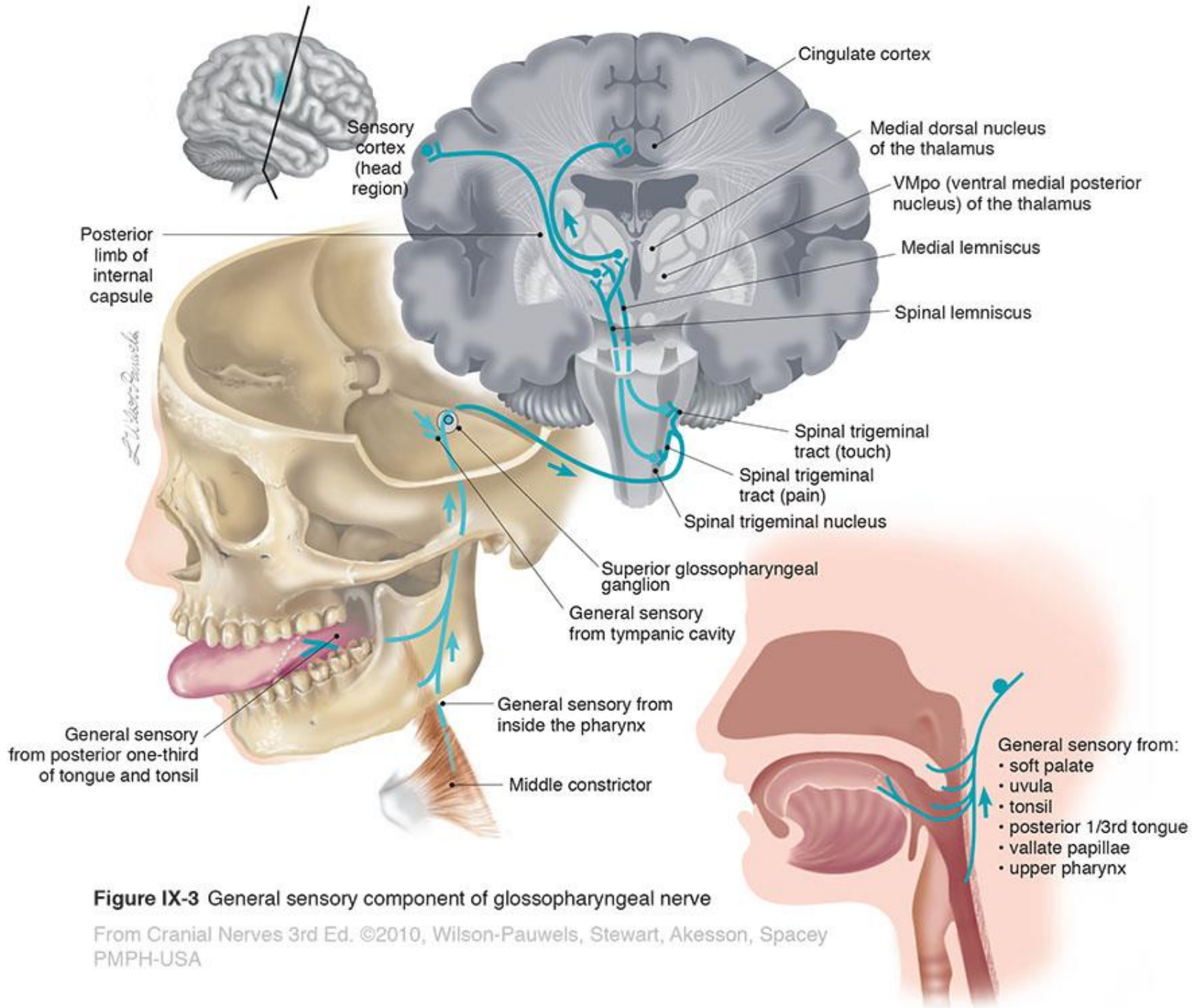


Figure IX-3 General sensory component of glossopharyngeal nerve

From Cranial Nerves 3rd Ed. ©2010, Wilson-Pauwels, Stewart, Akesson, Spacey
PMPH-USA

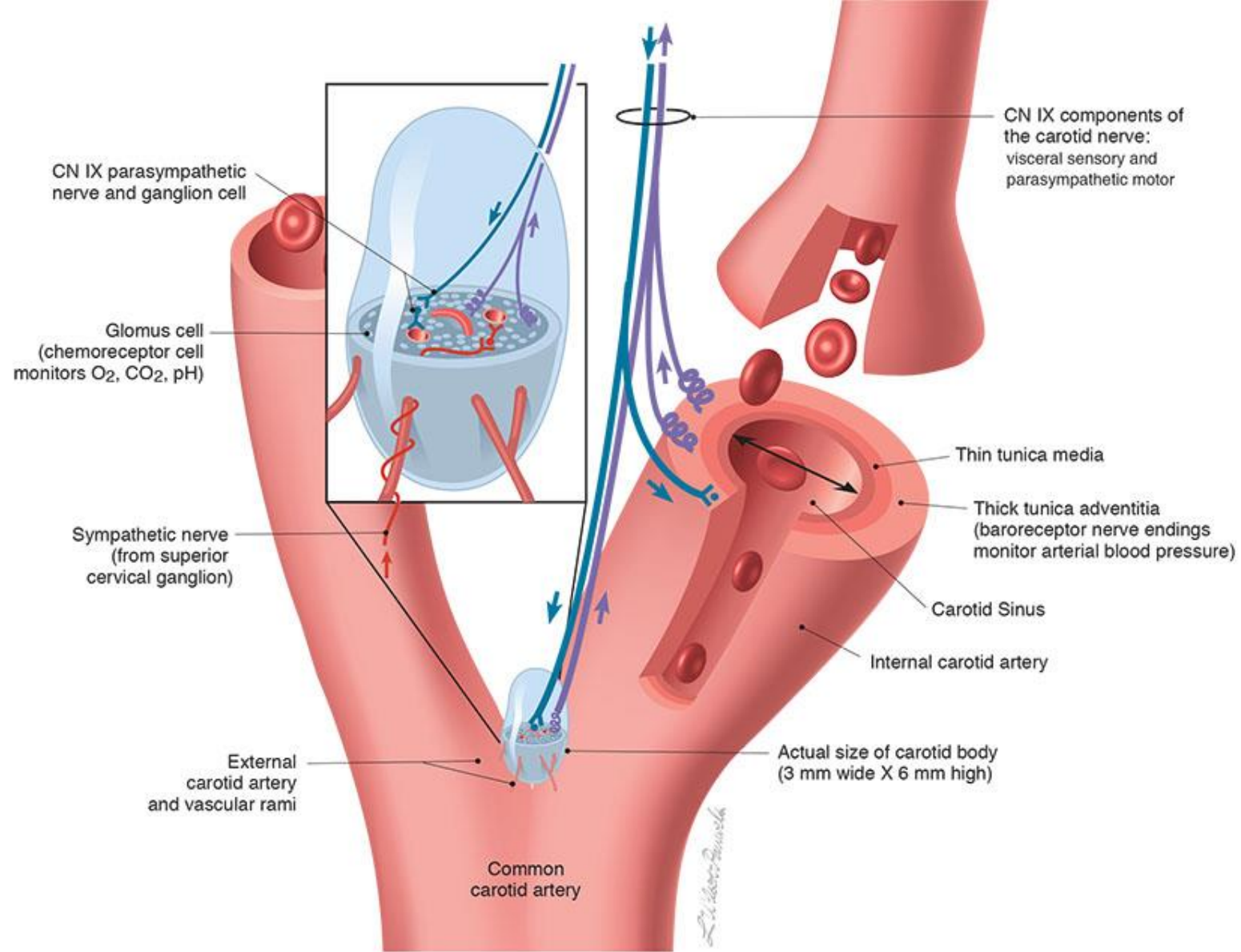


Figure IX-5 The bifurcation of the common carotid artery demonstrating CN IX sensory signals from baroreceptors in the wall of the carotid sinus and chemoreceptors within the carotid body as well as parasympathetic efferents that are vasodilatory to vessels of the carotid body and sinus. (The carotid body is enlarged to show structural detail.)

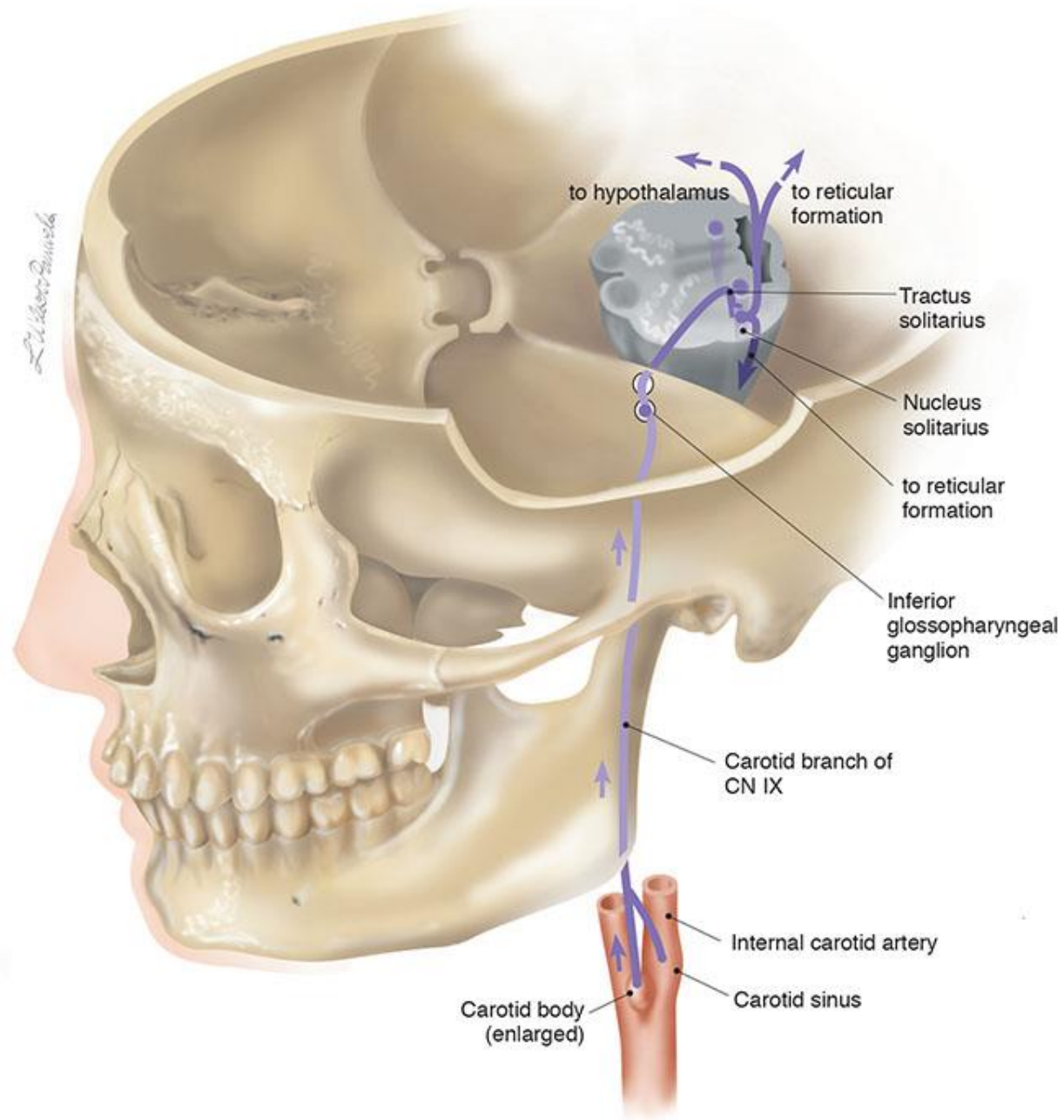
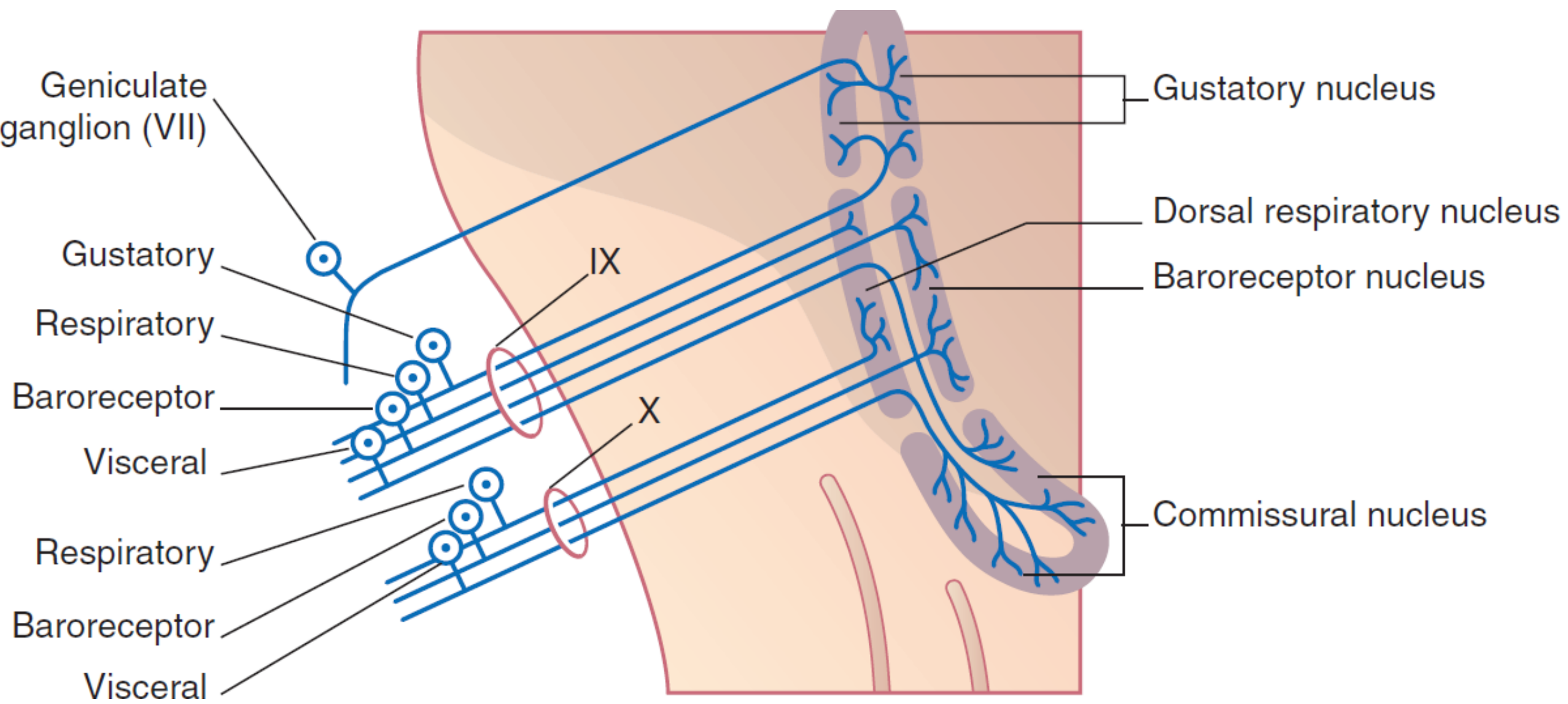
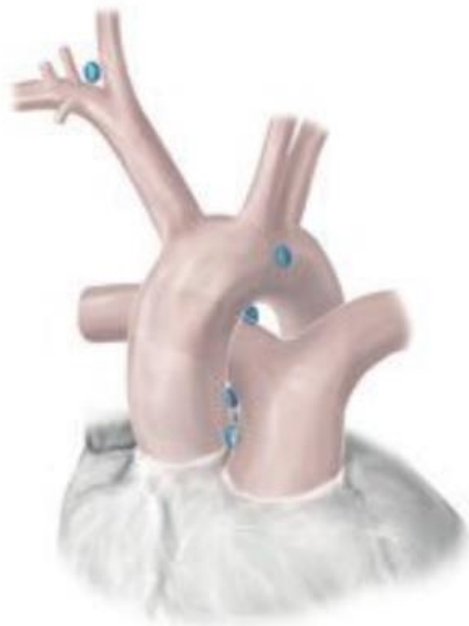
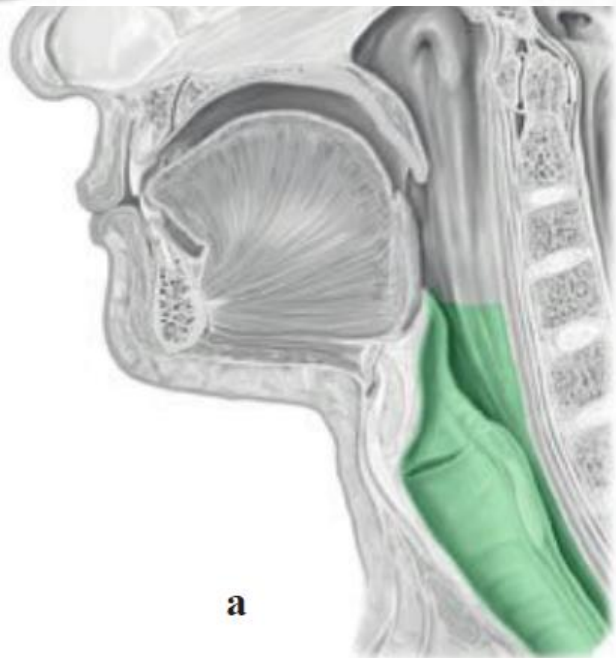
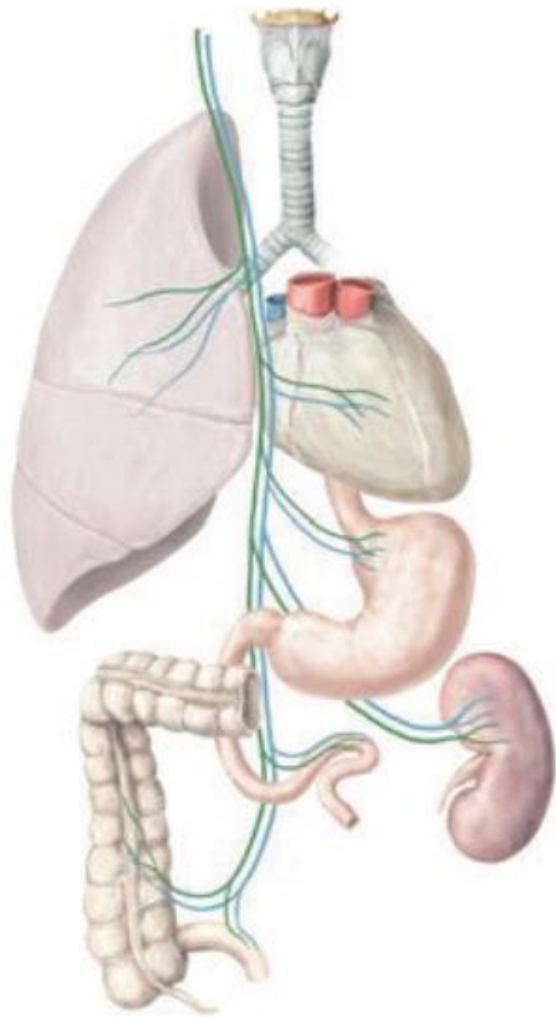
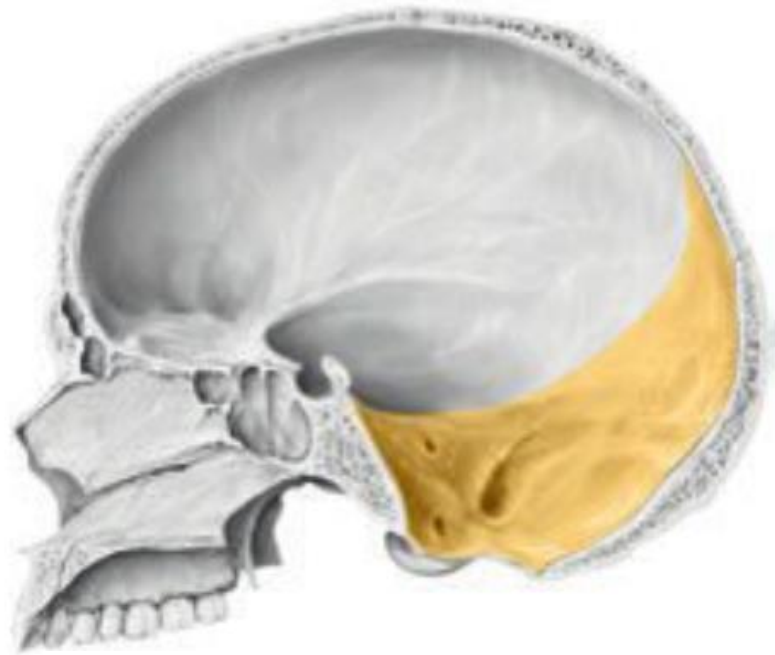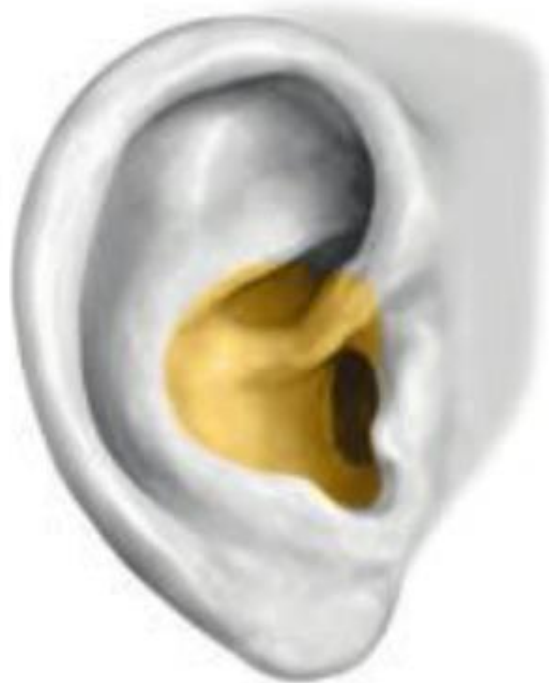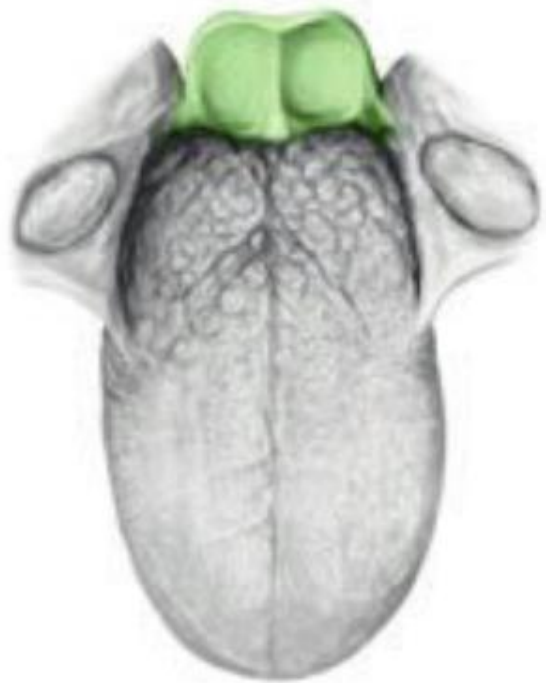


Figure IX-6 Visceral sensory component of the glossopharyngeal nerve—elevated brain stem.

From Cranial Nerves 3rd Ed. ©2010, Wilson-Pauwels, Stewart, Akesson, Spacey, PMPH-USA

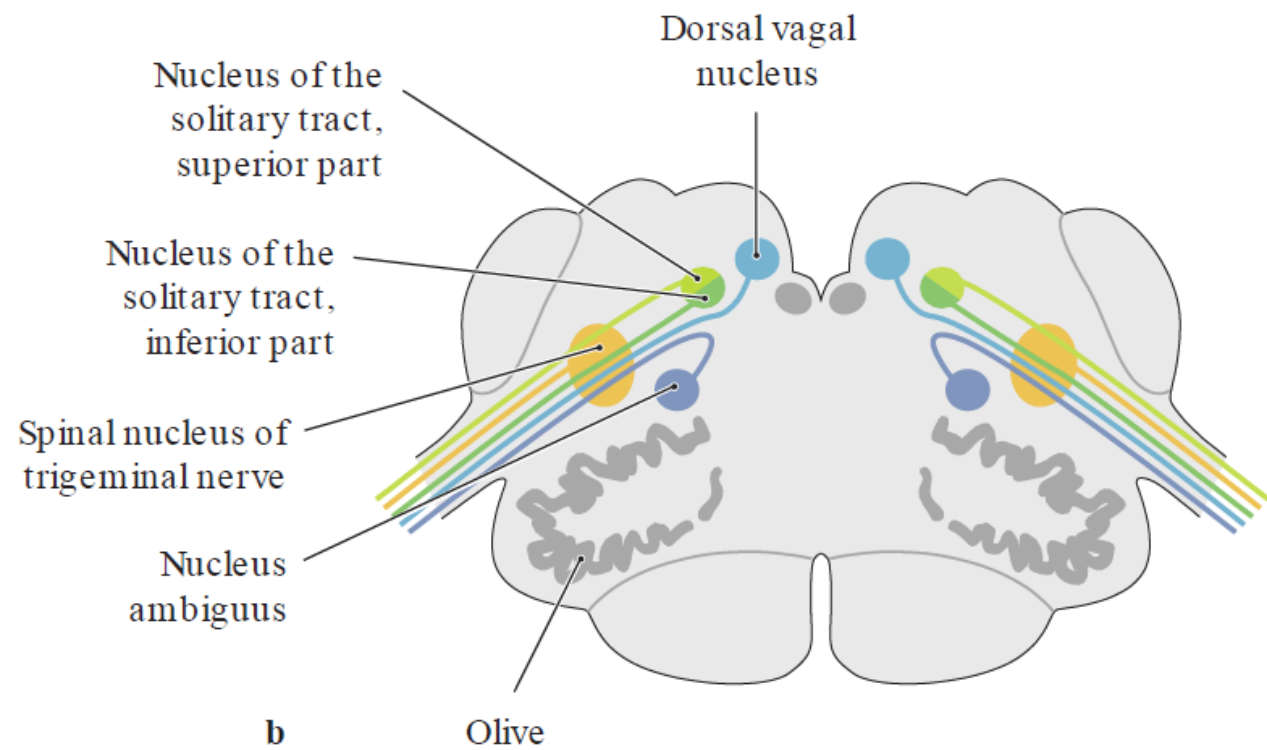
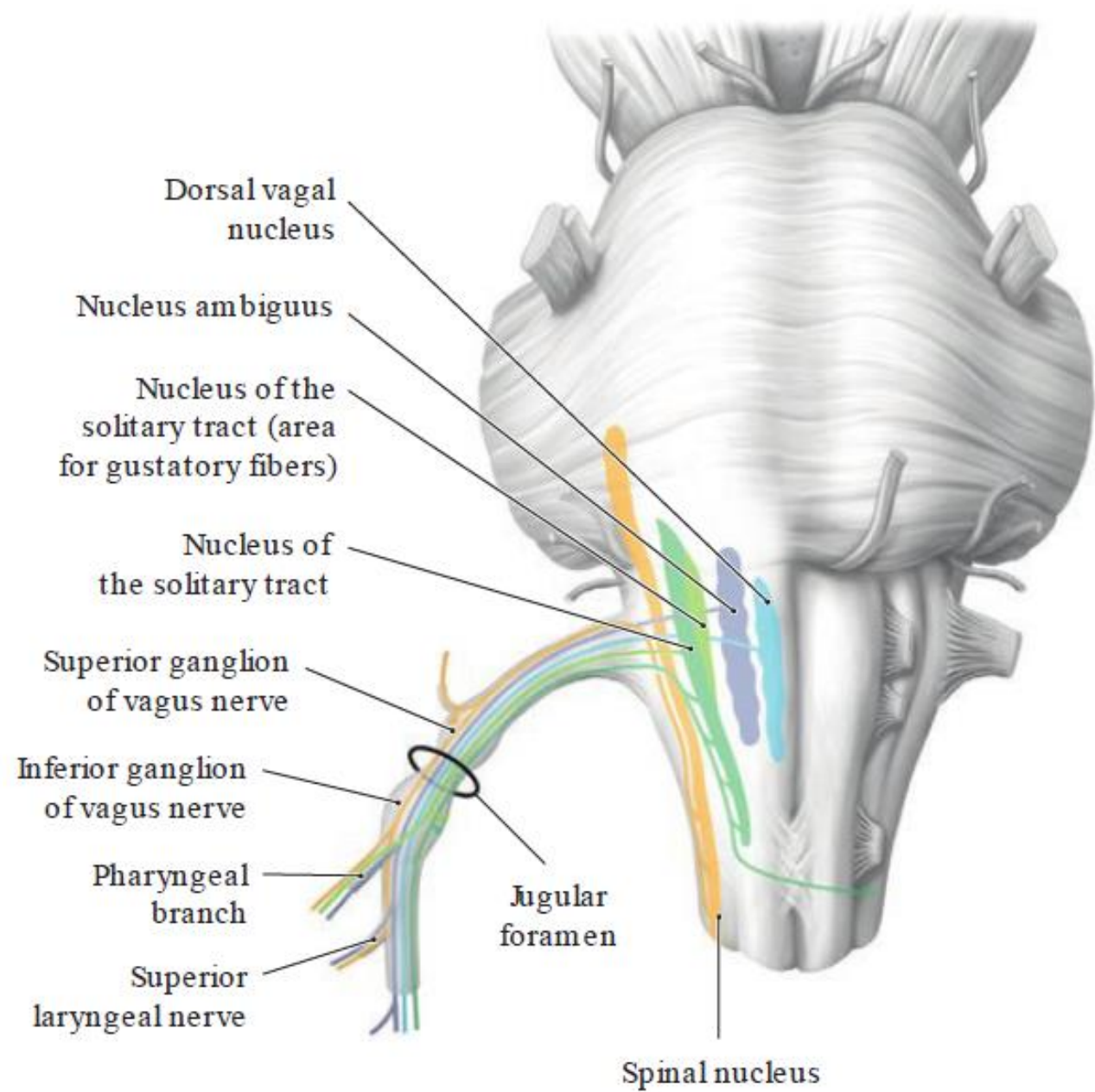




a

TABLE 27.1 Summary of Vagus Nerve Fiber Types

Fiber Type	Function	Cell Body Location	Distribution
GSA (general somatic afferent)	Cutaneous sensation	Superior ganglion	External ear, meatus, tympanic membrane, and posterior fossa dura mater
GVA (general visceral afferent)	Visceral sensation	Inferior ganglion	Cervical, thoracic, and abdominal branches, and carotid and aortic bodies
SVA (special visceral afferent)	Taste	Inferior ganglion	Epiglottis taste buds
GVE (general visceral efferent)	Visceral smooth muscle and glands	Dorsal motor nucleus of CN X	Muscles and glands of the alimentary canal, cardiac and pulmonary plexuses
SVE (special visceral efferent)	Swallowing and phonation	Nucleus ambiguus	Pharyngeal, superior laryngeal, and recurrent laryngeal nerves



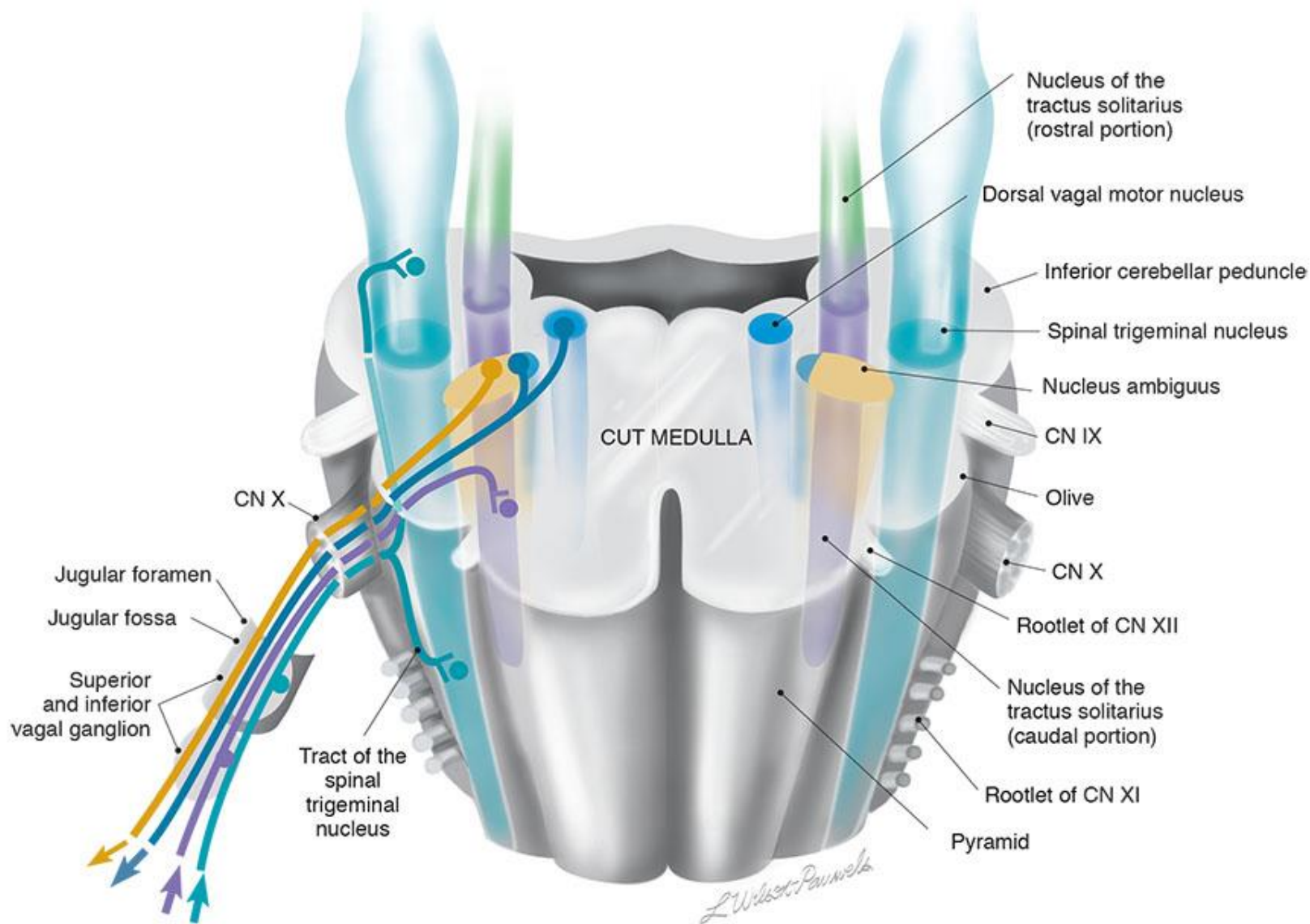


Figure X-2 Cross-section of the medulla at the point of entry of cranial nerve X illustrating the nuclei associated with this nerve.

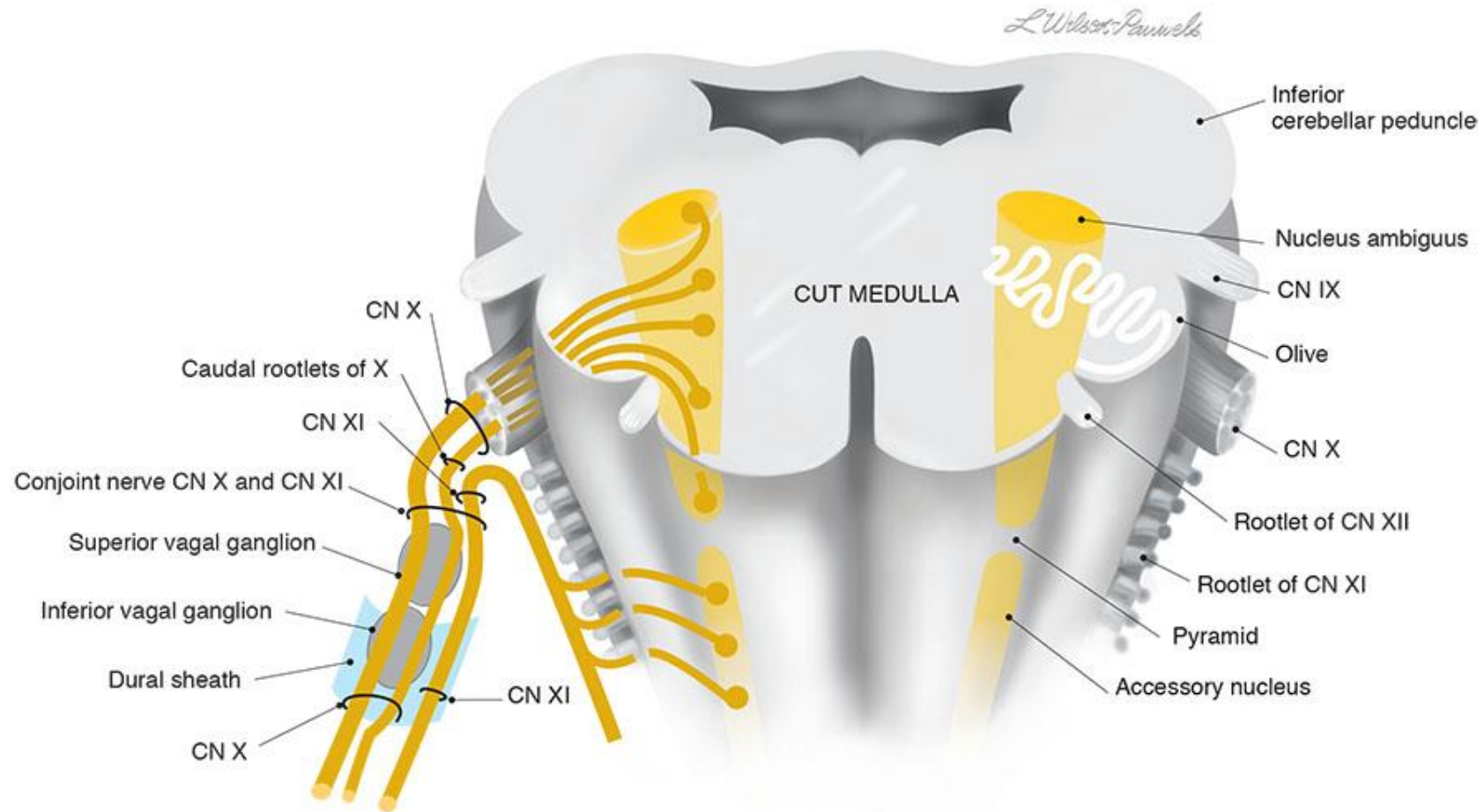


Figure X-3 Cross-section through the rostral (open) medulla demonstrating the branchial motor component of cranial nerve X including spinal rootlets of cranial nerve XI.

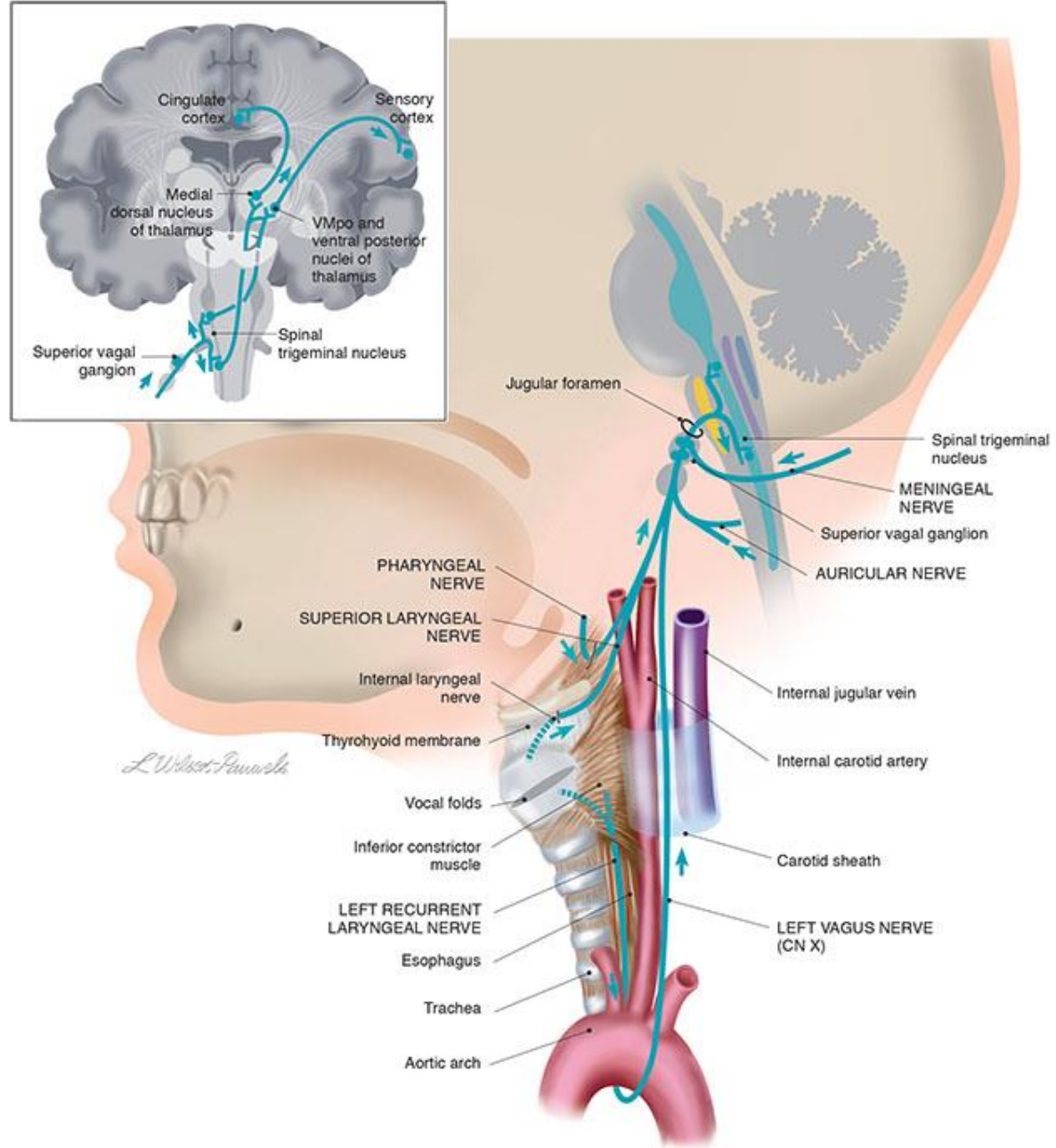
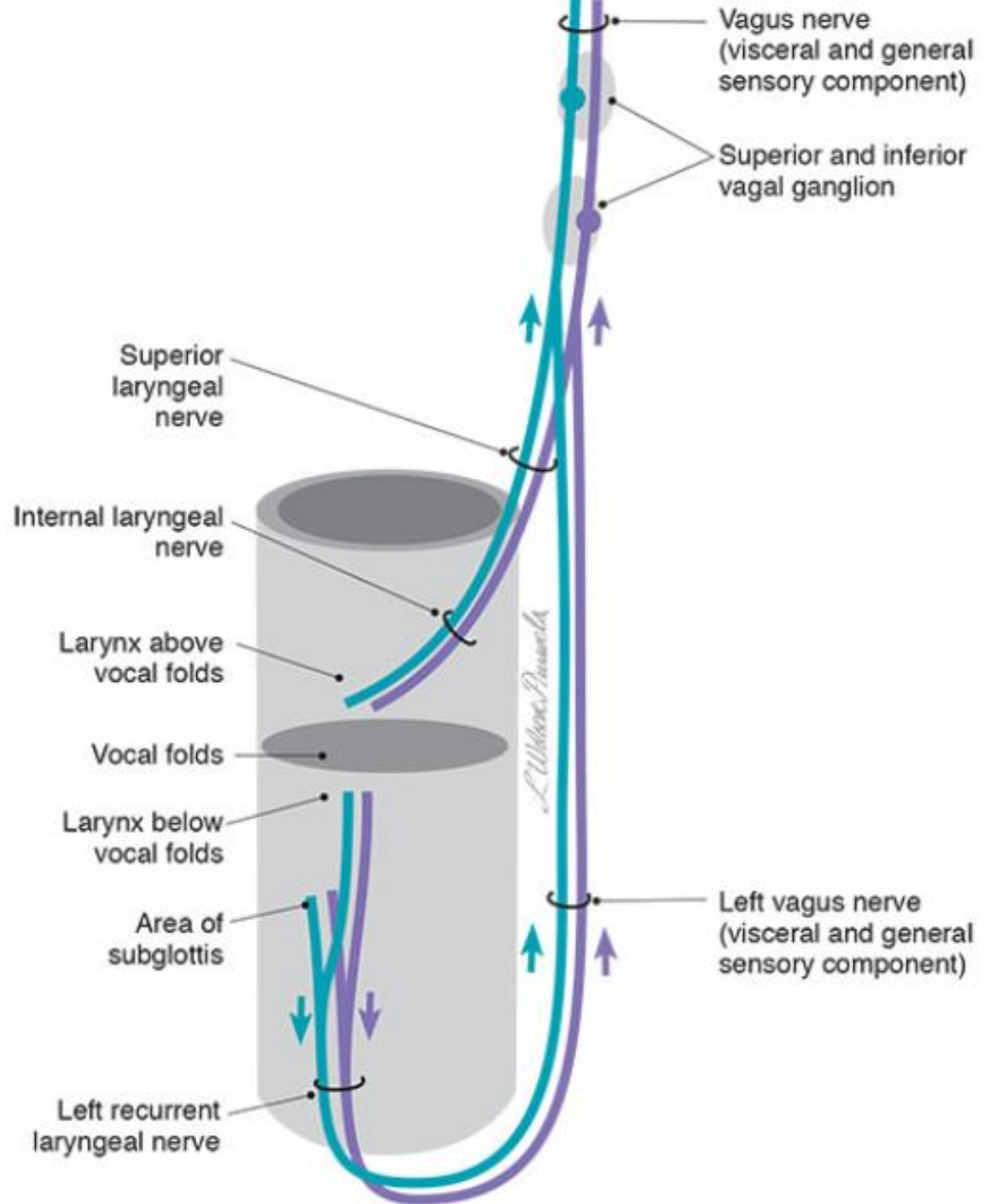


Figure X-5 General sensory component of the vagus nerve.



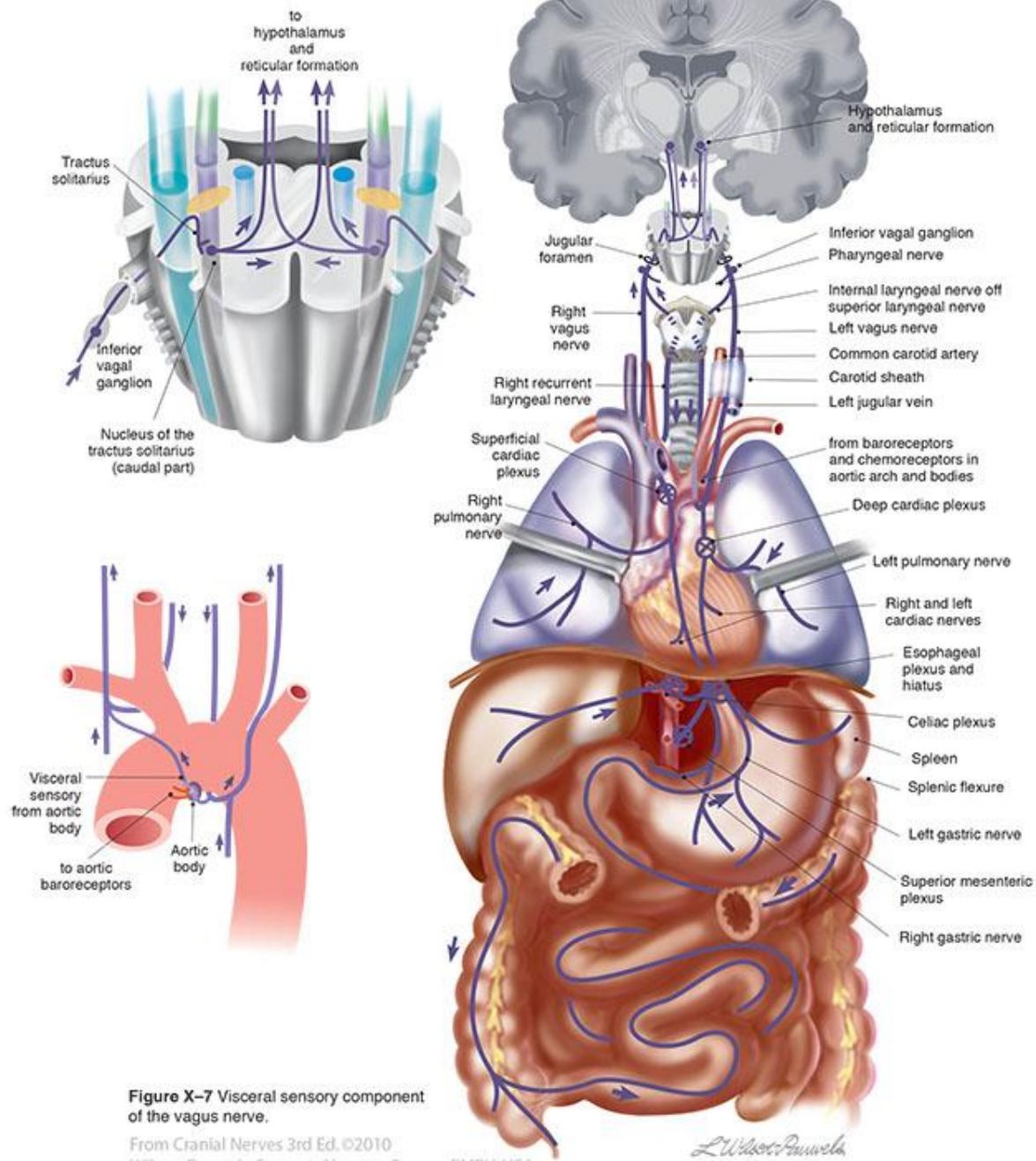


Figure X-7 Visceral sensory component of the vagus nerve.

From *Cranial Nerves* 3rd Ed. ©2010
Wilson-Pauwels, Stewart, Akesson, Spacey, PMPH-USA

L. Wilson-Pauwels

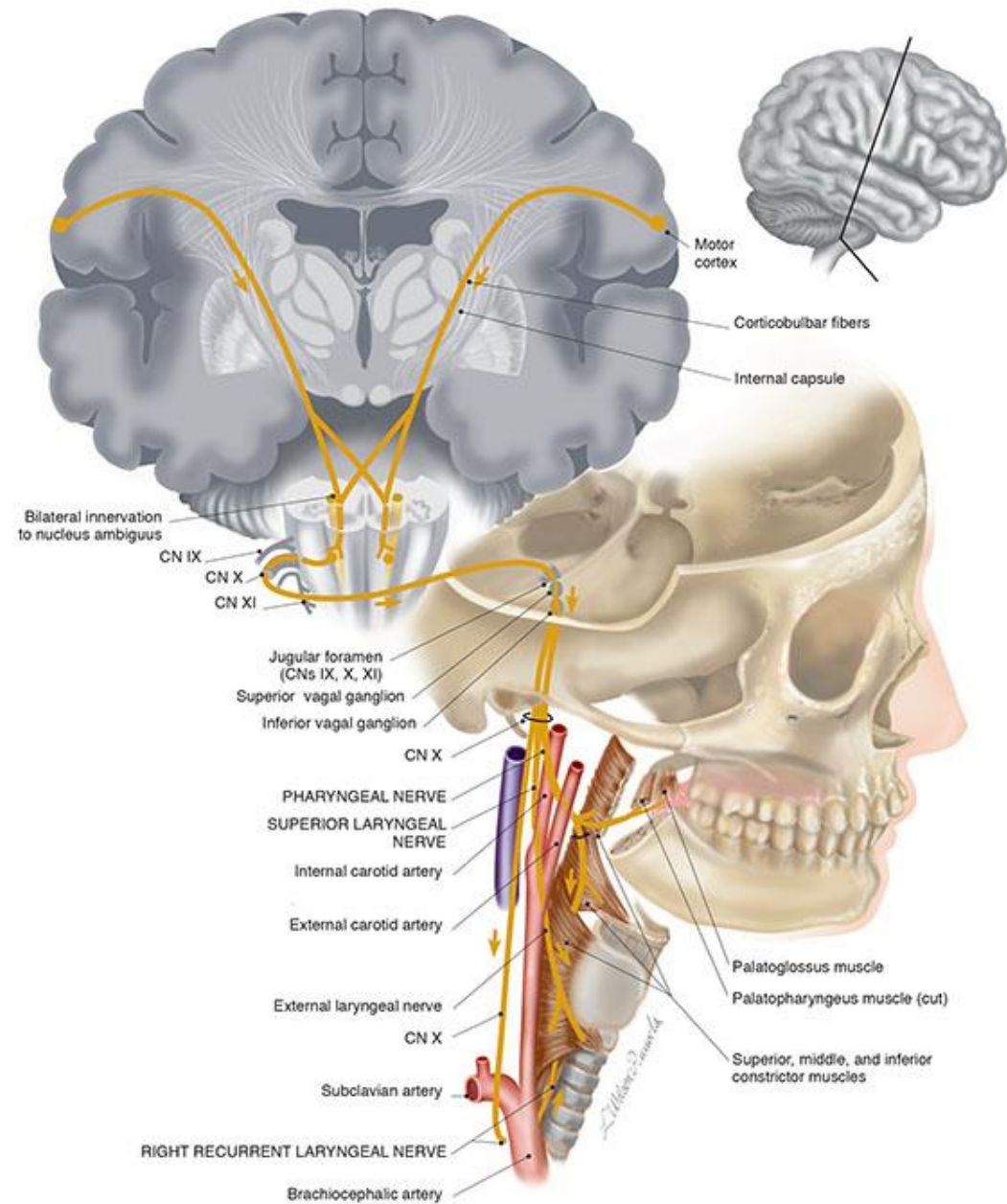


Figure X-8 Branchial motor component of the vagus nerve.

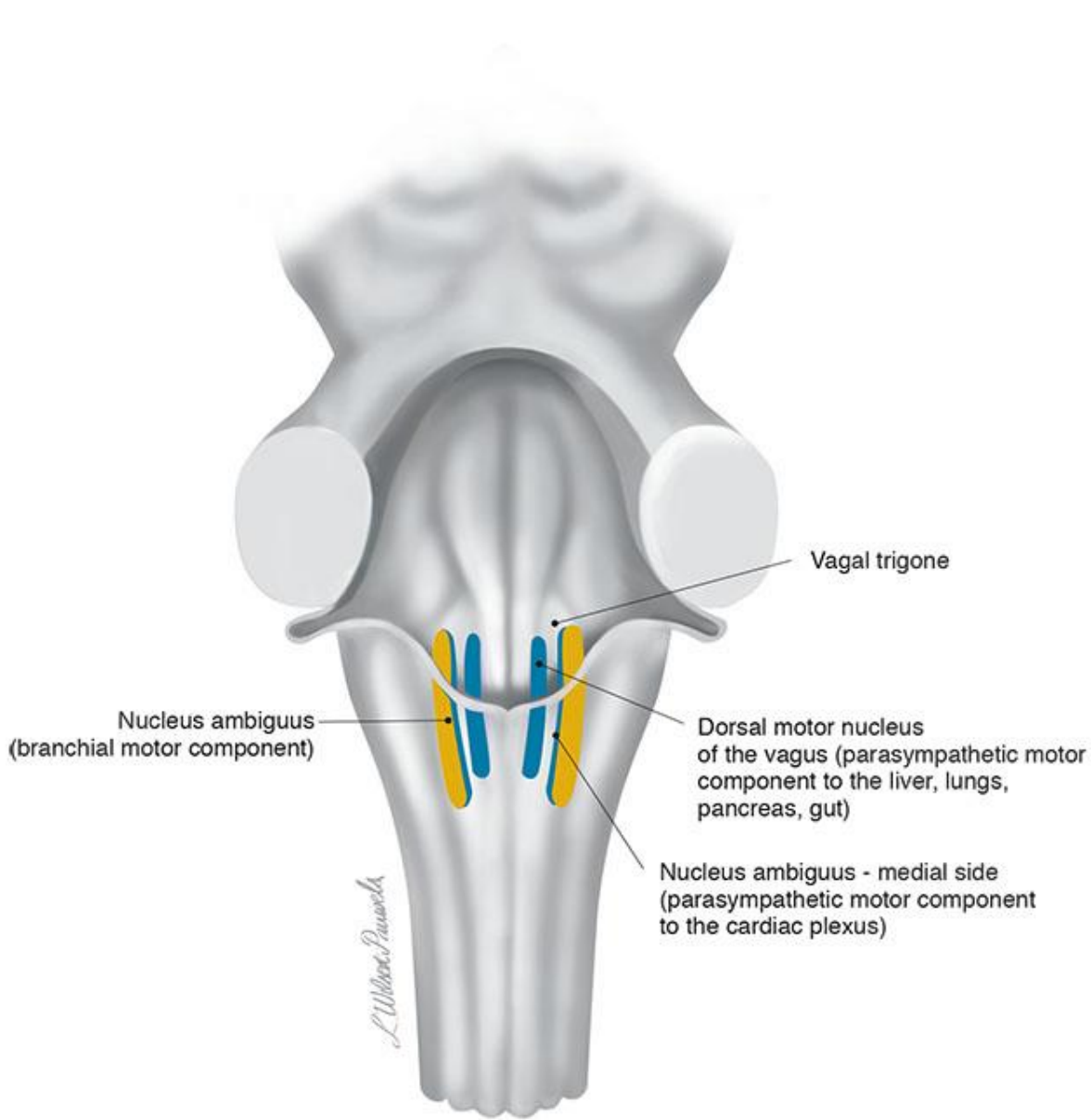


Figure X-9 Parasympathetic motor nuclei of the vagus nerve (posterior brain stem).

From *Cranial Nerves 3rd Ed.* ©2010 Wilson-Pauwels, Stewart, Akesson, Spacey, PMPH-USA

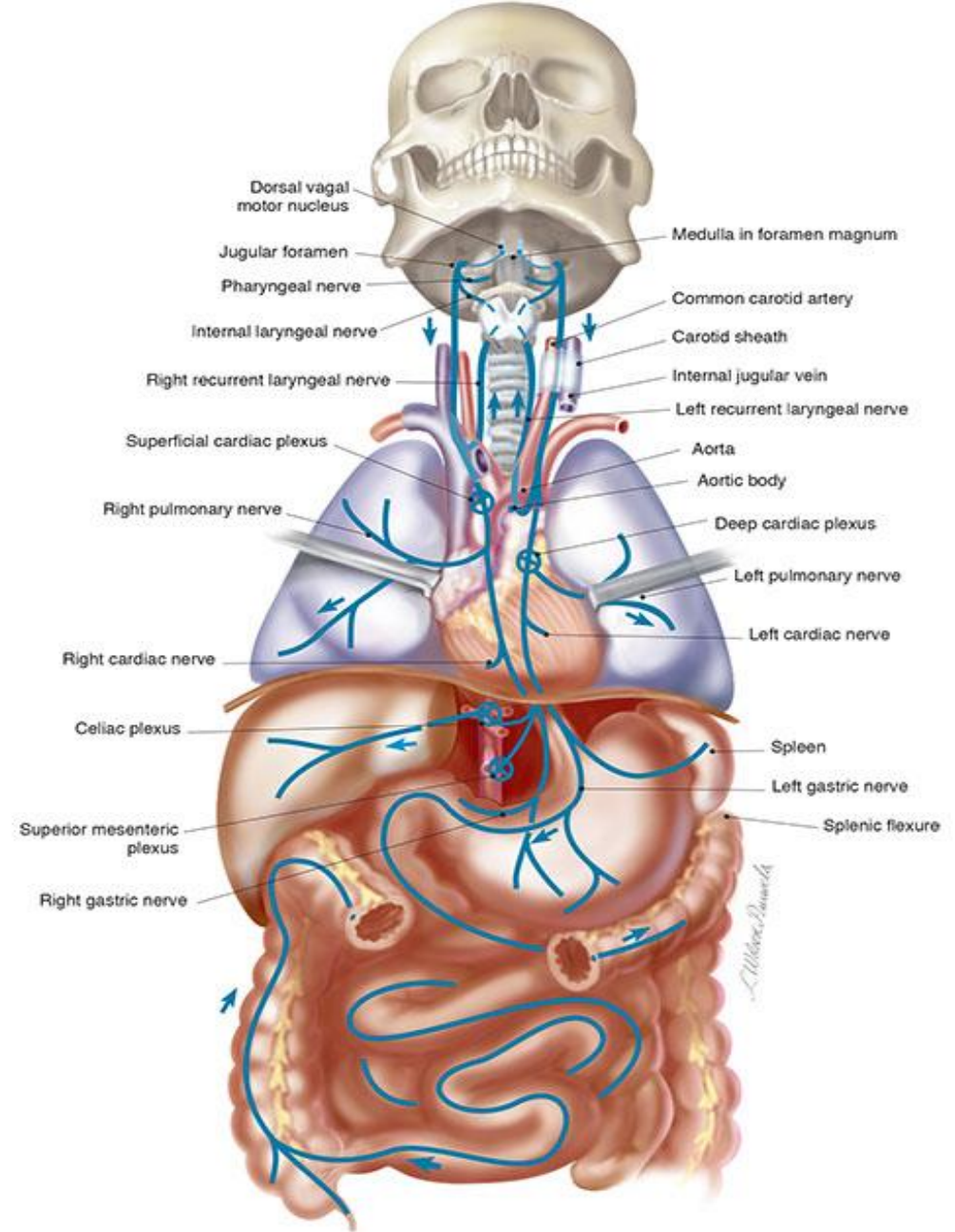


Figure X-10 Parasympathetic motor component of the vagus nerve.

From *Cranial Nerves 3rd Ed.* ©2010 Wilson-Pauwels, Stewart, Akesson, Spacey PMPH-USA

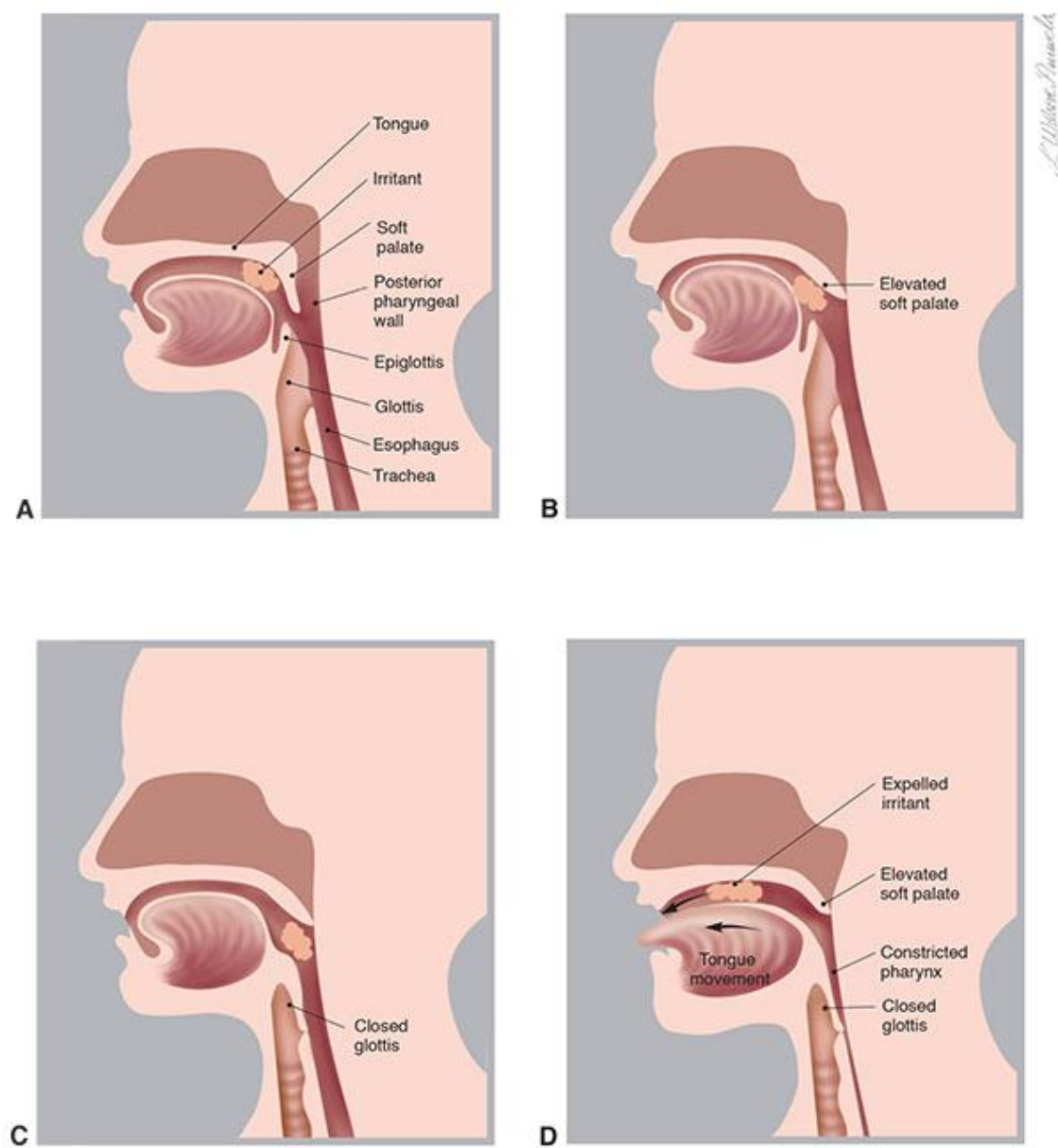
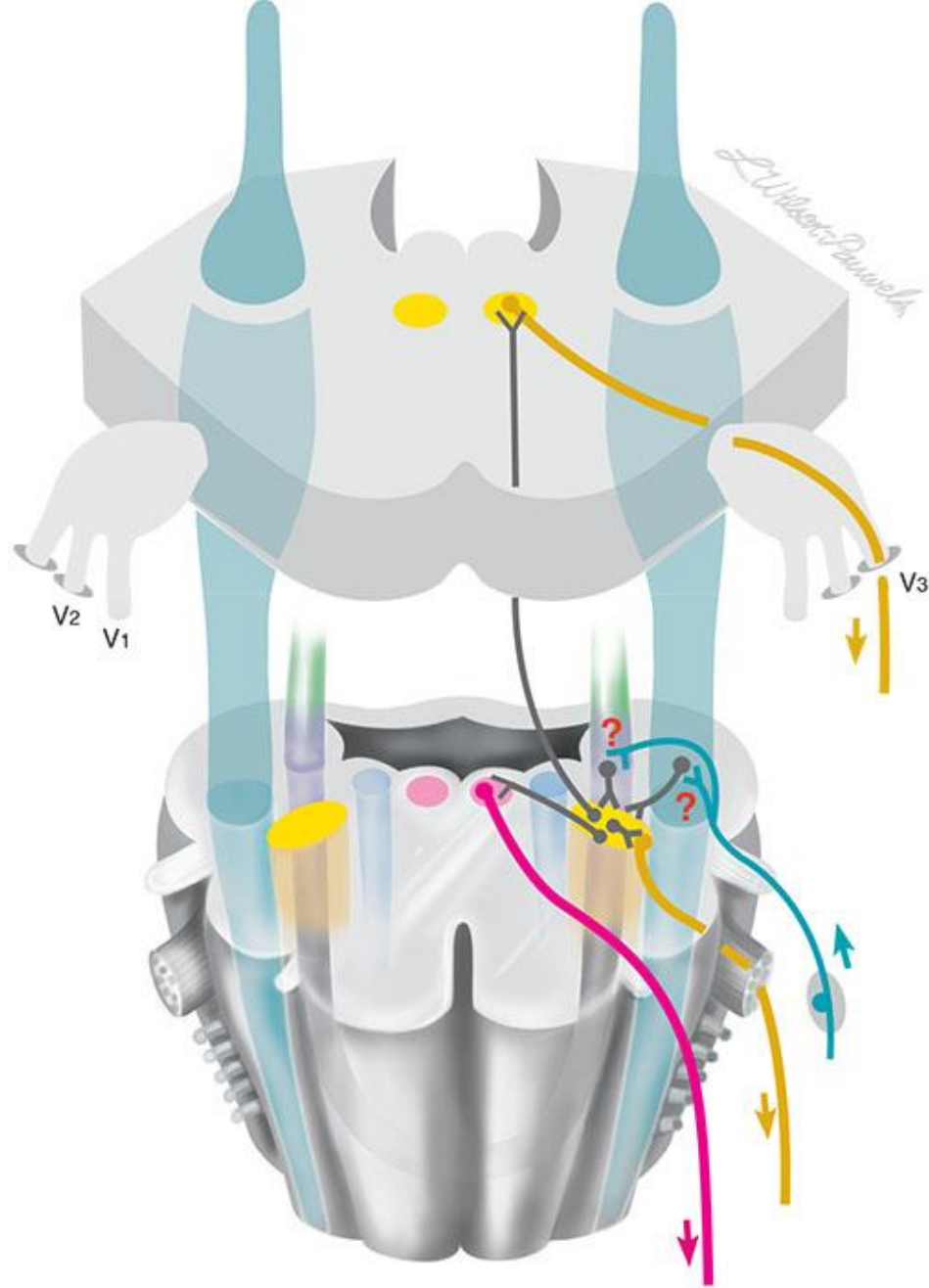
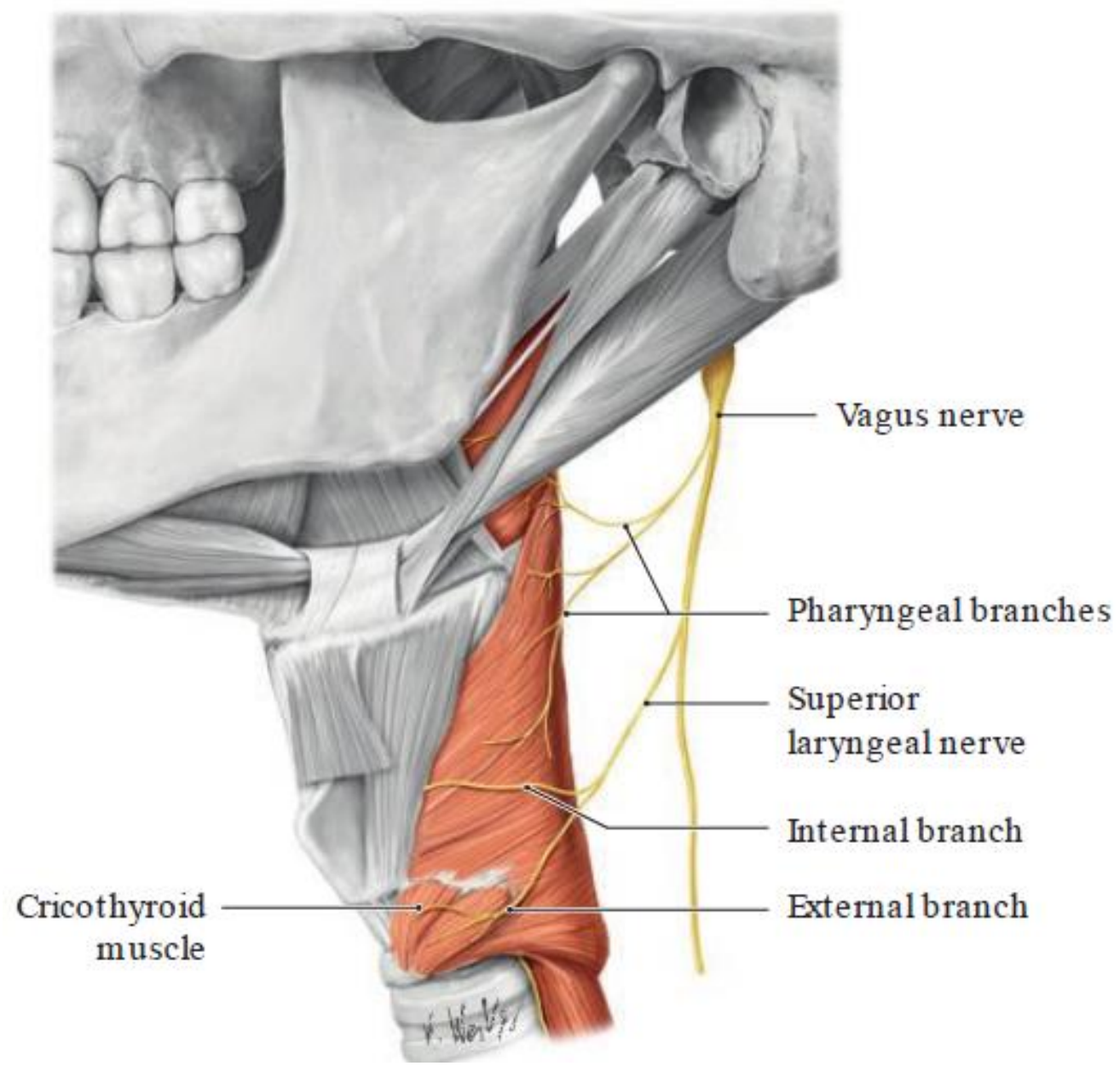
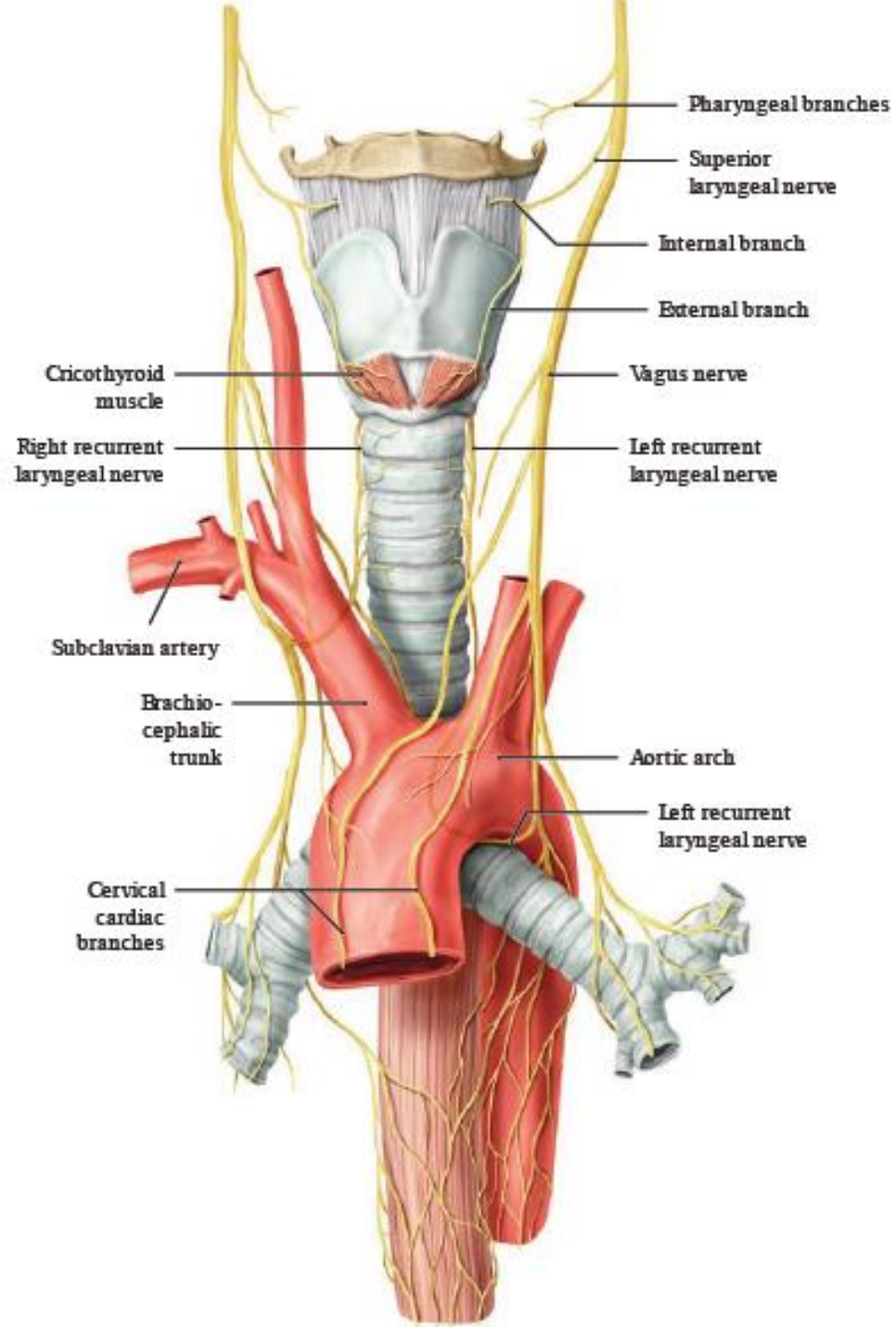


Figure IX-12 Steps in the gag reflex. **A**, Irritant in the mouth. **B**, Soft palate elevates, closing the upper respiratory airway. **C**, Glottis is closed to protect the lower respiratory airway. **D**, Pharyngeal wall constricts causing expulsion of the foreign object.





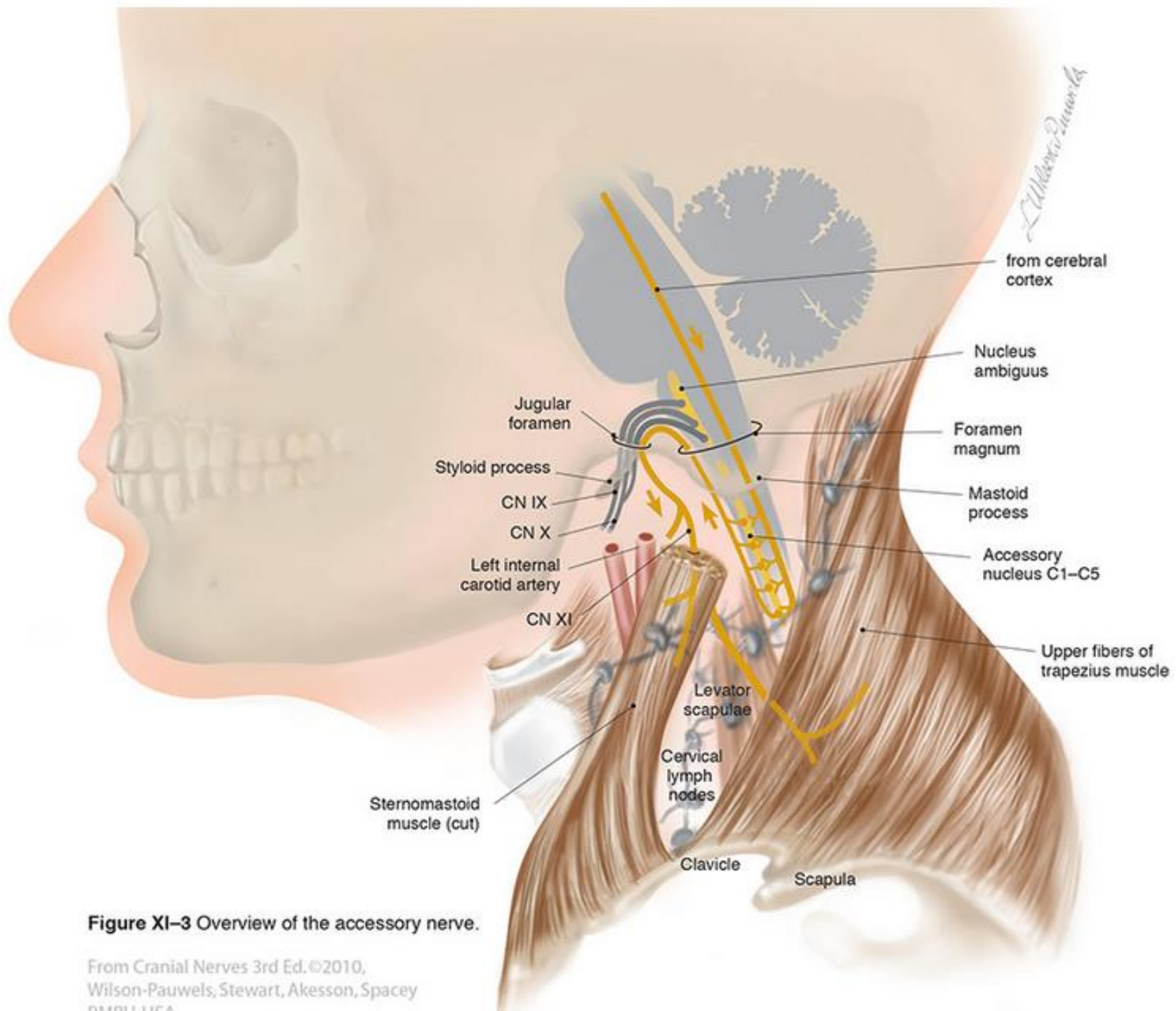
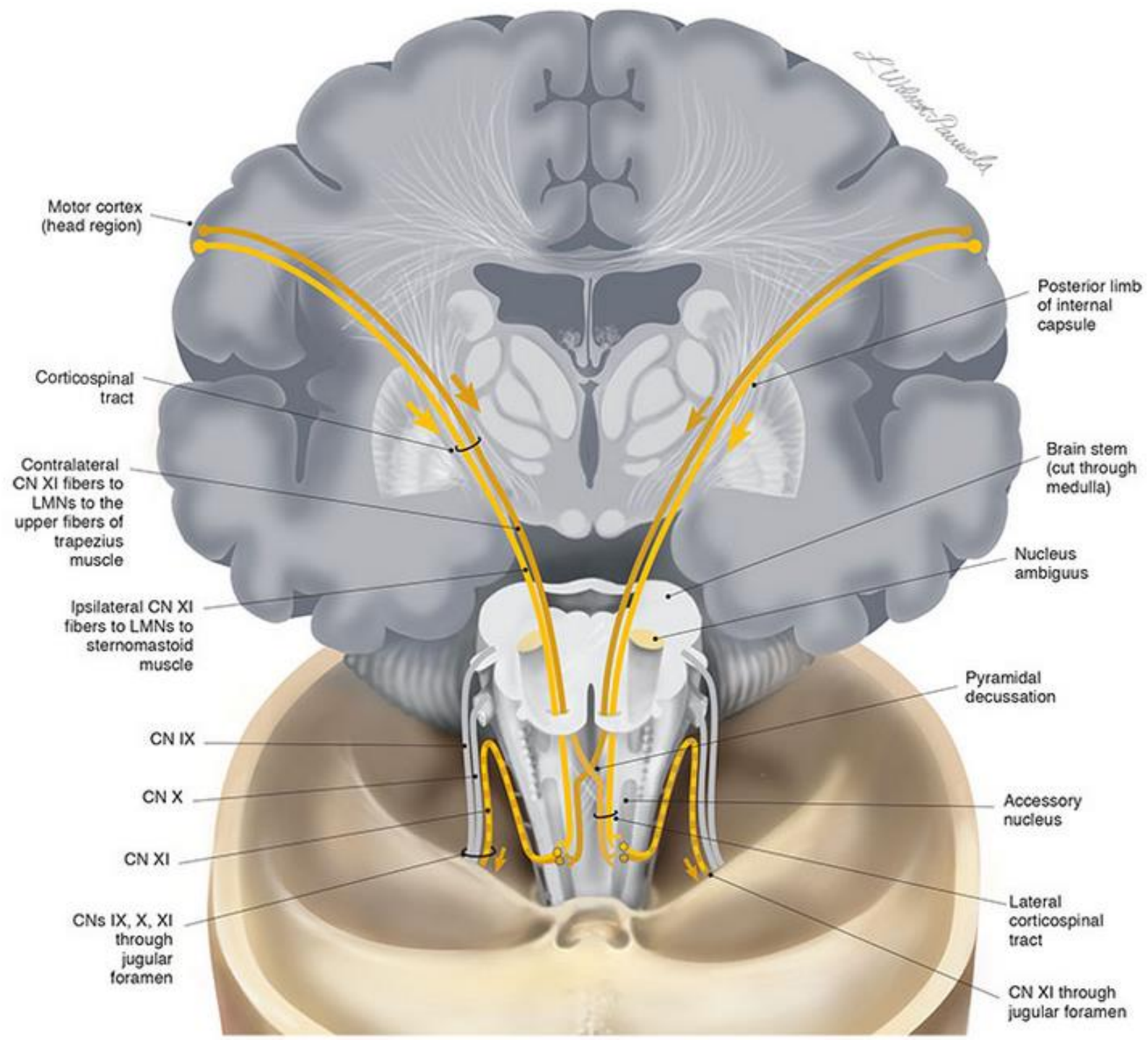
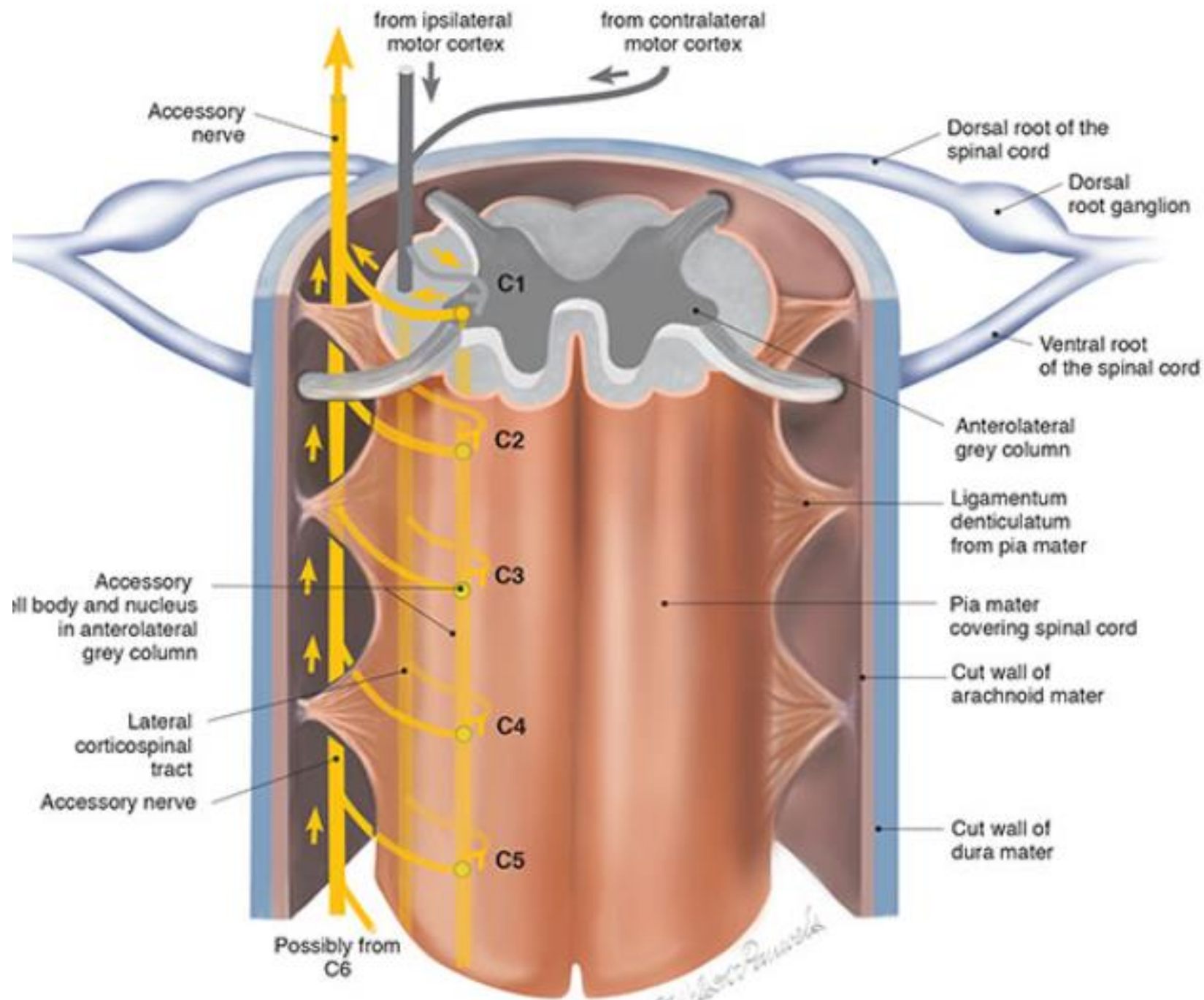
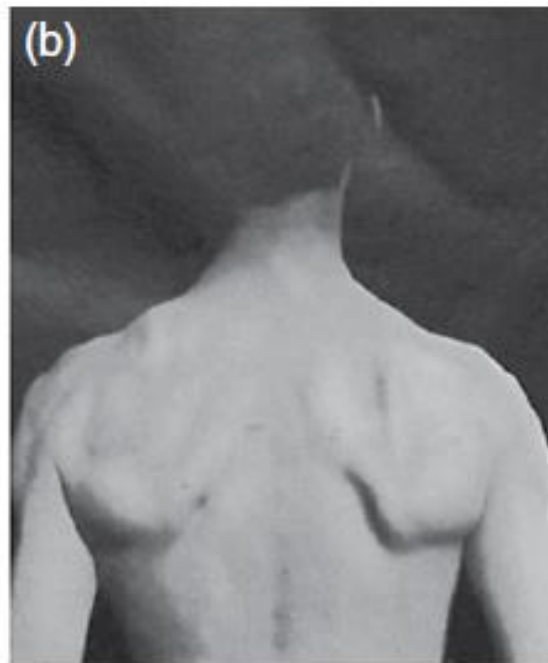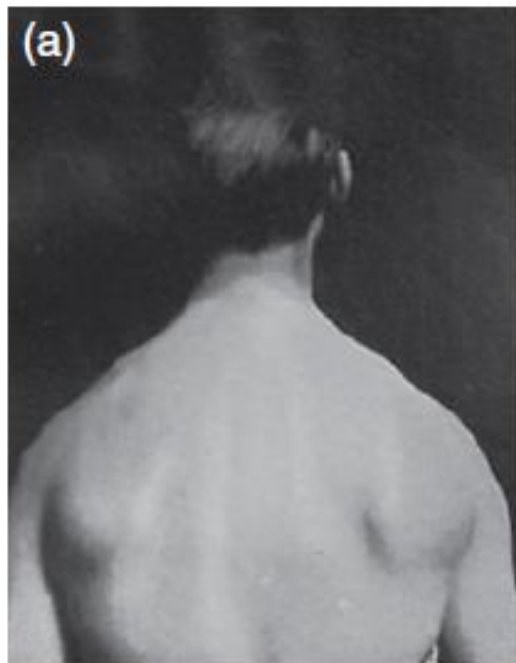


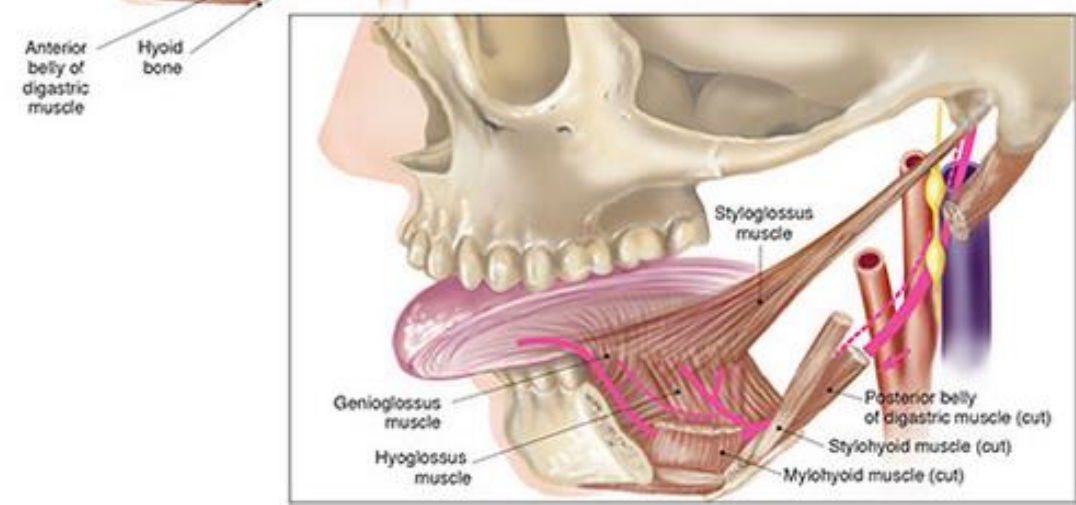
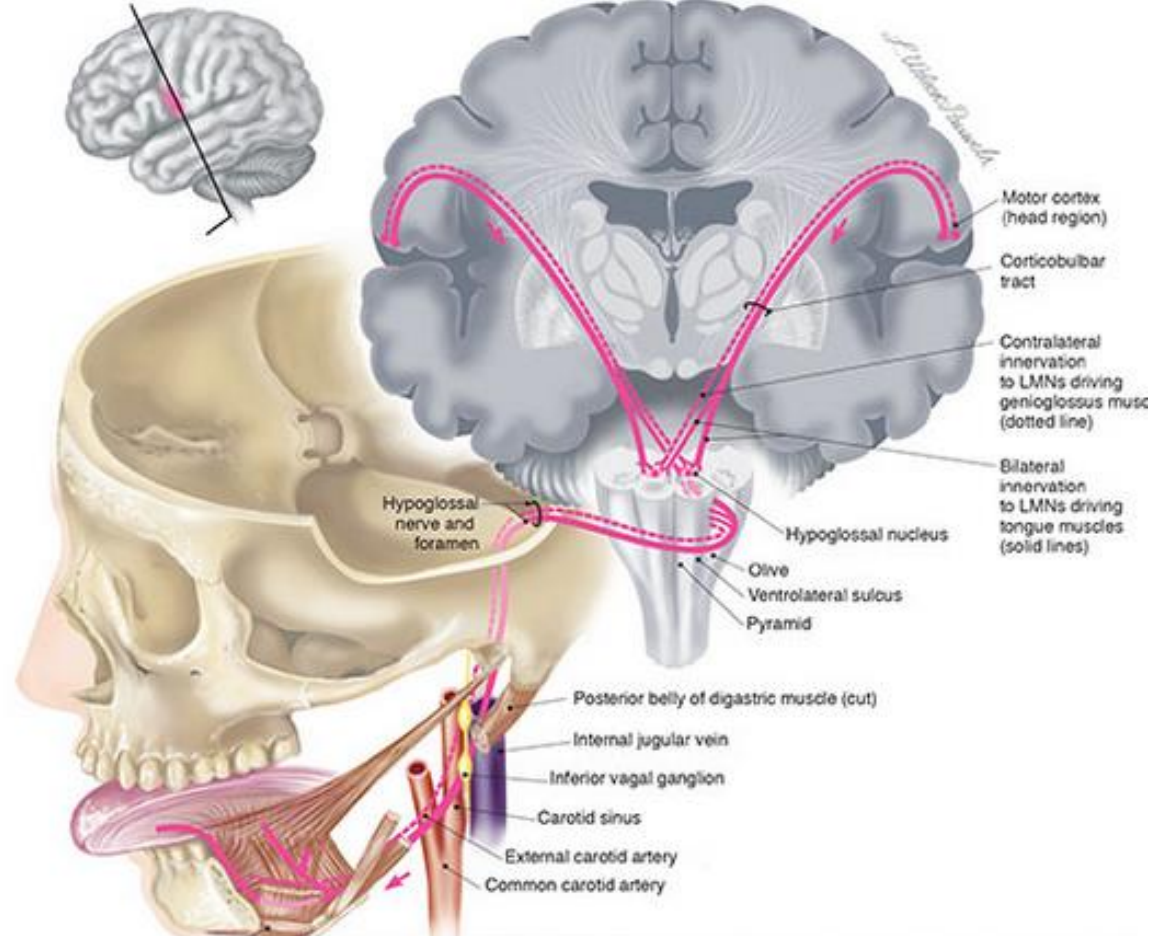
Figure XI-3 Overview of the accessory nerve.

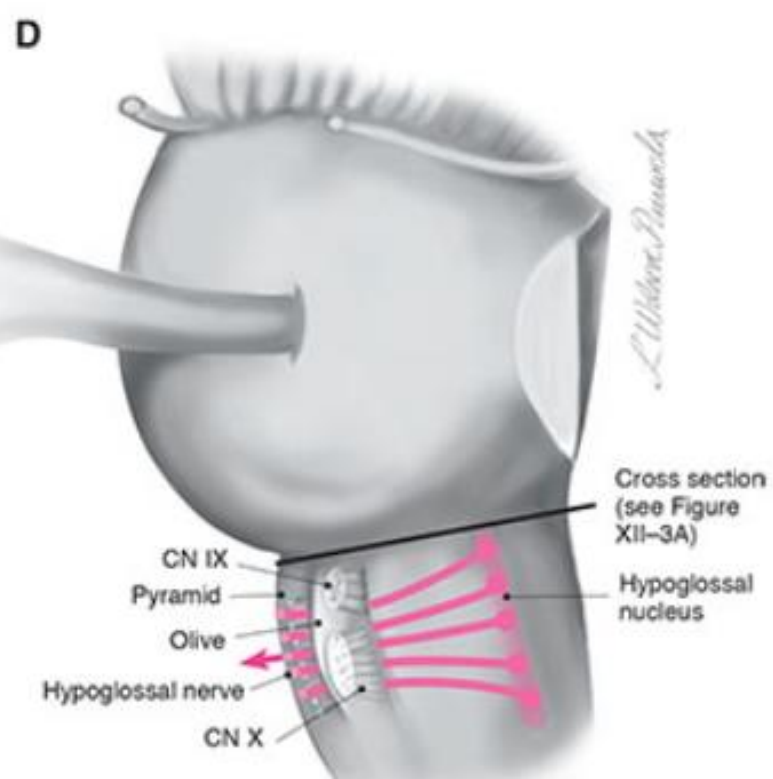
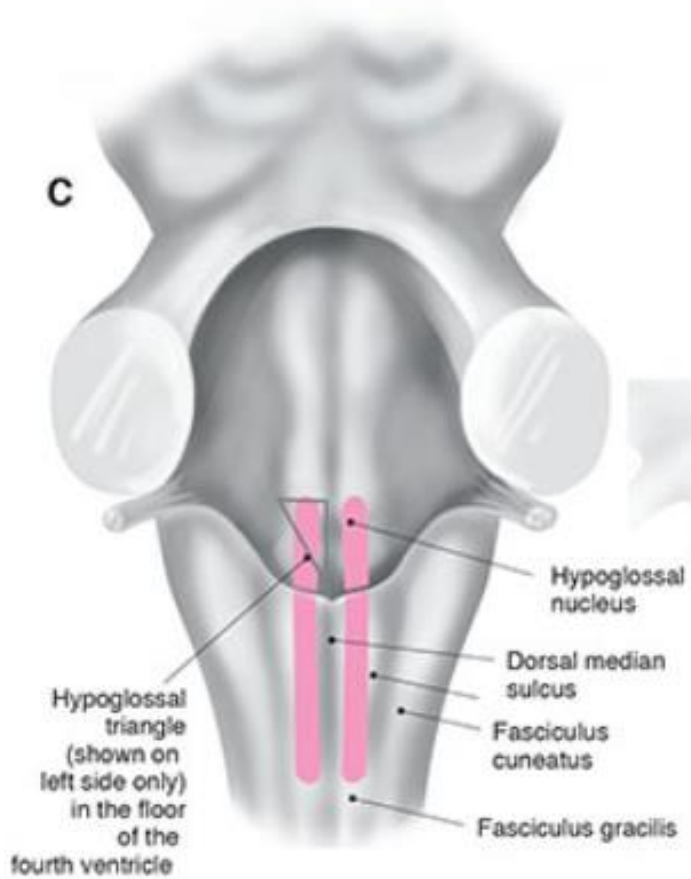
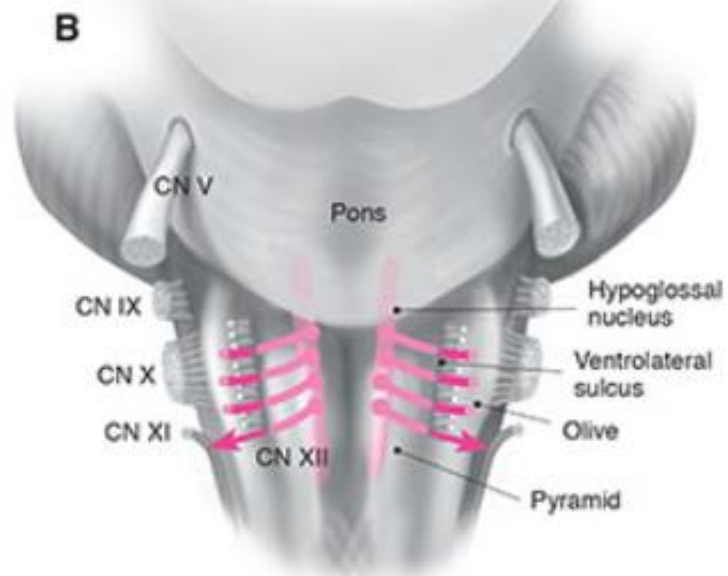
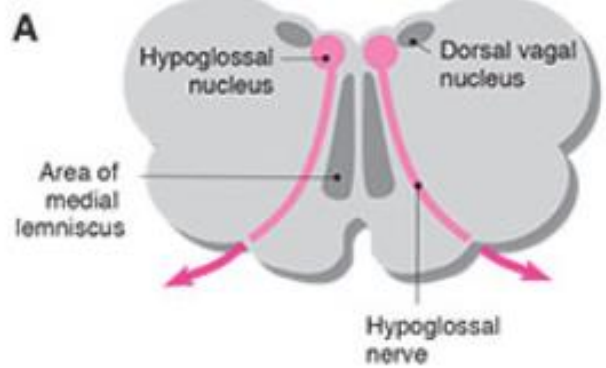
From *Cranial Nerves* 3rd Ed. ©2010,
 Wilson-Pauwels, Stewart, Akesson, Spacey
 DMD, LLC

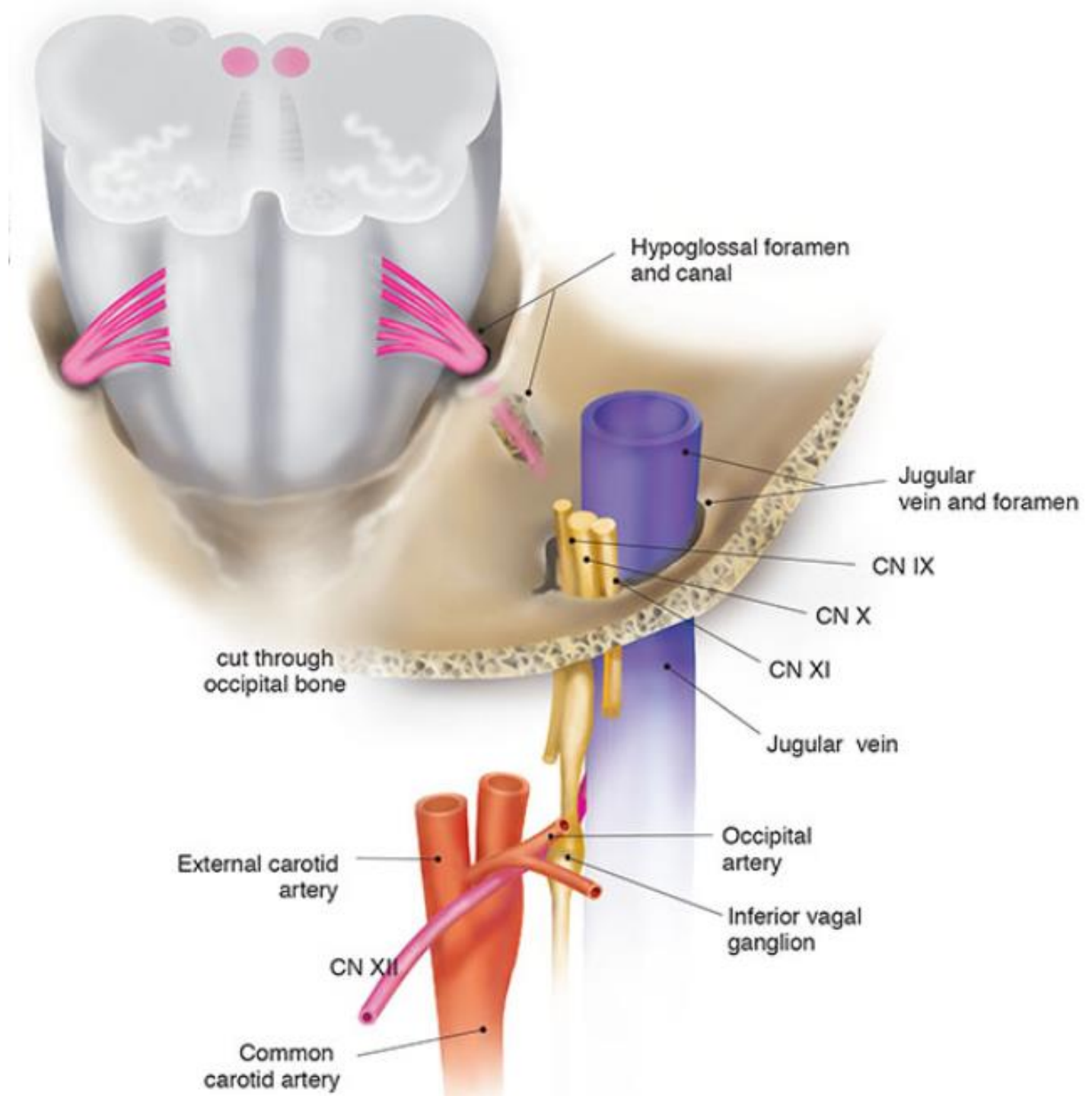


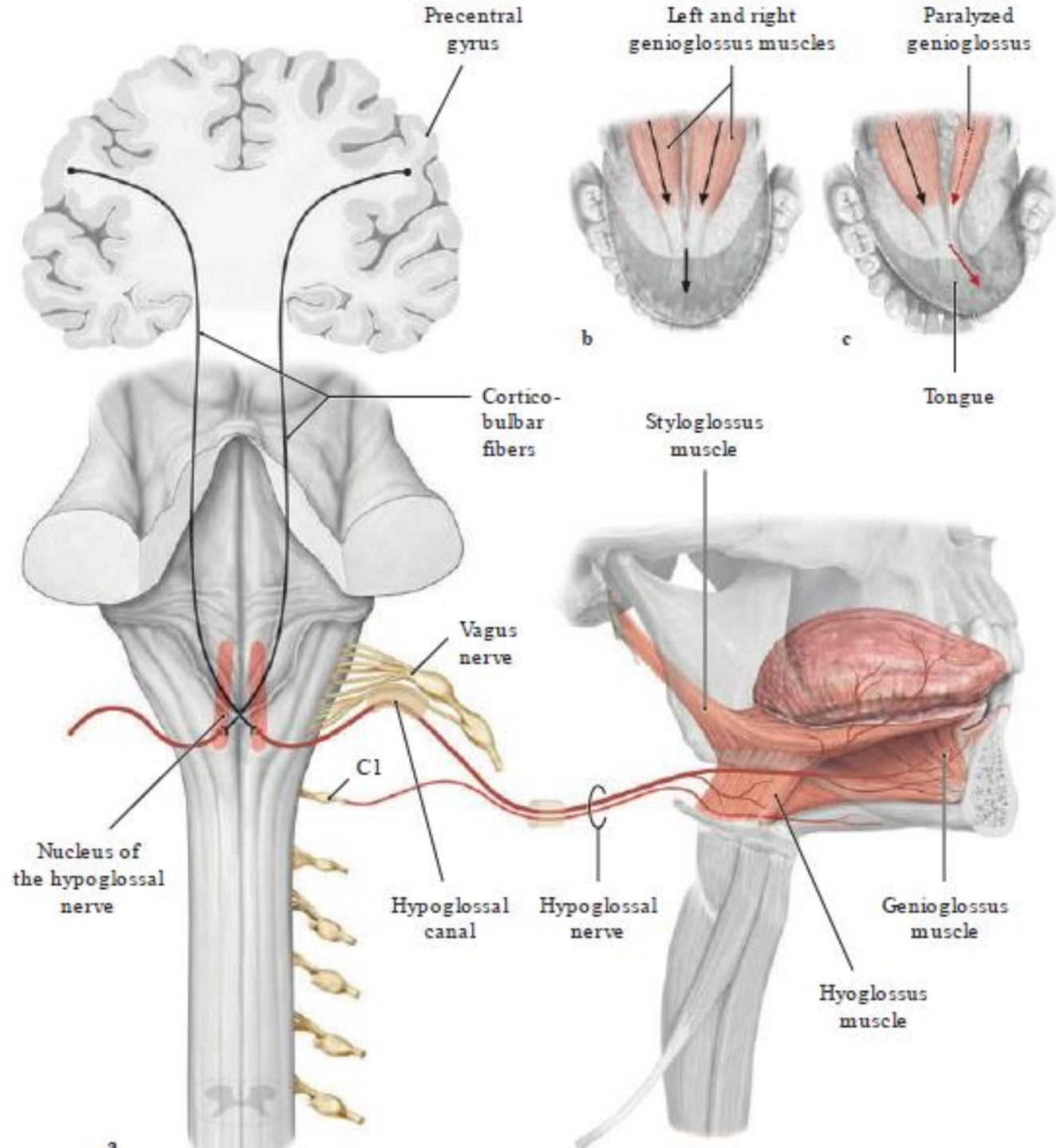


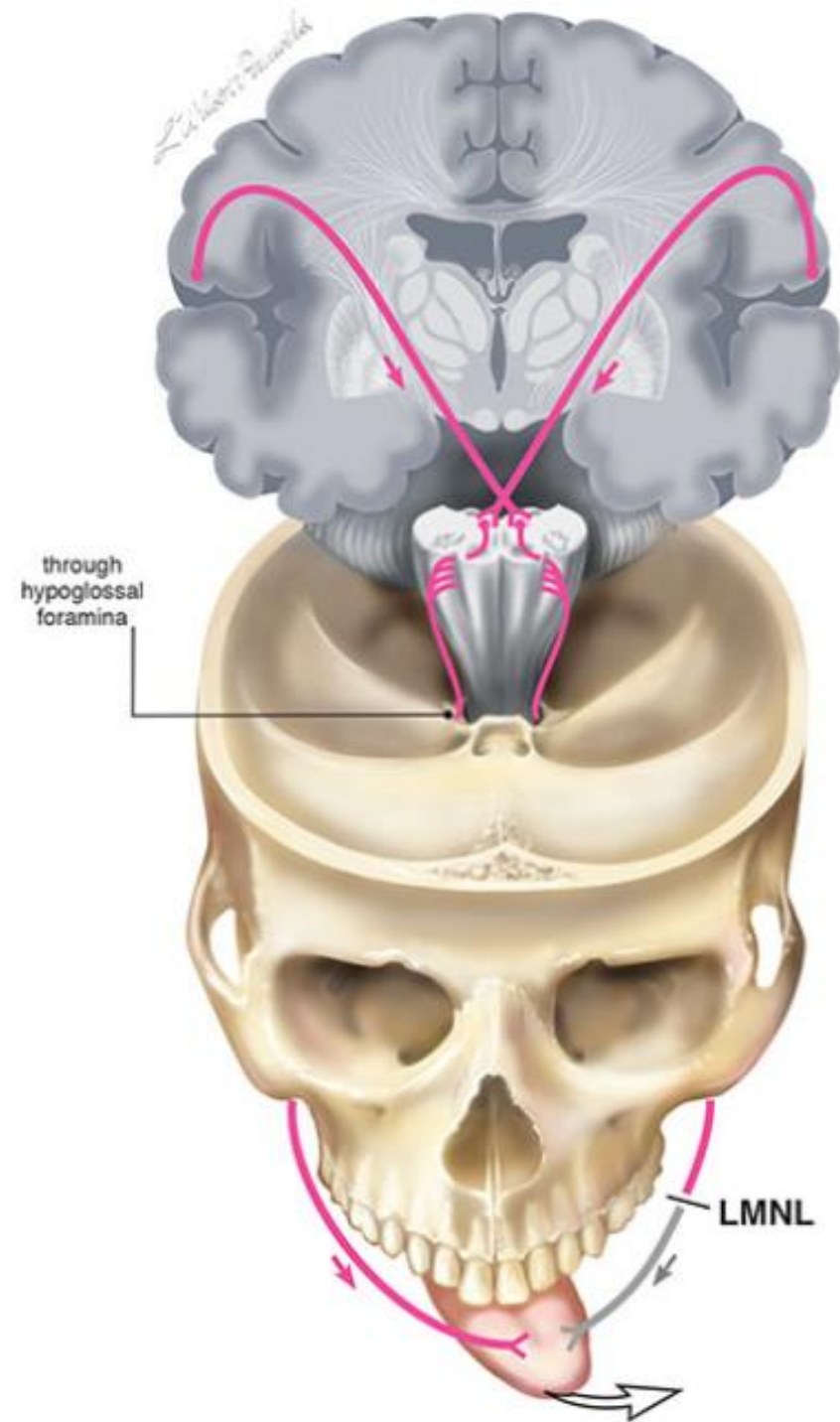
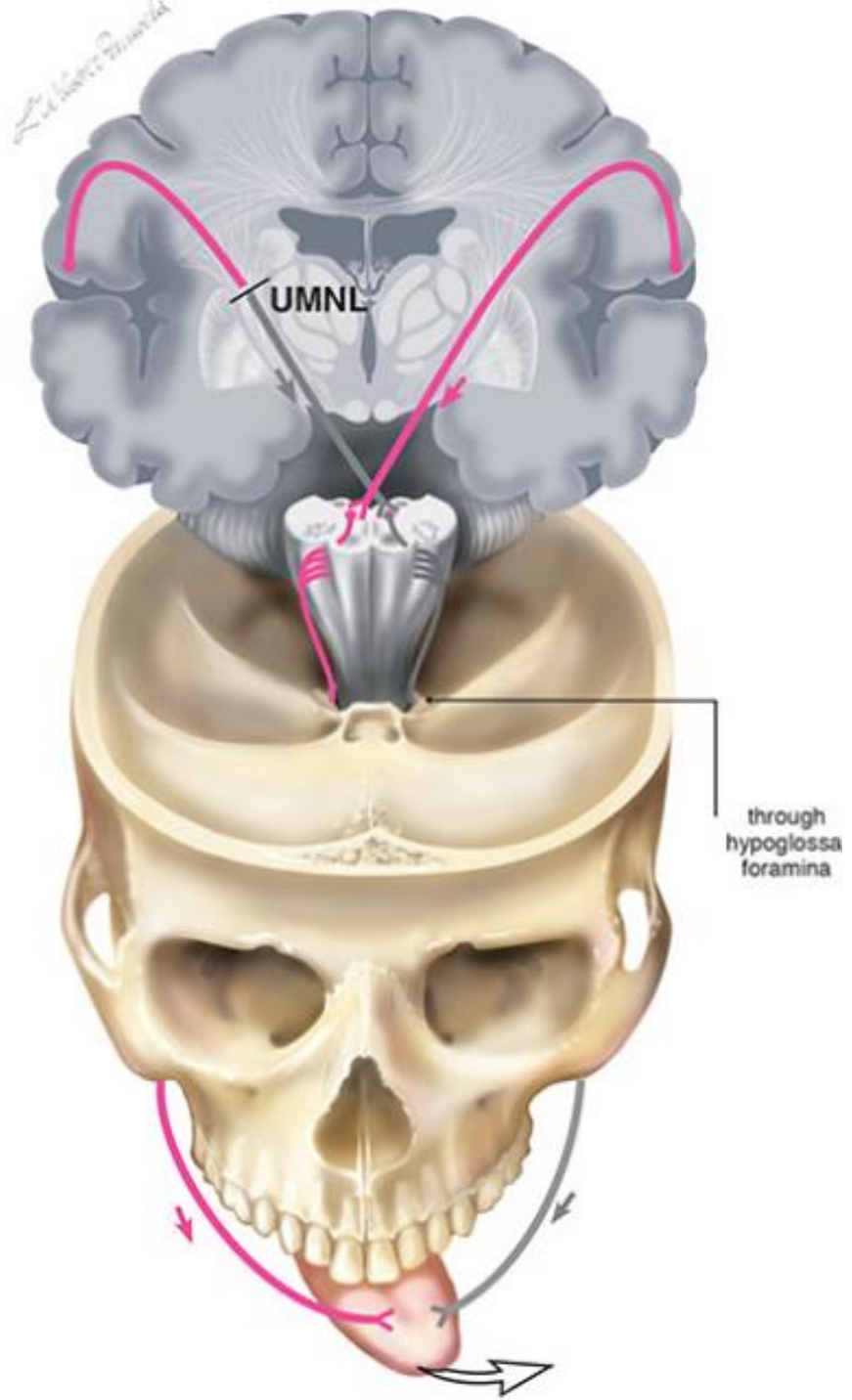


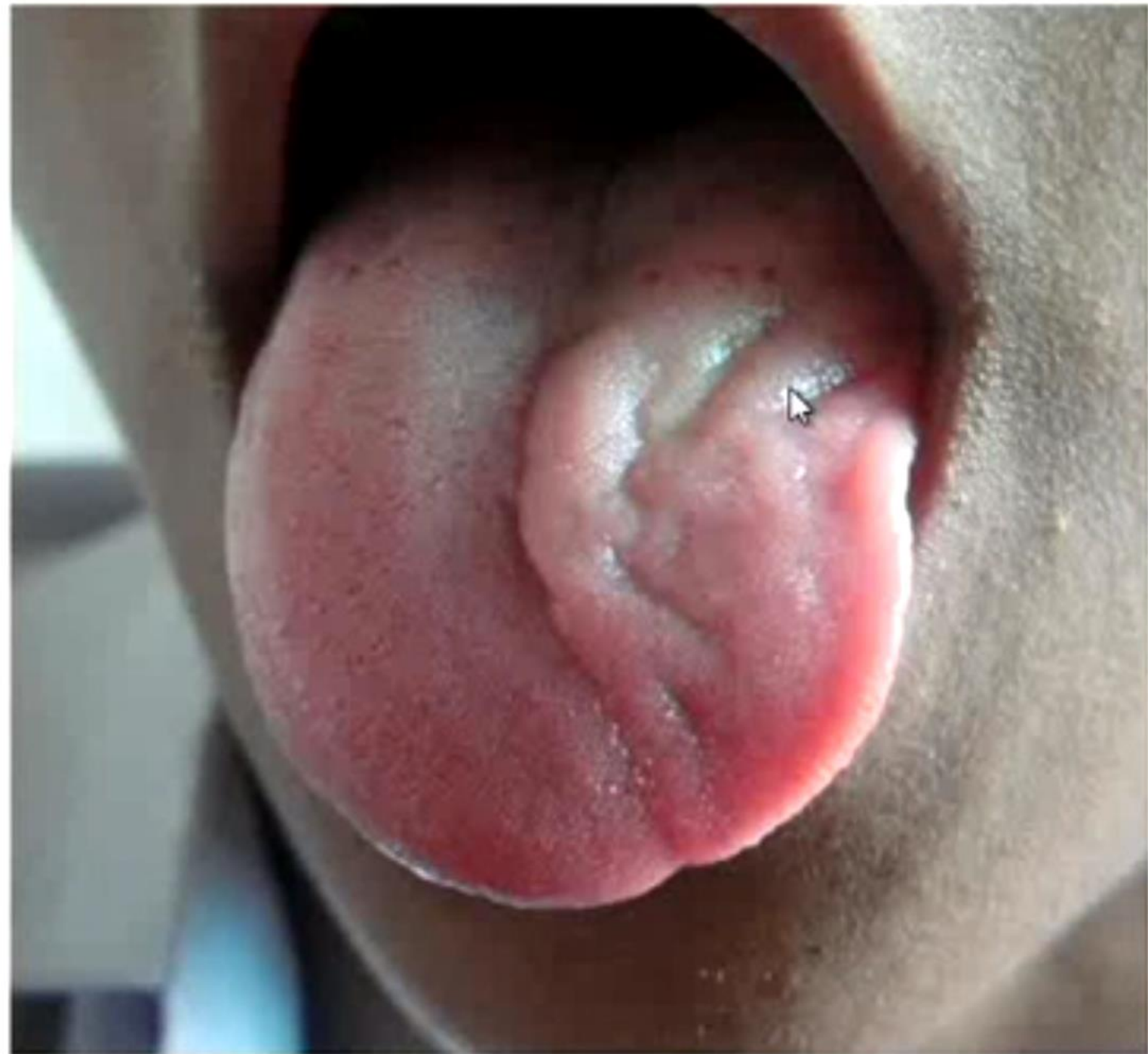

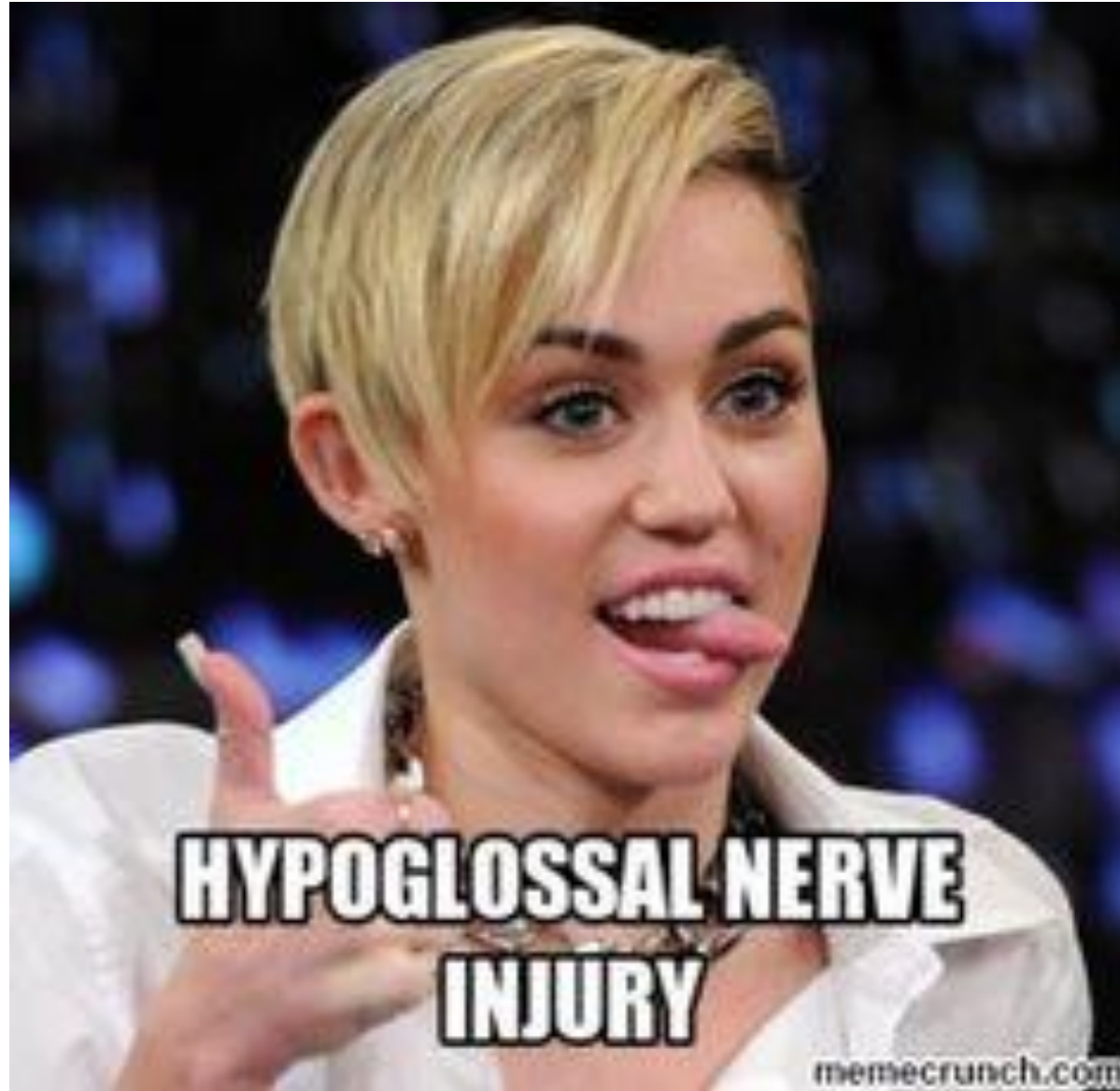












**HYPOGLOSSAL NERVE
INJURY**

memecrunch.com